

Assessment of Dermatological Disorders with Chronic Hepatitis C Virus Infection

Kronik Hepatit C Virüs Enfeksiyonuna Eşlik Eden Dermatolojik Hastalıkların Değerlendirilmesi

Cahit Yavuz¹, Esmâ Eroglu²

Öz

Amaç: Hepatit C virüsü (HCV) esas olarak hepatopatik olmasına rağmen HCV enfeksiyonuna bağlı gelişebilen çok sayıda ekstrahepatik belirti vardır. Bunlar arasında dermatolojik bulgular ekstrahepatik belirtilerin önemli bir bölümünü oluşturmaktadır. Bu çalışmada, bölgemizde kronik HCV enfeksiyonuna eşlik eden dermatolojik hastalıkları değerlendirmeyi amaçladık.

Hastalar ve Yöntem: Çalışmaya, 2008-2020 tarihleri arasında 12 yıllık süreçte Enfeksiyon Hastalıkları ve Klinik Mikrobiyoloji Kliniğinde takip edilen Kronik HCV enfeksiyonu tanısı alan 2050 hastanın ek olarak dermatolojik hastalığı tesbit edilen 394'ü dahil edildi.

Bulgular: Dermatolojik hastalık tanısı alan 394 hastanın yaş ortalaması 56 ±17 yıl idi. Bunların 218'i (%58,6) kadın, 176'sı (41,4%) erkek idi. Dermatoloji polikliniğine başvuran kronik HCV enfeksiyonu hastalarında en sık pruritus (18,5%) ve kontakt dermatit (%17,5) saptandığı görüldü. Pruritus ve kontakt dermatitin; ileri yaşta ve kadın cinsiyette daha sık görülmesi istatistiksel olarak anlamlı bulunmuştur (sırasıyla p: 0,013, p: 0,038).

Sonuç: Çalışmamızda HCV enfeksiyonu olan hastaların dermatoloji polikliniğine en sık başvuru sebebi pruritus ve kontakt dermatit olarak saptandı. Hepatit C enfeksiyonunun erken teşhisine ve tedavisine yardımcı olabileceğinden, hepatit C ile ilişkili dermatolojik durumları anlamak önemlidir. Kronik Hepatit C (KHC) hastalarının dermatoloji poliklinik başvuruları sonrası aldıkları tanılarının görülme sıklığı ve çeşitliliği bu alanda yapılacak olan çalışmaların daha standardize edilmiş hasta grupları ve standart laboratuvar teknikleri kullanılarak yapılması gerekliliğini düşündürmüştür.

Anahtar Kelimeler: Hepatit C virüs, ekstrahepatik bulgular, dermatolojik bulgular, pruritus

Abstract

Aim: Although hepatitis C virus (HCV) is essentially hepatopathic, there are many extra-hepatic symptoms that may develop with associated HCV infection. Of these, dermatological findings constitute a significant proportion of extra-hepatic symptoms. The aim of this study was to evaluate dermatological diseases accompanying to chronic HCV infection in our region.

Patients and Methods: From a total of 2050 patients diagnosed and followed up for chronic HCV infection in the Infectious Diseases and Clinical Microbiology Clinics in a 12-years period between 2008 and 2020, 394 determined with concurrent dermatological disease were included in the study.

Results: Chronic HCV patients diagnosed with dermatological disease comprised 218 (%58.6) females and 176 (%41.4) males with a mean age of 56±17 years. In the patients with chronic HCV infection presenting at the dermatology outpatient clinic, pruritus was determined most (%18.5) and followed by contact dermatitis (%17.5). At univariate analyses female gender (p:0,005, OR:3,329, CI 95% [1,439-7,701]) and advanced age (p:0,013, OR:1,029, CI 95% [1,006-1,052]) were detected as significant variables of frequent dermatological diseases. The female gender (p: 0,038, OR:2,682, CI 95% [1,054-6,826]) was detected as the predictor of most frequent dermatological diagnoses in chronic HCV infection at multivariate logistic regression analysis.

Conclusion: The most common reasons for presentation of patients with HCV infection at the dermatology outpatient clinic were determined to be pruritus and contact dermatitis. The frequency and variability of the diagnoses seen in chronic hepatitis C patients after presentation at the dermatology outpatient clinic suggest the need for further studies in this area with more standardised patient groups using standard laboratory techniques.

Key words: Hepatitis C virus, extra-hepatic manifestations, dermatological manifestations, pruritus

¹Konya City Hospital, Department of Dermatology, Konya, Turkey

²Konya Meram Hospital, Department of Infectious Diseases and Clinical Microbiology, Konya, Turkey

Address correspondence to: Cahit Yavuz, Konya City Hospital, Department of Dermatology, Konya, Turkey
e-mail: yavuzcahit@yahoo.com

Geliş Tarihi/Received: 15 July 2021

Kabul Tarihi/Accepted: 1 September 2021

Cite this article as: Yavuz C, Eroglu E. Assessment of Dermatological Disorders with Chronic Hepatitis C Virus Infection. Selcuk Med J 2021;37(3): 238-244

Disclosure: None of the authors has a financial interest in any of the products, devices, or drugs mentioned in this article. The research was not sponsored by an outside organization. All authors have agreed to allow full access to the primary data and to allow the journal to review the data if requested.



"This article is licensed under a [Creative Commons Attribution-NonCommercial 4.0 International License](https://creativecommons.org/licenses/by-nc/4.0/) (CC BY-NC 4.0)"

INTRODUCTION

It is estimated that 71 million people worldwide are infected with hepatitis C virus (HCV). Throughout the world, HCV is the leading cause of chronic liver disease, including cirrhosis and hepatocellular carcinoma (1). Although HCV is essentially hepatopathic, there are many extra-hepatic symptoms and it is predicted that approximately 74% of patients with chronic HCV infection will manifest at least one extra-hepatic symptom during their lifetime (2).

Increased mortality rates, which have been reported in patients with chronic HCV infection, are thought to be associated to a great extent with extra-hepatic symptoms of chronic infection (3, 4). Autoimmune mechanisms are thought to be responsible for the development of extra-hepatic symptoms associated with HCV. This theory is supported by the emergence of autoimmune characteristics such as immune complex deposition diseases which cause lymphoproliferative disorders (eg, lymphoma) and local and/or systemic complications (2, 5). Dermatological findings constitute a significant part of extra-hepatic symptoms and significantly affect the morbidity of the disease (6-8).

There is an extremely wide range of cutaneous symptoms of chronic HCV infection. There are extensive studies in literature showing an epidemiologically proven relationship between chronic HCV and cutaneous diseases. Approximately 17% of chronic HCV patients have directly or indirectly at least one skin symptom (9). The most frequently seen dermatological findings of HCV infection are mixed cryoglobulinemia, porphyria cutanea tarda, lichen planus, urticaria, pruritus, thrombocytopenic purpura, and psoriasis. Also there may be an association with autoimmune skin diseases such as vitiligo. However, the prevalence of skin findings shows geographical variability (10-12). The aim of this study was to determine the dermatological diseases accompanying to chronic HCV infection in our region.

PATIENTS AND METHODS

Local ethical committee approval was granted from Ethical Committee of Selcuk University School of Medicine with approval number 2021/139. From a total of 2050 patients diagnosed and followed up for chronic HCV infection in the Infectious Diseases and Clinical Microbiology Clinics of our hospital in 12-year period between July 2008 and July 2020 were assessed with Hospital Information Management System and 394 patients with dermatological problems were included

in the study. A retrospective review was made of the results of the examinations of all the patients performed by an infectious diseases specialist and a dermatologist. Written informed consent could not be obtained from patients for retrospective hospital file analysis.

A record was made for each patient of demographic data, genotype analyses, HCV-RNA levels, liver histopathology results and dermatological disease diagnoses. The patients included in the study were aged >18 years, anti-HCV positive, had received treatment and subsequently developed recurrence, were unresponsive to treatment or had naive chronic HCV infection. Patients were excluded from the study if they were anti-HCV positive but HCV-RNA negative and under 18 years of age. The anti-HCV tests were performed in laboratory with an Advia Centaur autoanalyser (Siemens) using the chemiluminescence immunoassay technique.

In each anti-HCV positive status, reverse-transcription polymerase chain reaction (RT-PCR) HCV-RNA measurement was performed. The liver fibrosis grade and histological activity index with the modified Ishak scoring were applied to the chronic HCV patients (13). The liver fibrosis grade of the patients ranged from grade I to grade V. The normal range of the modified Ishak Histological Activity Index is 0-18 (13). The patients included in the study were separated into 3 groups for evaluation according to the histological activity index scores as 0-5, 6-10 and >11.

Statistical Analysis

Data obtained in the study were analyzed statistically using SPSS version 15.0 software (SPSS Inc., Chicago, IL, USA). Conformity of the variables to normal distribution was evaluated using visual (histograms, probability curves) and analytical methods (Kolmogorov-Smirnov test). Numerical variables showing normal distribution were stated as mean \pm standard deviation values and those not showing normal distribution as median (interquartile range) values. Categorical variables were stated as number (n) and percentage (%). Statistical analysis of independent groups of numerical variables was performed with the Student's t-test or the Mann Whitney U-test, and in the analysis of categorical variables, the Chi-square test or Fisher's Exact test was applied. A combined endpoint was created as frequently detected dermatological diagnoses with chronic HCV infection (pruritus and contact dermatitis). The univariate and multivariate logistic

regression analyses were used to determine the predictors of combined endpoint. A value of $p < 0.05$ was considered statistically significant.

RESULTS

394 of 2050 chronic HCV patients with dermatological disease were included to study. These 394 patients comprised 218 (%58.6) females and 176 (%41.4) males with a mean age of 56 ± 17 years (Table-1). In the patients with chronic HCV infection presenting at the dermatology outpatient clinic, pruritus was determined most (%18.5) and followed by contact dermatitis (%17.5). The frequency of dermatological diagnoses of the chronic HCV patients are summarized in Figure-1. At univariate analyses female gender ($p:0,005$, OR:3,329, CI 95% [1,439-7,701]) and advanced age ($p:0,013$, OR:1,029, CI 95% [1,006-1,052]) were detected as significant variables of frequent dermatological diseases (Table-2). Afterward, female gender ($p:0,038$, OR:2,682, CI 95% [1,054-6,826]) was detected as the predictor of most frequent dermatological diagnoses in chronic HCV infection at multivariate logistic regression analysis.

The treatment records were available for 97 of the patients with chronic HCV infection (Table 3). Most used treatment was interferon+ribavirin therapy for patients (%44.3). No statistically significant relationship was determined between therapy and the frequency of dermatological disease ($p > 0.05$). The HCV-RNA results were available for 97 of the

Table 1. Baseline characteristics of patients

Demographic characteristics	n (%)
HCV patients, total	2050
HCV patients with dermatological disorder	394, (100)
Male	176, (41,4)
Female	218, (58,6)
Age in years (mean SD)	56 \pm 17

patients with chronic HCV infection. The median HCV-RNA value was determined to be 664.000 IU/ml (min:190.315 IU/ml, max:2.609.282 IU/ml). No significant relationship was determined between viral load and the frequency of the diagnosis of the two most common dermatological diseases that pruritus and contact dermatitis ($p > 0.05$).

When the records of the chronic HCV patients were examined, it was seen that genotyping had been performed in 101 patients. The most common genotype was determined to be 1b (n:74/101, %73.1). No significant relationship was determined between genotype and dermatological disease ($p > 0.05$). In the retrospective examination of the records of the 394 chronic HCV patients, pathology results were available for 30 patients. Liver fibrosis grade of the patients was evaluated according to the modified Ishak grading system. The liver fibrosis grade of the patients ranged from grade I to grade V. No significant

Table 2. Univariate analyses for presence of pruritus and contact dermatitis with chronic HCV disease

	Beta	p	OR	CI 95%
Female	1,203	0,005	3,329	1,439-7,701
Age	0,028	0,013	1,029	1,006-1,052
Treatment	-,064	0,685	0,938	0,689-1,277
Genotype	-,034	0,312	0,967	0,906-1,032
HCV-RNA	0,00	0,982	1	1-1
Grade	-,242	0,346	0,785	0,475-1,298

OR: Odds ratio, CI:Confidence interval

Table 3. Treatments were given for chronic HCV patients

Treatments	n (%)
Interferon+Ribavirin	43, (44,3)
Glecaprevir / Pibrentasvir	20, (20,6)
Paritaprevir / Ritonavir / Ombitasvir / Dasabuvir	22, (22,7)
Sofosbuvir / Ribavirin	2, (2,1)
Sofosbuvir / Ledipasvir	6, (6,2)
Sofosbuvir / Ledipasvir / Ribavirin	4, (4,2)
Total	97, (100)

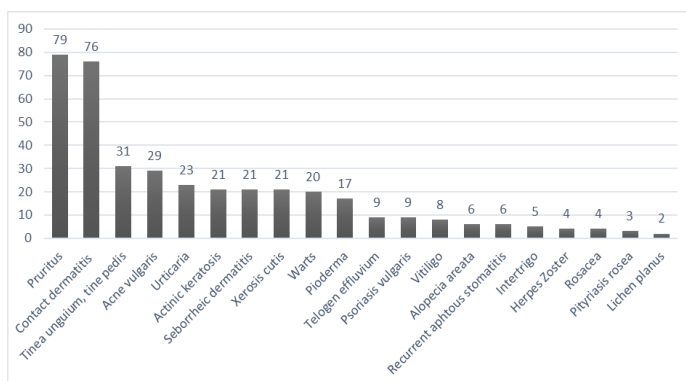
Table 4. Genotype analysis, Grading and Histological Activity Index of chronic HCV patients

Genotype	n, (%)	Grade	n, (%)	Histological Activity Index	n, (%)
1a	1 (1)	I	11 (36,6)	1-5	6 (20)
1b	74 (73,1)	II	8 (26,6)	6-10	14 (46,6)
2	5 (4,9)	III	6 (20)	>11	10 (33,3)
3	19 (18,8)	IV	2 (6,6)	Total	30 (100)
4	1 (1)	V	3 (10)		
5	1 (1)	Total	30 (100)		
Total	101 (100)				

relationship was determined between fibrosis grade and dermatological disease ($p>0.05$). The normal range of the modified Ishak Histological Activity Index is 0-18. The patients included in the study were separated into 3 groups for evaluation according to the histological activity index scores as 0-5, 6-10 and >11 . No significant relationship was determined between the histological activity index scores and dermatological disease ($p>0.05$) (Table-4).

DISCUSSION

It was a single center, retrospective study. We try to evaluate dermatological diseases accompanying to chronic HCV infection in our region. 394 of 2050 chronic HCV patients was determined with dermatological disease. In comparison to other dermatological diagnoses, pruritus and contact dermatitis were found to be most common diseases in HCV patients. In some patients, dermatological findings may be clinical signs of early stage liver disease. It has been reported that approximately %17 of chronic HCV infection patients directly or indirectly develop at least one skin symptom (9). Of the patients with chronic

**Figure 1.** The frequency of dermatological diagnoses in chronic HCV patients

HCV infection in this study, dermatological disease was determined in %19.2 (n:394/2050). Although the mechanisms that play a role in the development of extra-hepatic symptoms have not been clarified, autoimmune mechanisms are thought to be basically responsible (14).

In a study by Amin et al. (15) the most common cutaneous findings of HCV infection were determined to be pruritus, lichen planus (LP), hyperpigmentation and urticaria. In patients group with LP, pruritus, urticaria and porphyria cutanea tarda (PCT), HCV infection was seen more often than in the normal healthy population. Schwartz et al. (16) reported that the most frequently seen skin diseases associated with HCV infection were cryoglobulinemia and the others are PCT, LP, urticaria, pruritus and thrombocytopenic purpura. The various dermatological findings observed and frequencies are shown in Figure-1. The most common reason for presentation at the dermatology outpatient clinic of the chronic HCV patients in this study was determined to be pruritus (%20), followed by contact dermatitis (%19), tinea unguium/pedis (%7.8), acne vulgaris (%7.3), urticaria (%5.8), seborrheic dermatitis (%5.3) and xerosis cutis (%5.3). Pruritus was the most commonly seen skin disease in the current study, at the rate of %20. In a previous study in Turkey by Dervis and Serez, pruritus was reported at the rate of %18.57 in chronic HCV patients (17). Another study in Egypt reported pruritus at %21.3 (18). The exact mechanism of itching in liver diseases remains uncertain, but it has been suggested that the presence of bile salts and liver metabolites responsible for pruritus (19).

Urticaria is a widespread disease that may be seen at least once in the lifetime of %20 of the general population. It is known that urticaria originates from drugs, foodstuffs, connective tissue diseases and infections (20). However, whether or not urticaria is caused by hepatitis C infection and the related etiopathogenic process have not yet been clarified,

but it is thought to be related to the presence of immune complexes in chronic HCV patients (21). Various studies have recommended the examination of anti-HCV in patients with urticaria in regions where the prevalence of HCV is high (20, 22). Dega et al. (23) reported that anti-HCV positivity was determined in %18 of patients with urticaria. Azfar et al. (24) determined this rate to be 2.4. In another study in Turkey by Soylyu et al. (25) urticaria was determined in %4 of 50 anti-HCV positive patients. The regional data of the current study with urticaria determined at %5.8, were consistent with the findings of Soylyu et al. (25).

There is known to be increased HCV frequency in LP patients. Previous studies have recommended regular examining for anti-HCV in patients diagnosed with LP (26, 27). In the current study, this rate was determined to be extremely low at %0.5. Similarly, two other studies in Turkey determined no relationship between LP and chronic HCV infection (28, 29). This could be explained by variations in HCV genotypes according to geographical region and some genetic conditions which increase disease sensitivity (30). Some epidemiological data have shown a relationship between HCV infection and PCT. In a study that evaluated 2167 PCT patients, the mean prevalence of chronic HCV infection was calculated to be %47 (31). However, in a previous study from Turkey, there were no PCT cases (17). Likewise in the current study, there were no PCT cases. Although this could be due to different genetic and environmental factors or possibly different laboratory techniques, it was also thought that it could be related to the consideration of PCT in the diagnosis. Several studies have reported the co-existence of hepatitis C and psoriasis vulgaris disease, and some authors have suggested that hepatitis C could be one of the triggering factors of psoriasis vulgaris (32, 33). In the current study, this rate was determined to be %2.2. It is clear that HCV infection can not trigger the disease alone without a genetic basis for psoriasis vulgaris.

The other dermatological diseases seen in the patients with chronic HCV infection in the current study are shown in Figure-1. In literature, there are very few studies or case reports about the relationship between HCV infection or the treatments given for HCV and recurrent findings such as oral sores, telogen effluvium, pyoderma, acne vulgaris, actinic keratosis, seborrheic dermatitis, xerosis cutis, alopecia areata, vitiligo and intertrigo (12, 24, 34). It is thought that the majority of diseases such as pityriasis

rosea, acne rosacea, zona zoster, viral warts, and tinea unguium/tinea pedis are determined incidentally. To the best of our knowledge, there is no study in literature that has revealed a relationship between these diseases and HCV infection. To evaluate a possible relationship, there is a need for further studies of more extensive patient series. There are some studies about extrahepatic manifestations of HCV infection and treatment relation. Kassas et al. (35) reported that extrahepatic manifestations of HCV improved with direct antiviral agents. They reported 30 of 1039 patients with extrahepatic manifestations, 16 patients with pruritus, 8 patients with psoriasis vulgaris and 6 patients with lichen planus. All patients with pruritus and psoriasis and 4 of 6 patients with lichen planus showed significant improvement with antiviral treatment (35). As similar Tawfik et al. (36) also reported significant improvement of extrahepatic manifestations of HCV patients with treatment. They noticed that vitiligo patients did not show any change in their disease activity with treatment. Wiznia et al. (37) reported an interesting metaanalysis about percentage of cutaneous manifestations in HCV patients and possibility of accompanying HCV in cutaneous disorders. They reported that, mixed cryoglobulinemia is seen about %5-30 in HCV patients and mixed cryoglobulinemia patients have HCV positivity nearly %80-90. Lichen planus is more common about 5 fold in HCV patients and lichen planus patients have HCV positivity is more common about 5 fold compared with normal population. Necrolytic acral erythema is more common about %1 in HCV patients and necrolytic acral erythema patients nearly %100 have HCV positivity. Necrolytic acral erythema was initially considered pathognomonic for HCV (37). Necrolytic acral erythema is characterized with painful erythematous skin lesions on acral skin surfaces and this involvement is pathognomonic for HCV (38).

In Turkey, genotype 1 is the most common genotype at over %80, and is weighted towards genotype 1b. Other genotypes are seen at lower rates. This creates a difference in treatment approach (39). It has been reported that there are dermatological symptoms that develop secondary to the drugs used in the treatment of chronic hepatitis C (40-41). However, in the current study, no statistically significant relationship was determined between the drugs used and the frequency of dermatological diseases. Although there are studies suggested that there is a relationship between different genotypes and the frequency of some dermatological diseases (42), there are no

studies that have shown a relationship between genotype and skin findings (39, 43). The genotype of HCV determines the range of treatment options, and therefore it is difficult to decide whether dermatological diseases seen from HCV infection or secondary to the drugs. In the current study, no relationship was determined between genotypes, HCV-RNA levels and the frequency of dermatological diseases.

There were some limitations to this study. Primarily it was a single-centre study, so this prevents generalisation of the results to the whole population. Secondly as it was a retrospective study, it could not be determined whether or not the treatment of the HCV infection affected the prognosis of the dermatological disease thought to be associated with HCV. Thirdly, there was no control group in our study. There is a need for further, larger scale, multi-centre, prospective studies to be able to better understand the prevalence and outcomes of cutaneous symptoms in hepatitis C patients.

CONCLUSION

The results of this study demonstrated that the most common reasons for presentation with chronic HCV infection were pruritus and contact dermatitis. In particular female gender and advanced age in patient with pruritus and contact dermatitis should be taken into consideration at chronic HCV infection. It is important to understand the dermatological conditions associated with hepatitis C, as they can be of assistance in the early diagnosis and treatment of HCV infection. Nevertheless, there is a need for further studies of large series with standardised clinical and laboratory methods to determine the dermatological findings and diseases that may be seen and associated with chronic HCV infection.

Conflict of interest: Authors declare that there is no conflict of interest between the authors of the article.

Financial conflict of interest: Authors declare that they did not receive any financial support in this study.

Address correspondence to: Cahit Yavuz, Konya City Hospital, Department of Dermatology, Konya, Turkey
e-mail: yavuzcahit@yahoo.com

REFERENCES

- Naggie S, Wyles DL. Hepatitis C. In: Bennett JE, Dolin R, Blaser MJ (eds). Mandell, Douglas, and Bennett's Principles and Practice of Infectious Diseases. 9th ed. Philadelphia: Elsevier, 2020;154:2040-73.
- Zignego AL, Ferri C, Pileri SA, et al. Italian association of the study of liver commission on Extrahepatic Manifestations of HCV infection. Extrahepatic manifestations of Hepatitis C Virus infection: A general overview and guidelines for a clinical approach. Dig Liver Dis 2007;39:2-17.
- Backus LI, Boothroyd DB, Philips BR, et al. A sustained virologic response reduces risk of all-cause mortality in patients with hepatitis C. Clin Gastroenterol Hepatol 2011;9:509-16.
- Ramos Casals M, Font J. Extrahepatic manifestations in patients with chronic hepatitis C virus infection. Curr Opin Rheumatol 2005;17:447-55.
- Davis GL. Hepatitis C. In: Schiff ER, Sorrell MF, Maddrey WC, editors. Schiff's diseases of the liver. Philadelphia: Lippincott Williams and Wilkins 2003;807-44.
- Sterling RK, Bralow S. Extrahepatic manifestations of hepatitis "C" virus. Curr Gastroenterol Rep 2006;8(1):53-9.
- Younossi ZM, Stepanova M, Mishra A, et al. The impact of chronic hepatitis C on resource utilisation and in-patient mortality for Medicare beneficiaries between 2005 and 2010. Aliment Pharmacol Ther 2013;38:1065-75.
- Jackson JM. Hepatitis C and the skin. Dermatologic Clinics 2002;20(3):449-58.
- Garcovich S, Garcovich M, Capizzi R, et al. Cutaneous manifestations of hepatitis C in the era of new antiviral agents. World J Hepatol 2015;7:2740-8.
- Halawani MR. Dermatological manifestations of hepatitis C virus infection in Saudi Arabia. Saudi Med J 2014;35(6):531-7.
- Bonkovsky HL, Mehta S. Hepatitis C: A review and update. J Am Acad Dermatol 2001;44:159-79.
- Jadali Z, Eslami M, Sanati M, et al. Hepatitis C virus antibodies and vitiligo disease. Iran J Publ Health 2005;34:23-6.
- Knodell RG, Ishak KG, Black WC, et al. Formulation and application of a numerical scoring system for assessing histological activity in asymptomatic chronic active hepatitis. Hepatology 1981;1:431-55.
- Zampino R, Marrone A, Restivo L, et al. Chronic HCV infection and inflammation: Clinical impact on hepatic and extra-hepatic manifestations. World J Hepatol 2013;5:528-40.
- Amin S, Irfanullah Khattak I, Wazir MN. Chronic hepatitis "C" A dermatological outlook. J Liaquat Uni Med Health Sci 2013;12:12-14.
- Schwartz RA, Birnkrant AP, Elmets CA, et al. Cutaneous manifestations of hepatitis C. [Updated: 2013 September 12; Accessed: 2013 October 15]. Available from: <http://emedicine.medscape.com/article/1134161-overview>.
- Dervis E, Serez K. The prevalence of dermatologic manifestations related to chronic hepatitis C virus infection in a study from a single center in Turkey. Acta Dermatovenerol Alp Panonica Adriat 2005;14:93-8.
- Ezzat WM, Abd El Hamid MF, Emam H, et al. Skin manifestations of chronic hepatitis C virus infection in Cairo, Egypt. Raslan East Mediterr Health J 2009;15:692-700.
- Ghent CN. Cholestatic pruritus. In: Bernhard JD, editor. Itch: Mechanisms and Management of Pruritus. New York (NY): McGraw-Hill 1994;229-42.
- Kanazawa K, Yaoita H, Tsuda F, et al. Hepatitis C virus infection in patients with urticaria. J Am Acad Dermatol 1996;35:195-8.
- Cribier B. Urticaria and hepatitis. Clin Rev Allergy Immunol 2006;30:25-9.

22. Siddique N, Pereira BN, Hasan Arshad S. Hepatitis C and urticaria: Cause and effect? *Allergy* 2004;59:668.
23. Dega H, Francès C, Dupin N, et al. [Pruritus and the hepatitis C virus. The MULTIVIRC Unit]. *Ann Dermatol Venereol* 1998;125:9-12.
24. Azfar NA, Zaman T, Rashid T, et al. Cutaneous manifestations in patients of hepatitis C. *J Pakistan Assoc of Dermatol* 2008;18:138-43.
25. Soylu S, Gül Ü, Kılıç A. Cutaneous manifestations in patients positive for anti-hepatitis C virus antibodies. *Acta Derm Venereol* 2007;87:49-53.
26. Nagao Y. Patients with oral lichen planus showed greater likelihood for HCV. *BMC Gastroenterology* 2012;12:31.
27. Mahboobi N, Agha-Hosseini F, Lankarani KB. Hepatitis C virüs and lichen planus: The reassociation. *Hepat Mon* 2010;10:161-4.
28. Kirtak N, İnalöz HS, Özgöztaş O, et al. The prevalence of hepatitis C virüs infection in patients with lichen planus in Gaziantep region of Turkey. *Eur J Epidemiol* 2000;16:1159-61.
29. Kadiroğlu AK, Göral V, Şit D, et al. Kronik hepatit-C virüsü enfeksiyonunda ekstrahepatik bulguların prevalansının değerlendirilmesi. *Türkiye Klinikleri J Med Sci* 2005;25:621-6.
30. Pittelkow MR, Daoud MS. Lichen planus. In: Wolff K, Goldsmith LA, Katz SI, Gilchrist BA, Paller AS, Leffell DJ, editors. *Fitzpatrick's Dermatology In General Medicine*. 7th ed. New York (NY): McGraw-Hill; 2008;1457.
31. Gisbert JP, Garcia Buey L, Pajares JM, et al. Prevalence of hepatitis C virüs infection in porphyria cutanea tarda: Systematic review and meta-analysis. *J Hepatol* 2003;39:620-7.
32. Chouela E, Abeldano A, Panetta J, et al. Hepatitis C virüs antibody (anti-HCV): Prevalence in psoriasis. *Int J Dermatol* 1996;35:797-9.
33. Kanazawa K, Aikawa T, Tsuda F, et al. Hepatitis C virus in patients with psoriasis. *Arch Dermatol* 1996;132:1391-2.
34. Muzaffar F, Hussain I. Hepatitis C: the dermatologic profile. *J Pakistan Assoc Dermatol* 2008;18:171-81.
35. Kassas ME, Hegazy OM, Salah EM. Effect of treating chronic hepatitis C with direct-acting antivirals on extrahepatic cutaneous manifestations. *World J Hepatol* 2020;12:841-9.
36. Tawfik YM, Hassany SM, Badran AY, et al. Hepatitis C virus associated skin manifestations in upper Egypt: Before and after direct acting antiviral treatment. *Dermatol Ther* 2020;33:e14365.
37. Wiznia LE, Laird ME, Franks AG. Hepatitis C virus and its cutaneous manifestations: Treatment in the direct-acting antiviral era. *J Eur Acad Dermatol Venereol* 2017;31:1260-70.
38. Kuna L, Jakab J, Smolic R, et al. HCV extrahepatic manifestations. *J Clin Transl Hepatol* 2019;7:172-82.
39. Mıstık R. Hepatit C virüs enfeksiyonunun epidemiyolojisi. In: Tabak F, Tosun S, eds. *Viral Hepatit 2013*. Ankara: Viral Hepatit Savaşım Derneği 2013:83-112.
40. Fortune BE, Francis S, Forman LM. Hepatitis C virus therapy-related skin manifestations. *Gastroenterol Hepatol* 2010;6(5):326-8.
41. Feld JJ, Kowdley KV, Coakley E, et al. Treatment of HCV with ABT-450/r-ombitasvir and dasabuvir with ribavirin. *N Engl J Med* 2014;370(17):1594-603.
42. Zekri AR, Bahnassy AA, Shaarawy SM, et al. Hepatitis C virüs genotyping in relation to neu-oncoprotein over expression and the development of hepatocellular carcinoma. *J Med Microbiol* 2000;49:89-95.
43. Halawani M. Screening of Hepatitis C virüs genotypes in urticaria patients in Saudi Arabia. *Genet Test Mol Biomarkers* 2012;16:964-7.