

# Melanoacanthoma / Pigmented Seborrhoeic Keratosis: A Rare Variant of a Common Entity

## Melanoakantom / Pigmente Seboreik Keratoz: Yaygın Bir Antitenin Nadir Bir Varyantı

Faheema Hasan,  
Pramila Anthony Singh,  
Nidhi Shukla

Consultant Pathologist, Anoop Laboratories  
Private Limited, Allahabad, India

Geliş Tarihi/Received: 01 April 2018  
Kabul Tarihi/Accepted: 11 April 2018

### Öz

Melanoakantom veya pigmente seboreik keratoz, sıklıkla yaşlı hastaların gövde, baş ve boyun bölgesinde ortaya çıkan, yoğun pigmente sahip, seboreik keratozun nadir bir varyantıdır. Melanoakantomların histolojik incelemesinde dendritik melanositlerin ve bazaloid keratinositlerin proliferasyonu izlenir. Lezyon klinik olarak malign melanomu taklit edebildiğinden, doğru tanı ve doğru klinik yönetim için histopatolojik inceleme yapılması gereklidir.

**Anahtar Kelimeler:** melanoakantom, seboreik keratoz, pigmentli poroma.

### Abstract

Melanoacanthoma or pigmented seborrhoeic keratosis is a rare variant of seborrhoeic keratosis which commonly occurs as deeply pigmented lesion in the head and neck or trunk of elderly patients. Melanoacanthomas shows proliferation of dendritic melanocytes and basaloid keratinocytes on histology. The lesion can clinically mimic malignant melanoma and variants a histopathological examination for the right diagnosis and proper management.

**Keywords:** Melanoacanthoma, seborrhoeic keratosis, pigmented poroma

## INTRODUCTION

Seborrhoeic keratosis is a common benign epidermal lesion. Melanoacanthoma is a rare variant of seborrhoeic keratosis composed of benign proliferation of keratinocytes and melanocytes (1). The term melanoacanthoma was introduced by Mishima and Pinkus in 1960 (2). Melanoacanthoma can be found both in skin and oral mucosa, however oral melanoacanthomas are reactive lesions, cutaneous melanoacanthomas are considered benign neoplastic lesions (3). It is imperative to identify this lesion as they may clinically misdiagnosed as malignant melanoma. We present a case of melanoacanthoma on the abdominal skin an elderly female.

## CASE

A 68 year old female presented to the outpatient department with postmenopausal bleeding. During examination, the gynecologist noticed a 4x4 cm

deeply pigmented elevated lesion on the abdominal wall and sent for dermatologic consult due to concerns for a malignant lesion. The dermatologist gave a clinical differential diagnosis of melanoacanthoma, pigmented hidroacanthoma and nodular malignant melanoma. A hysterectomy was performed for the abnormal vaginal bleeding and during the surgery; the clinician removed this pigmented lesion as well and sent for histopathology.

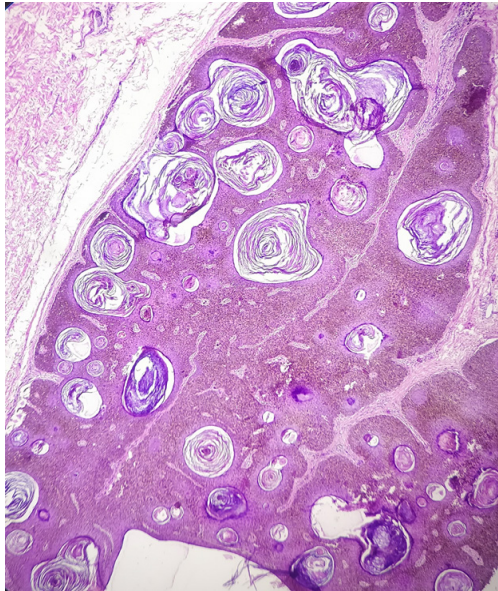
The abnormal vaginal bleeding was caused due to an endometrial polyp.

The skin lesion on the abdominal wall showed microscopically hyperkeratosis, acanthosis and papillomatosis with proliferation of small cuboidal keratinocytes and melanocytes and abundant melanin pigment (Figure 1). Melanocytes were noted in all layers of epidermis. Numerous horn cysts were noted (Figure 2). On higher power, there was no cytologic atypia (Figure 3). Dermis showed mild inflammatory

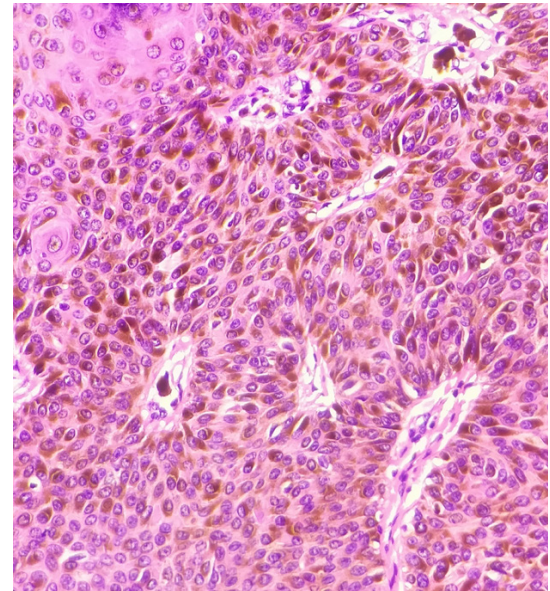
**Address correspondence to:** Faheema Hasan MD, Consultant Pathologist, Anoop Laboratories Private Limited, Allahabad, INDIA  
**e-mail:** 1faheemahasan@gmail.com

**Cite this article as:** Hasan F, Singh PA, Shukla Nidhi. Melanoacanthoma/ Pigmented Seborrhoeic Keratosis: A Rare Variant of a Common Entity. Selcuk Med J 2018;34(2): 74-76.

**Disclosure:** None of the authors has a financial interest in any of the products, devices, or drugs mentioned in this article. The research was not sponsored by an outside organization. All authors have agreed to allow full access to the primary data and to allow the journal to review the data if requested.



**Figure 1.** Elevated pigmented tumour with acanthosis, hyperkeratosis and papillomatosis. (H and E, 4x)



**Figure 3.** Proliferation of keratinocytes and melanocytes with abundant melanin pigment (H and E , 40x)

infiltrate. A histopathological diagnosis of pigmented seborrhoeic keratosis/melanoacanthoma was made.

## DISCUSSION

Seborrhoeic keratosis is a common benign epidermal lesions developing in the elderly. It is a neoplastic lesion composed of basaloid cells with variable degrees of squamoid differentiation. Many variants are described including acanthotic, adenoid,

keratotic, the term melanoacanthoma is used when the pigmentation in seborrhoeic keratosis is overwhelming (4).

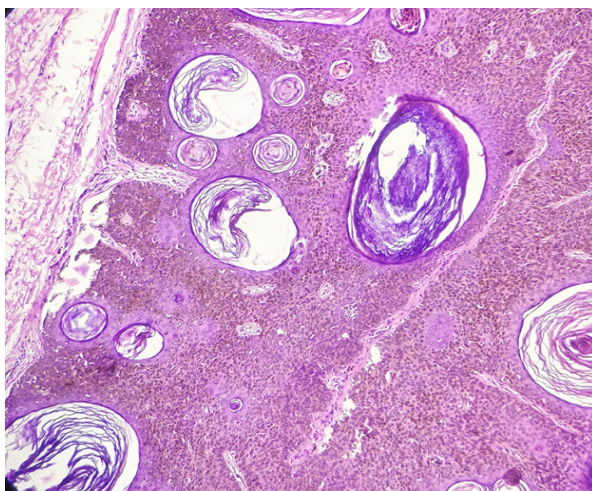
Melanoacanthoma is a rare variant of seborrhoeic keratosis. This term was coined by Mishima and Pinkus in 1960 which refers to a lesion exhibiting proliferation of dendritic melanocytes throughout the surface epithelium (2). It can be seen both in the oral mucosa and in the skin. Oral melanoacanthoma is a reactive lesion unrelated to cutaneous melanoacanthoma (3).

Cutaneous melanoacanthoma usually appears as solitary deeply pigmented lesion of the head and neck or trunk of older people. Microscopy shows an acanthotic lesion composed of keratinocytes and melanocytes with small keratin cysts without any atypia. Electron microscopic studies reveal that there is a disruption of transfer of melanin from these dendritic melanocytes to the adjacent keratinocytes (5).

This case is presented here owing to the rarity of the lesion and the clinical suspicion of a malignant lesion in a very benign lesion as the right diagnosis directs the proper management of the patient.

**Conflict of interest:** Authors declare that there is no conflict of interest between the authors of the article.

**Financial conflict of interest:** Authors declare that they did not receive any financial support in this study.



**Figure 2.** Multiple keratinous cysts seen in the epidermis (H and E, 10x)

**Address correspondence to:** Faheema Hasan MD,  
Consultant Pathologist, Anoop Laboratories Private Limited,  
Allahabad, INDIA,  
**e-mail:** 1faheemahasan@gmail.com

## REFERENCES

1. Vasani RJ, Khatu SS. Melanoacanthoma: Uncommon presentation of an uncommon condition. Indian Dermatology Online Journal 2013;4(2):119-21.
2. Mishima Y, Pinkus H. Benign mixed tumor of melanocytes and malpighian cells. Melanoacanthoma: Its relationship to Bloch's benign non-nevoid melanoepithelioma. Arch Dermatol 1960;81:539-50.
3. Lakshminarayanan V, Ranganathan K. Oral melanoacanthoma: A case report and review of the literature. J Med Case Rep 2009;3:11.
4. Phulari RG, Buddhdev K, Rathore R, et al. Seborrheic keratosis. J Oral Maxillofac Pathol 2014;18:327-30.
5. Schlappner OL, Rowden G, Philips TM, et al. Melanoacanthoma. Ultrastructural and immunological studies. J Cutan Pathol 1978;5:127-41.