

Cama Yumruk Atmaya Bağlı Üst Ekstremitte Hasarları

Striking Glass-Related Upper Extremity Injuries

Celalettin Sever, Yalçın Kulahçı, Cihan Sahin

Department of Plastic and Reconstructive Surgery and Burn Unit, Gülhane Military Medical Academy and Medical Faculty, Haydarpaşa Training Hospital, Istanbul, Turkey

Özet

Bu çalışmada, 2005 -2010 yılları arasında cama yumruk atma sonucu yaralanan 47 hasta retrospektif olarak incelenmiş ve bu hastalara ait dermografik veriler, travmanın şiddeti ve tedavi sonuçları araştırılmıştır.Cama vurma sonucu oluşan cilt laserasyonlarının uzunluğu,büyüklüğü genellikle hasara uğrayan nörovasküler yapıların sayısı ile doğru orantılı değildir.Küçük laserasyonlar daha derin dokularda çeşitli hasara neden olabilmektedir.Tedavide başarılı sonuç alabilmek için operasyon öncesinde hastanın dikkatlice fizik muayeneye tabi tutulması ve erken cerrahi girişimin yapılması gerekmektedir.

Anahtar kelimeler: Üst ekstremitte hasarları-El travmaları-Cama yumruk atma

Abstract

We carried out a retrospective and prospective study of 47 patients who had sustained injuries over the last three years from the hand passing through or striking glass. The demographic data, severity of injury, history of psychiatric illness and outcomes of the patients were evaluated. The preoperative examination of these injuries significantly underestimated the amount of damage. A simple and small laceration has the potential to conceal an underlying deep injury. For this reason, if glass is implicated as a causative agent, careful preoperative evaluation and surgical management should be considered.

Key words: Upper extremity injuries-Hand injuries-Striking glass

INTRODUCTION

Striking glass injuries of the upper extremity are the result of major social, public, and medical problems especially common in developing countries. These injuries are most commonly associated with preexisting psychiatric disorders and various predisposing factors, including chronic medical illnesses, lack of adequate mental health, substance and alcohol abuse, family instability, unemployment and low socioeconomic status. Striking glass injuries may cause neurovascular and functional damage. The severity of the damage depends on the injury size and depth. However, the size of the skin laceration does not correlate with the number of structures that are cut.1 Even when specifically performed to evaluate deficiencies, the preoperative examination may be absent or inadequate. The initial evaluation of these injuries significantly underestimated the extent of the damage. For this reason, if glass is implicated as a causative agent, careful surgical management should be considered. Although the majority of hand injuries are not life-threatening, these injuries may result in disabilities and deformities that require more complex reconstructions and a longer rehabilitation time, if missed in the initial evaluation. Early primary repair and good rehabilitation during the postoperative period are of great importance for successful outcomes.2 Despite their frequent occurrence, few data are available in the literature for these injuries. 3-6 The goals of the present study are to (1) categorize common patterns of injuries caused by striking glass, (2) identify the demographic data of the patients, (3) identify the epidemiologic features, (4) discuss the postoperative rehabilitation protocol, and (5) compare our findings with other data from the literature.

MATERIALS AND METHODS

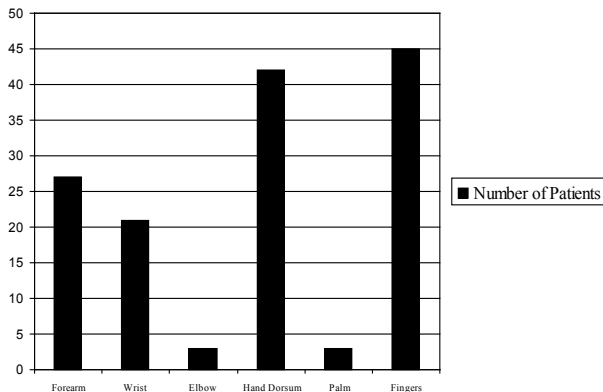
The study was performed on 47 patients who were treated for hand injuries caused by striking glass in the Department of Plastic Surgery,

the GATA Haydarpaşa Training Hospital between the 2005 and 2010. Of the 47 patients, 42 were male and 5 female, with an average age of 22.4 years (range 16–46 years). The intoxicated state of some patients was determined after an interview with the patient, his/her family, and a physical examination. The demographic data of the patients were recorded. The patients were evaluated for evidence of tendon, nerve, or vascular injuries. All injuries were sharp lacerations caused by striking glass. Crush or avulsive injuries were excluded from this study. Patients with associated hand fractures were also excluded.

All patients were seen within three hours after the injury, and underwent primary repair. Following anti tetanic serum and wound debridement, all the injured structures in the upper extremity were simultaneously repaired after placement of a pneumatic tourniquet. Under tourniquet control, exposure is obtained by an incision extending both proximally and distally. The carpal tunnel was opened when lacerations occurred at the distal wrist crease with the wrist in flexion. After the surgery, the patients were usually discharged from the hospital on the seventh postoperative day. Following the surgery, the wrist was immobilized at 30 degree of flexion in a dynamic splint for three weeks. Postoperatively, active extension and passive finger flexion was carried out for the first four weeks. At 4–6 weeks the patient began protective early motion. The mean length of follow-up was 16 months with a range of 6-22 months.

RESULTS

Forty-seven patients were included in the study. The mean age of the patients was 22.4 years. Forty patients had right lesions and seven patients had left extremity lesions. The injury was localized to the forearm in 27 patients (57.44%), elbow in 3 (6.38%), wrist in 21 (44.68%), hand dorsum in 42 (89.36%), palm in 3 (6.38%), and fingers in 45 patients

Table 1. The localization of injuries

(95.74%) (Table 1). Striking glass injuries were predominantly located at the flexor side of the wrist and at the dorsum of the fingers. A predilection for wrist ulnar-sided injuries was observed, reflecting the role of the ulnar border of the pronated hand as the leading contact surface. The most frequently injured structures were the extensor digitorum tendons in 40 patients (85.71%), flexor carpi ulnaris in 18 (38.29%), palmaris longus in 18 (38.29%), ulnar nerve in 15 (31.90%), median nerve in 14 (29.78%), ulnar artery in 12 (25.53%), radial artery in 5 (10.63%), and superficialis and profundus flexor tendons in 3 (6.38%). Combined flexor carpi ulnaris, ulnar nerve, and ulnar artery (ulnar triad) injuries occurred in 25.53% of the patients while combined median nerve, palmaris longus, and flexor carpi radialis injuries (radial triad) occurred in 10.63% of cases. Simultaneous injuries of both the ulnar and radial arteries occurred in 6.38% of patients. Simultaneous injuries of both the median and ulnar nerves occurred in 4.25% of patients. Of the total 47 patients, 27 (57.44%) had been previously diagnosed with a psychiatric disorder and 17 (36.17%) had deliberately harmed themselves in the past. At the time of the hand injury, 42.55% of the patients were on medications for psychiatric disorders. The most common primary diagnoses were depression and schizophrenia. Major depression had been diagnosed in 14 of 47 patients (Table 2). A history of drug abuse was identified in 12 (25.53%) patients.

The occupational status of the patients is shown in Table 3. Four patients (12.5%) were unskilled workers and 68.7% (22/32) were unemployed. Furthermore, 27 of 32 patients (84.3%) were of a low socioeconomic status. A predisposing factor could be identified in 17 of 32 patients. A failure of interpersonal relationships (i.e., unmarried, divorced, lack of love, lack of children, difference of age, premature marriage, fight with wife or family misunderstanding, fight with friends) was the identified cause in 29 of 47 patients. Other factors identified included drug abuse in 12 (25.53%), personality disorders in 2 (4.25%), and chronic disease in (12.2%) patient. Therefore, all our patients received consultations with a psychiatrist and social worker during their

Table 2. Previous psychiatric disorder history

Psychiatric History	Number of Patients (%)
No psychiatric disorders	20 (42.55 %)
Previous self harmed	17 (36.17 %)
Depression	14 (29.78 %)
Schizophrenia	3 (6.38 %)
Post Traumatic Stress Disorder	2 (4.25 %)

Table 3. Occupational status of patients

Occupational state	patients (%)
Soldier	26 (55.31 %)
Unskilled worker	10 (21.27 %)
Unemployed	6 (12.76 %)
Student	3 (6.38 %)
Others	2 (4.25 %)

long hospital stay. All patients had continuous psychiatric treatment during this period. After discharge, most of the patients were referred to different health centers for further psychiatric treatment and social work support.

DISCUSSION

Striking glass injuries are a common cause of severe neurovascular damage. These injuries frequently result in damage to many anatomic structures of the hand. Despite their relatively frequent occurrence, few data are available in the literature to characterize these injuries. Many victims in this group have multiple scratches, abrasions and superficial incisions. The laceration margins may be clean-cut or irregular.⁷ The size of the skin laceration did not correlate with the number of structures that were cut. Small laceration injuries of the upper extremity have the potential to conceal an underlying deep injury.⁸ Striking glass injuries may result in disabilities and deformities that require more complex reconstructions and longer rehabilitation if missed during the initial evaluation.⁹ In addition, the preoperative examination significantly underestimates the extent of the damage even when specifically done to evaluate for deficiencies. For this reason, early surgical exploration is critical to successful management. The superficial location of tendons, nerves and vessels on the volar aspect of the wrist make them particularly vulnerable to penetrating trauma. There are three different components to these multiple-structure lacerations: (1) multiple flexor and extensor tendons, (2) the median nerve, ulnar nerve, or both, and (3) the radial artery, ulnar artery, or both. To understand these complex injuries it is helpful to analyze each of these frequently injured structures. In our study, there seemed to be a tendency for ulnar-based injuries. The most common pattern of injury involved the flexor carpi ulnaris, ulnar nerve and artery, or the so-called ulnar triad. A laceration caused by striking glass and located on the volar side of the wrist or forearm must raise suspicion for a combination injury

When a laceration is located on the extensor side of the fingers, the more superficial tendons may not be the only ones injured. In our study the extensor tendon lacerations predominated in number except for injuries to the finger region; this finding was substantiated by other findings in the literature.^{9,10} Vascular injuries due to striking glass are well described in the literature; however, there may be a considerable number of missed vascular injuries.⁹ Therefore, the examiners have to look for a deep arterial injury because a single vascular injury may not result in any deformity or disability due to the dual vascularization of the upper extremity. In our study the average age of the patients was under 25 years and most patients were soldiers or unskilled manual workers. There was a preponderance of male patients (89.36%) that may be explained by the disoriented male psychology under the pressure of marital, unemployment or low socioeconomic problems in our society. In addition, our clinic belongs to a military hospital; therefore, it seems that being male in our population is one of the risk factors for glass injury of the upper extremity. The predisposing factors of this injury according to our data were a failure of interpersonal relationships, drug abuse and

personality disorders. For this reason, striking glass injures represent a serious medical and socioeconomic problem. Even when minor, penetrating injuries by glass should be regarded as "potential lacerations" for more serious injuries. Any suspicion of a deep injury necessitates surgical exploration. Immediate exploration and primary repair is safe and has a good outcome, depending on good physiotherapy. In addition, striking glass injuries cause a major disability in a society. It is necessary to develop preventive programs and to educate the susceptible patient group in military forces to decrease the occurrence of this injury.

REFERENCES

1. Iconomou TG, Zuker RM, Michelow BJ. Management of major penetrating glass injuries to the upper extremities in children and adolescents. *Microsurgery*. 1993;14(2):91-6
2. Yüksel F, Peker F, Açikel C, Celiköz B. Ann Plast Surg. Second hand management of "spaghetti wrist": do not hesitate to explore. 2002 Nov;49(5):500-4;
3. Puckett, C. L., and Meyer, V. H. Results of treatment of extensive volar wrist lacerations: The spaghetti wrist. *Plast. Reconstr. Surg*. 75: 714, 1985.
4. Widgerow, A. D. Full-house/spaghetti wrist injuries. *S. Afr. J. Surg*. 28: 6, 1990
5. Rogers, G. D., Henshall, A. L., Sach, R. P., and Wallis, K. A. Simultaneous laceration of the median and ulnar nerves with flexor tendons at the wrist. *J. Hand Surg*. 15A: 990, 1990
6. Hudson, D. A., and deJager, L. T. The spaghetti wrist: Simultaneous laceration of the median and ulnar nerves with flexor tendons at the wrist. *J. Hand Surg*. 18B: 171, 1993
7. Karger B, Rothschild MA, Pfeiffer H. Accidental sharp force fatalities- beware of architectural glass, not knives. *Forensic Sci Int*. 2001 Dec 1;123(2-3):135-9
8. Tuncali D, Yavuz N, Terzioglu A, Aslan G. The rate of upper-extremity deep-structure injuries through small penetrating lacerations. *Ann Plast Surg*. 2005 Aug;55(2):146-8
9. Jarvik JG, Dalinka MK, Kneeland JB. Hand injuries in adults. *SeminRoentgenol*. 1991;26:282-299
10. Broback LG, Ekdahl PH, Aschan GW, et al. Clinical and socio economical aspects of hand injuries. *Acta Chir Scand*. 1978;144:455-461