

Sağ Sinus Valsalva'dan Çıkan Sağ Koroner Arter, LAD ve Cx Anomalisi

Anomaly of Right Coronary, LAD, and Cx Arteries Originating From Right Sinus Valsalva

¹Aydin Akyuz, ²Ramazan Uygur, ¹Seref Alpsoy, ²Veli Caglar, ¹Dursun Cayan Akkoyun, ²Bilal Burak Baltaci

¹Department of Cardiology, Faculty of Medicine, Namik Kemal University, Tekirdag, Turkey

²Department of Anatomy, Faculty of Medicine, Namik Kemal University, Tekirdag, Turkey

Özet

Tek koroner arter bütün koroner arter anomalileri içerisinde yaklaşık olarak % 2-4 oranında gözlenir. Bizim vakamızda, 48 yaşında bayan hastada egzersize bağlı göğüs ağrısı ve yorgunluk vardı. Hastanın egzersiz elektrokardiogramında 9 mets iş gücünde ST depresyonu sonrası, biz koroner anjiyografide orijinal sol ana koroner arterin yerinde olmadığını sol ön inen arterin ve sirkumfleks arterin sağ sinus Valsalvadan sağ koroner arterle birlikte çıktığı çok nadir bir tek çıkışlı koroner arter anomalisi olduğunu gösterdik. Medikal tedavi olarak beta bloker ile hastanın semptomları düzeldi. Bu tip koroner arter anomalileri oldukça seyrek ve ani ölüm sebebi olabilir.

Anahtar kelimeler: Anomali, Sağ koroner arter, Sol ön inen arter, Sirkumfleks arter, Sağ sinus Valsalva

Abstract

Single coronary artery is observed in approximately 2-4% of all coronary artery anomalies. In our case, 48 years old female patient had exercise-induced angina pectoris and fatigue. After her exercise electrocardiogram revealed ST depression during 9 mets, we demonstrated a single coronary artery as an extremely rare anomaly of coronary artery in which there was no original left main artery as well as right coronary artery, left anterior descending and circumflex arteries were originated from right sinus Valsalva. On medical treatment with beta blocker, her symptoms had recovered. This type of coronary anomalies is very infrequent and may be a reason of sudden death.

Key words: Anomaly, Right coronary artery, Left anterior descending artery, Circumflex artery, Right sinus Valsalva

INTRODUCTION

There are three main arteries in the heart; right coronary artery (RCA), left anterior descending artery (LAD), circumflex artery (Cx). RCA originates from the right aortic sinus. The left coronary artery (LCA) originates from the left aortic sinus. LAD and Cx are two terminal branches of LCA. The incidence of coronary artery anomalies is 1.3% in coronary arteriography (1). Single coronary artery is a rare coronary anomaly occurring in approximately 0.024%-0.066% of the population (2,3). In this report, we presented a patient with an extremely rare anomaly of coronary artery in which RCA, LAD, and Cx arteries were arising from right sinus Valsalva as well as there was no original left main artery. This coronary anomaly pattern is very rare seen, may cause angina, syncope and sudden cardiac death.

CASE

Forty eight years old female patient has applied to our clinic with complaints of fatigue and chest pain during exercise for two years. She was transferred from clinic of internal medicine for further study. She had only hypertension as a cardiovascular risk factor. Physical examination, chest X-ray, electrocardiography were all normal. There was only grade 1 diastolic dysfunction and left ventricle hypertrophy on transthoracic echocardiography. Exercise treadmill stress testing was abnormal during 9 mets. So, coronary angiography was planned. We have noticed that

there exists no left sinus Valsalva during the procedure of selective left coronary injection via left Jutkins catheter even though anatomically left sinus Valsalva was expected on that localization. We showed that there was no left main coronary artery and RCA, LAD, and Cx trifurcated into a short single coronary artery which arising from right sinus Valsalva (Figure 1 and Figure 2).

The opacifying of three separate coronary anatomy with one catheter was difficult, and risky because of coronary anatomy feeding from only one ostium. This relation could be visualized only with a careful procedure. There was no atherosclerotic lesion. Relative ischemia due to hypertensive left ventricle hypertrophy was considered based on causes were probable angina and fatigue. In our case, left main coronary artery could not be visualized and on the course of LAD, there was intraseptal course, not clinically important. Medical therapy was planned due to ischemic changes during 9 mets in treadmill. Our case was discharged with medication on beta blocker.

DISCUSSION

Coronary artery anomalies are quite rare, and discovered incidentally during coronary angiography or autopsy. Sometimes, very rare forms are observed. Very infrequent type is a type in which all coronary artery systems (LAD, CX as well as RCA) are originated from one location. The frequency of this type anomaly was 0.024% (4) and 0.017% (1) in

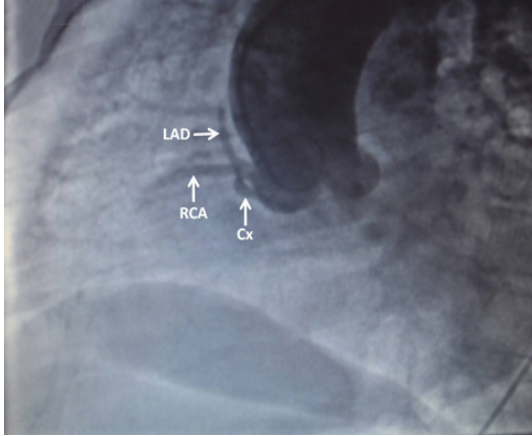


Figure 1. RCA, LAD, and Cx trifurcated after a very short single coronary artery originated from right sinus Valsalva. RCA: Right coronary artery; LAD: Left anterior descending artery; Cx: Circumflex artery.

to big series. The cases of single coronary artery originating from right coronary sinus have risky of mortality before young adulthood. Death commonly occurs during heavy physical activity due to coronary vessel compression. The cases with coronary anomaly coursing between aorta and pulmonary trunk should be operated in case the presence of symptoms such as angina pectoris, myocardial ischemia, syncope and ventricular severe arrhythmias (5). In our case, we demonstrated as an anomaly of coronary artery in which there was no original left main artery and RCA as well as LAD and Cx arteries were originated from right sinus Valsalva. In this case, we found coronary angiography as gold standard good enough since the anomaly could be visualized sufficiently. We did

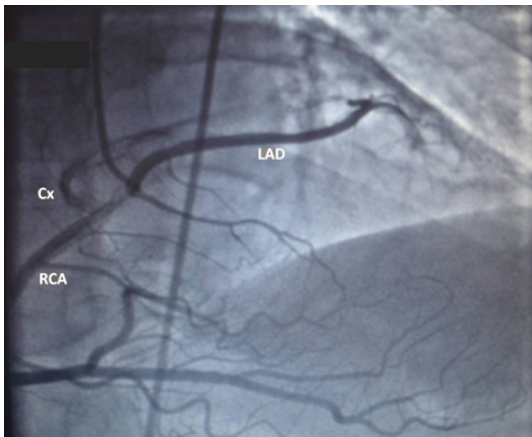

Figure 2. Dominant RCA as well as LAD and Cx arising from right sinus Valsalva and reaching their anatomical area. RCA: Right coronary artery; LAD: Left anterior descending artery; Cx: Circumflex artery.

not need other imaging systems such as computerized tomography and magnetic resonance imaging. Single coronary artery anomalies were classified by Lipton et al. (2) according to the place of RCA or LCA origin, its anatomical distribution, and its relation to ascending aorta and pulmonary artery.

The anomalies of relation of the course of left main coronary artery originating from right sinus Valsalva between aorta and pulmonary artery is attracting attention for sudden death (6). When single coronary artery courses between the aorta and pulmonary trunk is high risk of sudden cardiac death, because of coronary artery compression, especially during exercise. However, other coursing such as front or behind of aorta and pulmonary trunk may cause ischemia, ventricular arrhythmias and sudden death (2). In our case, demonstrated that after originating from right coronary sinus, a very short single coronary artery trifurcated into RCA, LAD, and Cx. RCA was dominant and well-developed. There is a single case very similar to our case reported by Şahin and Bozkurt (7). In our case, LAD artery was coursing in front of the pulmonary trunk and Cx artery was coursing behind of aorta and then reaching to posterior left ventricle. We discharged with medical treatment because we assumed that there was no sudden cardiac death risk for our case who have no compression between the aorta and pulmonary trunk.

KAYNAKLAR

1. Yamanaka O, Hobbs RE. Coronary artery anomalies in 126,595 patients undergoing coronary arteriography. *Cathet Cardiovasc Diagn* 1990; 21: 28-40.
2. Lipton MJ, Barry WH, Obrez I, Silverman JF, Wexler L. Isolated single coronary artery: diagnosis, angiographic classification, and clinical significance. *Radiology* 1979; 130: 39-47.
3. Desmet W, Vanhaecke J, Vrolix M, et al. Isolated single coronary artery: a review of 50,000 consecutive coronary angiographies. *Eur Heart J* 1992; 13: 1637-40.
4. Akcay A, Tuncer C, Batyraliev T, et al. Isolated single coronary artery: a series of 10 cases. *Circ J* 2008; 72: 1254-8.
5. Dogan SM, Gursurer M, Aydin M, Göcer H, Cabuk M, Dursun A. Myocardial ischemia caused by a coronary anomaly left anterior descending coronary artery arising from right sinus of Valsalva. *Int J Cardiol* 2006; 112: e57-9.
6. Cheitlin MD, De Castro CM, McAllister HA. Sudden death as a complication of anomalous left coronary origin from the anterior sinus of Valsalva, A not-so-minor congenital anomaly. *Circulation* 1974; 50: 780-7.
7. Şahin DY, Bozkurt A. Anomalous single coronary artery presenting as typical angina pectoris: a case report. *Arch Turk Soc Cardiol* 2010; 38: 121-4.