

Üst Özefagial Polipin Endoskopik Rezeksiyonu, Özefagial Leiomyomun Sıra Dışı Yerleşimi

Endoscopic Resection of Upper Esophageal Polyp, Unusual Location of Esophageal Leiomyoma

¹Adnan Şahin, ²Özgür Türk

¹Eskisehir Osmangazi University General Surgery Department; Osmangazi University Meselik campus Eskisehir
²Sivrihisar State Hospital General Surgery Department; Yunusemre Street Sivrihisar Eskisehir

Özet

Özefagial benin tümörler nadir görülen lezyonlardır. Özefagusun üst 1/3 bölümünde yerleşimleri oldukça nadirdir. Özefagial poliplerin endoskopik olarak çıkartılması ile ilgili bilgiler henüz yaygın değildir. Endoskopik prosedürün teknik zorlukları olmakla beraber işlem sonrası hemostazın sağlanmasında zor olabilir. 60 yaşında bayan bir hastada polipektomi loop'u kullanarak başarılı olarak polibi tamamen çıkarttığımız vakayı sunuyoruz. Üst özefagus leiomyomları nadir görülen klinik tablolardır. Özefagial leiomyomaların tanısı hem radyolojik olarak hem de endoskopik olarak yapılmalıdır. Salin enjeksiyonu metodu pediküllü poliplerin endoskopik olarak çıkartılmasında başarılı bir yöntem olabilir.

Anahtar kelimeler: Endoskopik rezeksiyon, leiomyoma, özefagial polipler

Abstract

Esophagial benign tumors are limited seen lesions. Rarely located at the upper one third part of the esophagus. Endoscopic removal of esophageal polyps has been declared infrequently. The procedure has technical difficulties and after the polypectomy hemostasis can be hard. We performed a successful endoscopic polypectomy handling a polypectomy loop to ablate the polyp in a 60-year-old woman patient. Leiomyoma of upper esophagus is a rare clinical situation. The diagnosis of esophageal leiomyomas must be achieved both endoscopic and radiologic examinations. Saline injection can be a useful method for endoscopic resections of pediculed polyps.

Key words: Endoscopic resection, leiomyoma, esophageal polyps

INTRODUCTION

Esophageal polyps are a common in clinical practice. Esophageal benign tumors are limited seen lesions. Less than 1% of esophageal neoplasms are benign. Leiomyoma constitutes almost two third part of benign esophageal tumors; the others are usually polyps and cysts [1]. They commonly originate from esophageal wall and grow intramurally. Rarely located at the upper one-third part of the esophagus. Endoscopic removal of esophageal polyps has been reported rarely. The procedure has technical difficulties and after the polypectomy haemostasis can be hard [2].

CASE

A 60-years-old woman underwent upper endoscopy because of odynophagia, dysphagia, and nausea and vomiting during one-year. In last month, difficulty of swallowing solid foods and heartburn added her complaints. Her medical history was unremarkable. In addition, her family history was ordinary. Physical examination revealed no abnormalities. Blood tests were usual. Serum tumor markers were normal. Upper Endoscopy revealed a pedunculated polyp; covered with the mucosa and located upper one third of esophagus. Polyp was localized at 15 cm of esophagus from the incisor teeth's. Thoracal computed tomography (CT) revealed polypoid lesion at the subcarinal esophageal segment (Figure 1). The esophageal mucosa was pristine. Any evidence of infiltration into

neighboring organs and mediastinal lymph node can not be detected. Metastasis or invasive carcinoma of esophagus not detected. We performed a successful endoscopic polypectomy handling a polypectomy loop. Sedation anaesthesia performed during procedure. Loading dose of 40 mg to 50 mg propofol is given with anymore smaller bolus dose of 10 mg [3]. Upper gastrointestinal endoscopy was performed with a standard forward-viewing video endoscope. Before the endoscopic resection of polyp we injected saline to the root of the polyp. Salin is injected using a standard sclerotherapy needle. Multiple injections of 2 ml salin has given around of the polyp. We aimed to prevent possible perforation of the esophagus. The resection was performed with an electrosurgical polypectomy loop by using cautery device. After polypectomy there was no visible residual polyp. At the polypectomy site a minor bleeding was observed. Bleeding stopped without any further intervention. After procedure there was not any complication. Esophageal polyp specimen was taken out with biopsy snare. Formalin solution used for fixation. Diameter of polyp was 3x3 cm. Histopathologic examination revealed polypectomy specimen was in leiomyoma pattern (Figure 2). Surgical margins were intact. The patient was remained well. Four days later discharged to home. Patients complaint has disappeared. 4 weeks later we performed control upper endoscopy. There was minimally ulcer area at the location of ligation and no more polyp esophagus.

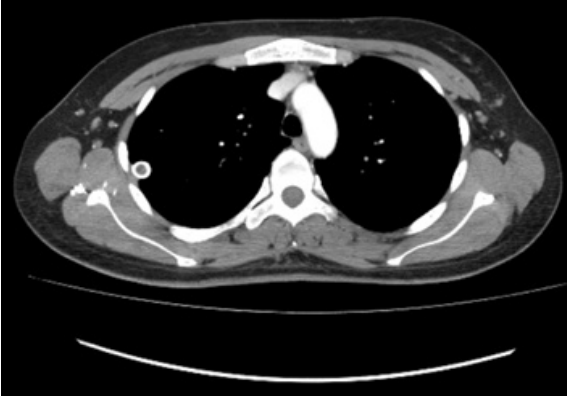
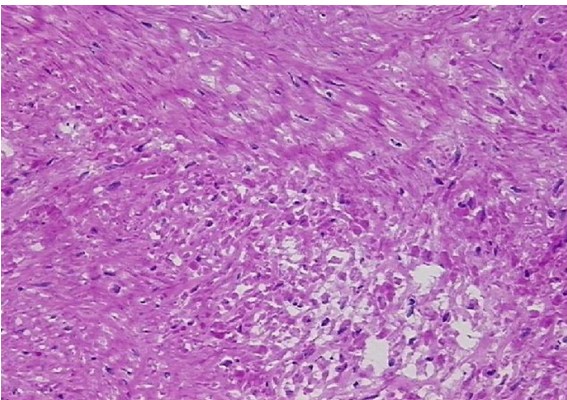


Figure 1. CT scan of esophageal polyp.

DISCUSSION

Esophageal leiomyomas smaller than 5 cm in diameter are rarely cause symptoms. In some cases to confirm the histopathological diagnosis polypectomy may be required [1]. Leiomyomas growth pattern is usually intramural. Approximately %5 of leiomyomas are multiple seen in cases. Most commonly diagnosed alongside of the distal two third part of the esophagus [4]. Esophageal leiomyomas smaller than 5 cm not cause symptoms. If it is greater than 5 cm dysphagia, retrosternal heartburn, chest pain, esophageal obstruction, and regurgitation may occur. Gastrointestinal bleeding is a rare symptom. Physical findings are not usually noted [1]. During the upper endoscopy the polyps are seen as mobile submucosal masses. If a polyp of esophagus is detected at upper endoscopy, endoscopist should abstain to perform biopsy because of creating scar at the biopsy site. Scarring polyp can fetter resection at surgery. However, due to risk of malignancy biopsy can be performed for ulcerated lesions [4]. Endoscopy usually shows a mobile intraluminal covered with normal mucosa. Pedunculated polyps can be diagnosed by careful examination of the upper esophageal sphincter. Discriminate between esophageal inflammatory fibrous polyp and leiomyoma is



Şekil 2. Histopatologic examination of polyp. H&E staining, x200 magnification, leiomyoma.

usually easy. Inflammatory fibrous polyps are usually flat, and non-pedunculated lesions in the middle and lower third part of the esophagus [5]. Endoscopic procedures look like possible in some cases that small pedunculated polyps of 2-4 cm originating from the muscularis mucosae [6]. In our case, an upper endoscopy was performed and we diagnosed a pedunculated esophageal polyp. We performed CT scan to determine other pathological findings. CT scan demonstrated that there was no evidence of local and distant metastases or mediastinal lymph node. Endoscopic polypectomy was performed as a second seans afterwards screening. Polypectomy loop should be stay away from the substratum of polyp to avoid of esophageal perforation. Endoscopic resection with sub mucosal saline injection is effective method to perform a successful resection of esophageal polyps. If needed, Post-polypectomy hemostasis can be accomplished with adrenaline injection to bleeding area and using hemoclips can be useful [7].

The diagnosis of esophageal leiomyomas must be achieved both endoscopic and radiologic examinations. Once the clinical diagnosis of leiomyoma is established if there is not any evidence of infiltration into neighboring organs and mediastinal lymph node endoscopic resection can be performed. Saline injection can be a useful method for endoscopic resections of pediculed polyps. Leiomyoma of upper esophagus is a rare clinical situation.

REFERENCES

1. Mutrie CJ, Donahue DM, Wain JC, Wright CD, Gaissert HA, Grillo HC. Esophageal leiomyoma: a 40-year experience. *Ann Thorac Surg* 2005;79:1122-5.
2. Zhang J, Hao JY, Li SW, Zhang ST. Successful endoscopic removal of a giant upper esophageal inflammatory fibrous polyp. *World J Gastroenterol* 2009;15:5236-8.
3. Byrne MF, Chiba N, Singh H, Sadowski DC. Propofol use for sedation during endoscopy in adults: a Canadian Association of Gastroenterology position statement. *Canadian Journal of Gastroenterology* 2008;22:457.
4. Wang Y-j, Zhang R, Ouyang Z, Zhang D, Wang L. Diagnosis and surgical treatment of esophageal leiomyoma. *Zhonghua zhong liu za zhi .Chinese J Oncol* 2002;24:394-6.
5. Levine MS, editor .Benign tumors of the esophagus: radiologic evaluation. *Seminars in Thoracic and Cardiovascular Surgery*; 2003: Elsevier.
6. Kajiyama T, Sakai M, Torii A, Kishimoto H, Kin G, Uose S. Endoscopic aspiration lumpectomy of esophageal leiomyomas derived from the muscularis mucosae. *Am J Gastroenter* 1995;90:417-22.
7. Narahara H, Iishi H, Tatsuta M, Uedo N, Sakai N, Yano H. Effectiveness of endoscopic mucosal resection with submucosal saline injection technique for superficial squamous carcinomas of the esophagus. *Gastrointest Endoscopy* 2000;52:730-4.