

# Cavernous Sinus Thrombosis in an Older Patient

## İleri Yaş Kavernöz Sinüs Trombozlu Bir Olgu

Dilcan Kotan<sup>1</sup>,  
Aslı Aksoy Gündoğdu<sup>2</sup>,  
Gürkan Kayabaşoğlu<sup>3</sup>

<sup>1</sup>Department of Neurology, Medical School, Sakarya University, Sakarya, Turkey

<sup>2</sup>Neurology Clinic, The Ministry of Health Sakarya University Research and Training Hospital, Sakarya, Turkey

<sup>3</sup>Department of Ear-Nose & Throat, Medical School, Sakarya University, Sakarya, Turkey

Geliş Tarihi/Received: 19 February 2015

Kabul Tarihi/Accepted: 25 April 2015

### Özet

İskemik inmenin nadir nedenlerinden olan kavernöz sinüs trombozu, yaşamı tehdit eden bir durumdur. Mortalitesi yüksektir ve klinik olarak kranyal sinir tutulumu ve görme kaybı dahil morbiditeye yol açabilir. Kavernöz sinüs trombozu enfeksiyöz veya nonenfeksiyöz kaynaklı oluşabilir. Bu çalışmada, iyi gidişli, nonenfeksiyöz, ileri yaş kavernöz sinüs trombozlu nadir bir kadın olgu sunulmuştur.

**Anahtar kelimeler:** Kavernöz tromboz, ileri yaş, MRG

### Abstract

The cavernous sinus thrombosis is a very rare and life-threatening condition. The mortality rate remains high, and significant morbidity includes residual cranial nerve palsies and blindness. The causes of cavernous sinus thrombosis are infectious or aseptic. We report well-progressed a rare case of aseptic thrombosis of the cavernous sinus in an older patient.

**Keywords:** Cavernous sinus thrombosis, elderly, MRI

## INTRODUCTION

Cavernous sinus thrombosis (CST) is encountered among rare causes of ischemic stroke (1-2%). It occurs mostly in children and young adults, often of a complicating of a local infectious process (1,2). Although the cause of cavernous sinus thrombosis is frequently an infection, it may also occur a result of aseptic conditions including trauma, tumor invasion, aneurysmal expansion, dehydration and hypercoagulable states (2,3). The mechanisms of aseptic CST include the occlusion of cerebral veins or dural sinuses leading to cerebral edema, parenchymal damage, or hemorrhage. Clinically it may manifest itself with headache, nausea and vomiting, changes in consciousness, cranial nerve involvement, vision loss and epileptic seizures (3,4). and it may result in death in up to 30-50% of all cases (1,2). CT with contrast and MRI have a significant impact on the diagnosis of CST (4). We present here an unusual case of aseptic CST in an elderly woman which responded to anti-coagulation therapy.

## CASE

A 85 years old, female patient presented with complaints of ptosis of the right eyelid, double vision, half-cranial headache on the right side like a flash of lightning and numbness in the right half of the face. Her past medical history revealed that she had hypertension and hyperthyroidism for 20 years.

On her neurological examination, ptosis in the right side, edematous right eyelid, limitation of right eye in every directions, hypoesthesia on the right half of the face were detected. Laboratory results were normal other for increased serum C-reactive protein concentrations (8.54 mg/L, normal range: 0-5 mg/L). On MRI examination, there were widespread ischemic and gliotic infarct areas widespread bilaterally in the periventricular white matter as well as widespread cortical atrophy. Significantly, a 36x30 mm sized lesion was detected in the right cavernous sinus, which was peripherally hyperintense and centrally iso intense thrombosis in T1 sequence (Figure 1), and hyperintense in FLAIR and T2 sequences (Figure 2). Ear-nose and throat (ENT) examination was within normal limits. Paranasal CT and vasculitic markers were all normal. Aseptic CST was diagnosed on the basis of clinical course and MRI findings. The patient was started warfarin treatment with the diagnosis of CST. On follow-up, her symptoms were partially resolved, and she continues to be maintained on warfarin therapy.

## DISCUSSION

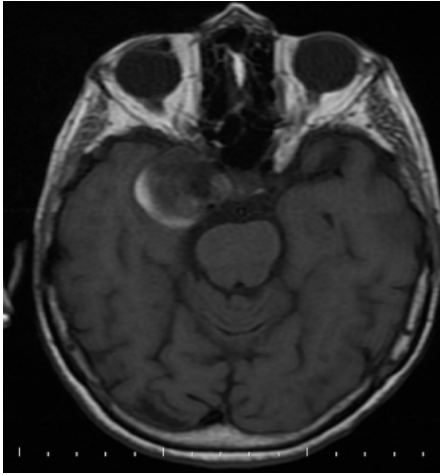
CST is an uncommon condition with a variable and often dramatic clinical presentation. CST may be encountered as a result of infectious or non-infectious etiology. Aseptic causes typically occur after surgery and after trauma (2,5). Our patient didn't have any

**Address correspondence to:** Dilcan Kotan, Sakarya University, Medical School, Department of Neurology, 54070 Sakarya, Turkey

**e-mail:** dilcankotan@yahoo.com

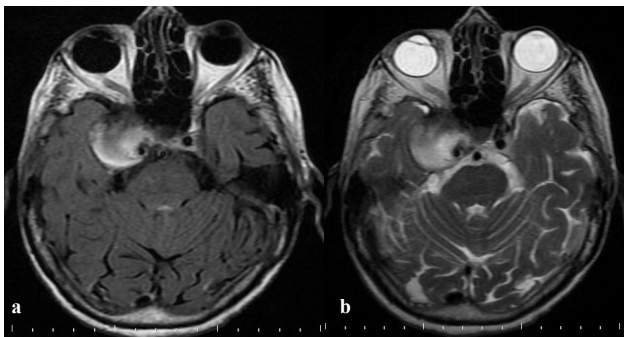
**Cite this article as:** Kotan D, Gündoğdu AA, Kayabaşoğlu G. Cavernous Sinus Thrombosis in an Older Patient. Selcuk Med J 2018;34(1): 34-35.

**Disclosure:** None of the authors has a financial interest in any of the products, devices, or drugs mentioned in this article. The research was not sponsored by an outside organization. All authors have agreed to allow full access to the primary data and to allow the journal to review the data if requested.



**Figure 1.** In MRI, a lesion in the right cavernous sinus, peripherally hyperintense and centrally isointense thrombosis in T1 sequence.

history of trauma and surgery. CST is a serious condition. It is critically important to recognize the early signs of cavernous thrombosis. The headache is the most common symptom, usually preceding fevers, periorbital edema, and cranial nerve signs. These clinical presentations are due to sinus obstruction and impairment of the cranial nerves that near of the cavernous sinus (1,3). Our patient presented with headache, ocular signs and hypoesthesia on the right half of the face. The diagnosis of CST is best established on clinical course and confirmed by neuroimaging studies. CT with contrast or MRI is useful in the assessment of cases with clinical features of CST (4). In our patient, cranial MRI showed CST in right cavernous sinus. CST is more commonly encountered in young or middle-aged individuals with female predominance, and it has high mortality (6,7). Our patient is a female but an older age and



**Figure 2.** In MRI, a lesion in the right cavernous sinus, which was hyperintense in FLAIR (a) and T2 sequences (b).

well-progressed. Other more progressive or chronic conditions may cause painful ophthalmoplegia owing to involvement of the cavernous sinuses, including granulomatous diseases such as tuberculosis or fungal infection, sarcoid, syphilis or Tolosa-Hunt syndrome. Granulomatous and septic events were excluded in our patient based on clinical, laboratory and MRI findings. Treatment of CST is directed to the underlying cause, therefore an accurate diagnosis is essential. In the aseptic cases, this may include treatment of fractures and correction of vascular malformations (6,8). There were no such underlying causes in our patient. Because of her older age, she was maintained and followed on anti-coagulant therapy with no additional invasive interventions. The case is presented here because well-progressed, non-infectious, advanced age CST in a older age female patient is rarely encountered.

#### **Acknowledges**

Written informed consent was obtained from the patient for publication of this report and any accompanying images.

**Conflict of interest:** Authors declare that there is no conflict of interest between the authors of the article.

**Financial conflict of interest:** Authors declare that they did not receive any financial support in this study.

**Yazışma Adresi:** Dilcan Kotan, Sakarya University, Medical School, Department of Neurology, 54070 Sakarya, Turkey  
e-posta: dilcankotan@yahoo.com

#### **REFERENCES**

1. Piazza G. Cerebral venous thrombosis. *Circulation* 2012;125(13):1704-09.
2. Saposnik G, Barinagarrementeria F, Brown RD, et al. Diagnosis and management of cerebral venous thrombosis: a statement for healthcare professionals from the American Heart Association/American Stroke Association. *Stroke* 2011;42(4):1158-92.
3. Gobron C, Guichard JP, Chabriat H. Thrombose du sinus caverneux. *Sang Thrombose Vaisseaux* 2004;16(3):130-8.
4. Schuknecht B, Simmen D, Yuksel C, et al. Tributary venous occlusion and septic cavernous sinus thrombosis: CT and MR findings. *AJNR Am J Neuroradiol* 1998;19:617-26.
5. Pavlovich P, Looi A, Rootman J. Septic thrombosis of the cavernous sinus: two different mechanisms. *Orbit* 2006;25:39-43.
6. Ebricht JR, Pace MT, Niazi AF. Septic thrombosis of the cavernous sinuses. *Arch Intern Med* 2001;161:2671-6.
7. Damak M, Crassard I, Wolff V, et al. Isolated lateral sinus thrombosis: a series of 62 patients. *Stroke* 2009;40(2):476-81.
8. Desa V, Green R. Cavernous sinus thrombosis: current therapy. *J Oral Maxillofac Surg* 2012;70(9):2085-91.