

# Angiographical and histological findings in sutured and fibrin-glued microvascular anastomosis

Ayhan SAĞMANLIGİL\* Mehmet Erkan ÜSTÜN\*, Aydan CANBİLEN\*\*,  
Mustafa Cihat AVUNDUK\*\*\*, Önder GÜNEY\*, Olcay ESER\*

\* S.Ü.T.F. Nöroşirürji Anabilim Dalı, \*\* S.Ü.T.F. Histoloji ve Embriyoloji Anabilim Dalı,

\*\*\* S.Ü.T.F. Patoloji Anabilim Dalı, KONYA

## ÖZET

Bugüne kadar fibrin yapıştırıcı kullanılarak yapılmış mikrovasküler anastomozlar hakkında bir çok histolojik çalışma bulunmasına karşın sadece bir adet deneysel anjiyografik çalışmaya rastlanmıştır. Sunulan çalışmada vasküler uç uca anastomoz sonrası gelişen arterial değişimler yalnızca histolojik değil aynı zamanda anjiyografik olarak da incelenmek istenmiştir. Çalışmada 16 adet Yeni Zelanda tipi tavşan kullanıldı. Kontrol grubunda sol femoral arterler geleneksel mikrovasküler suture tekniği ile suture edilirken, sağ femoral arter %50 azaltılmış suture sayısı kullanılarak fibrin yapıştırıcı ile suture edildi. Operasyon sonrası birinci haftada anjiyografik ve histolojik inceleme yapıldı. Sol ve sağ taraf arasında anjiyografik olarak belirgin farklılık bulunmadı. İki taraf arasındaki histolojik değişiklikler de benzerdi.

**Anahtar Kelimeler:** Anjiyografi, fibrin yapıştırıcı, mikrovasküler anastomoz.

## SUMMARY

Though so far, several histological studies on fibrin-glued microvascular anastomosis have been performed. We have noticed only one experimental angiographical study. The present study was designed to investigate the short term arterial patency of vascular end to end anastomosis not only histologically but also angiographically.

Sixteen New Zealand type rabbits were used. The left femoral artery was used as a control which sutured with conventional microvascular suturing technique and the right was sutured with fibrin glue using fifty percent reduced suture number. At the first postoperative week following the angiographic examination a histologic examination was also performed. We have found no patency difference between the right and the left sides angiographically. Histological findings were similar between the two sides.

**Key Words:** Angiography, fibrin glue, microvascular anastomosis.

In surgery, there have been frequent efforts to replace sutures by tissue adhesive systems. Microvascular anastomosis became easier and quicker when fibrin glue (FG) with a reduced number of sutures was used. Many authors achieved a sufficient microanastomosis using fibrin adhesives confirmed with histological findings (1-9). The introduction of fibrin adhesion systems was vital for neurosurgery

since they do not have any neurotoxic effects, as described with other adhesives (8-10).

The present study was designed to investigate the short term patency of vascular end- to- end anastomosis angiographically and also histologically using FG with fifty percent reduced suture number

## MATERIAL AND METHOD

The FG used, consists of two components; the lyop-

Haberleşme Adresi: **M.Erkan ÜSTÜN**, S.Ü.T.F. Nöroşirürji Anabilim Dalı, KONYA

Geliş Tarihi : 01.09.2000

Yayına Kabul Tarihi : 11.01.2000



hilised fibrinogen adhesive and the lyophilised thrombin.

The fibrinogen component is dissolved with aprotinin and the thrombin component (500 UI/ ml) with calcium chloride for injection at 37°C according to the maker's instructions.

Sixteen New Zealand rabbits of both sexes, weighing 1900 - 2400 g., were anesthetized with xylazine HCl i.m. (1,5 mg. / 100 g. body weight) and ketamine HCl i.m. (3,5 mg / 100g. body weight). The femoral artery (diameter 0,9 - 1,4 mm) was exposed and mobilised for a distance of 4 cm.

In order to prevent vascular spasm, 1% xylocaine was dropped around the vessel before the dissection of the adventisia. Vascular clamps were applied proximally and distally on to the femoral artery and it was transversely transected. Then, an end- to- end anastomosis was performed under microscopic magnification by means of nylon threads 10/ 0. The left femoral artery was used as a control, sutured with the conventional microvascular suturing technique and the right was treated with FG as described below.

Five to six sutures were placed on the FG side and FG was applied by dropwise circumferential applications by using a double syringe applicator, e. g. the Duploject. This system can be operated single handed and consists of a clip for two syringes enabling a single plunger to dispense equal volumes of fibrinogen and thrombin components into a common joining piece to which a single application needle is attached. Good mixing of constituents occurs in the delivery needle. Solidification of the glue can be visualised as its colour becomes milky white when it begins to gel. We have found that, before dropping the FG, waiting a few seconds to turn its colour to milky white, prevents the glue to reach inside the vessel. After ten minutes, the clamps were removed. If significant persistent bleeding was encountered, the FG was removed and one or two additional sutures were applied to control bleeding and FG was then reapplied. Five to six sutures were adequate when combined with FG to achieve a totally hemostatic anastomosis. The surgical control anastomosis required at least twice as many sutures. The patency of the anastomosed vessels was checked visually for arterial pulsations. The operation field

was closed layer by layer postoperatively the animals were allowed for normal activity.

For angiographic examination the rabbits were anesthetized in the same manner and after a median vertical abdominal incision, aorta abdominalis was exposed. A 24 gauge angiocath was introduced into the vessel, 3 ml. contrast media (Iopamidol - Iopamiro 300) was given and Anterior - posterior (A-P) plain films were taken.

As hemodynamic alterations begin to occur at a 50% stenosis, 50% or more stenosis is essential (11). Therefore angiographic evaluation was made in three stages. Stage I: No stenosis at the anastomosis side or less than 50% stenosis. Stage II: 50% or more stenosis at the anastomosis side. Stage III: Occlusion of the anastomosis.

The stenosis was calculated as the width of the vessel at the anastomosis side / the width of the proximal side of the vessel. In figure 1 a patent anastomosis in both sides are seen. In figure 2 a stenosis more than 50% are seen. In the FG (right) side, one vessel have seen to be occluded in angiographic examination. This was our first case and as we have not wait a few seconds to allow the FG to become more viscous it reached inside the vessel. Postoperatively no arterial pulsation was seen

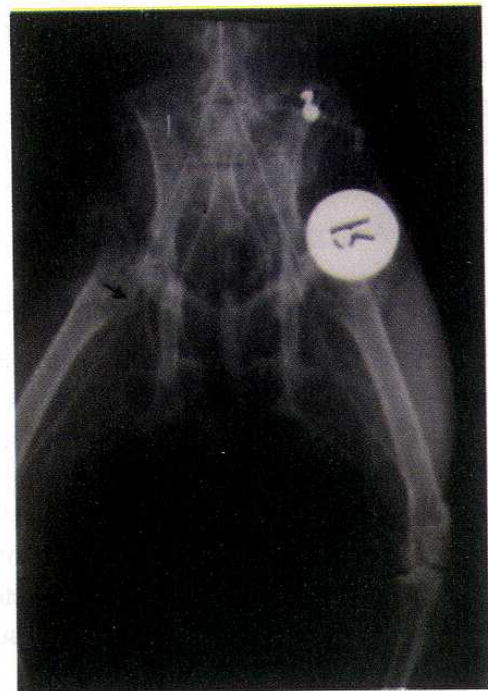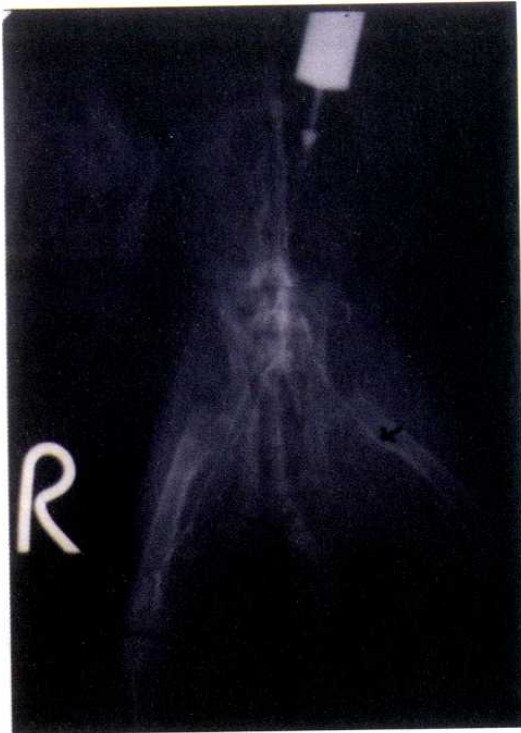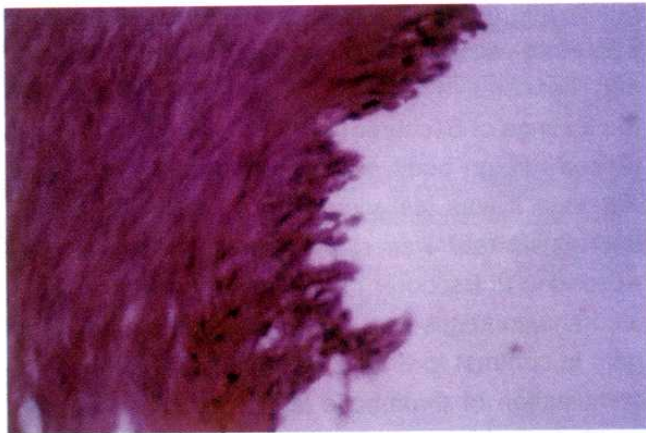


Figure 1. The patent anastomosis in both sides of vessel.





**Figure 2.** The arrow shows the stenotic anastomotic side.



**Figure 3.** The endothelial cell degeneration around the damaged areas. HE, X 100.

and in angiographic examination the occlusion was confirmed. Since it was a technical fault it was not considered for statistical analysis. The statistical analysis of the angiographic results were made according to the Fischers exact chi-square test .

After one week, when angiographic examination has been completed as described above, wounds were reopened and a 1 cm. segment of femoral artery at the site of anastomosis was removed for histologic examination.

## RESULTS

The angiographic results were shown on the table 1. We have found no statistically significant difference between the right and the left sides (Table 1).

Histological findings at the first postoperative week were similar between the two sides. Wide dis-endothelialized areas were seen. The endothelial cells present around the damaged areas were often partially detached or presented broken limits (Figure 3). Eosinophilic infiltration and foreign body giant cells appeared in the anastomoses (Figure 4, 5). Early endothelial regeneration was observed. A few blood elements and fibrin were adherent to the endothelium or to the exposed connective tissue. Thrombosis attached to the wall of the anastomosis was much more obvious where angiographically stenosis was observed (Figure 2).

## DISCUSSION

Tisseel is a tissue adhesive which consists of human fibrinogen and thrombin additive (11).Thrombin causes a hardening of the adhesive which corresponds to the physiological process (8).

The application of FG is important in the field of neurosurgery not only because it is easy to use and possesses great tensile strength, but also it exhibits no neurotoxicity like other gluing products (8,10). FG has been utilized in vascular surgery to minimize the amount of vessel trauma and foreign body reaction by decreasing the number of sutures necessary to

**Table 1.** Comparison of patency between right and left femoral arteries.

	Right Side	Left Side	Total
Stage I.	11 (73%)	15 (94%)	26 (84%)
Stage II.	4 (27%)	1 (6%)	5 (16%)

p= 0,15 (Fisher's exact chi-square test).

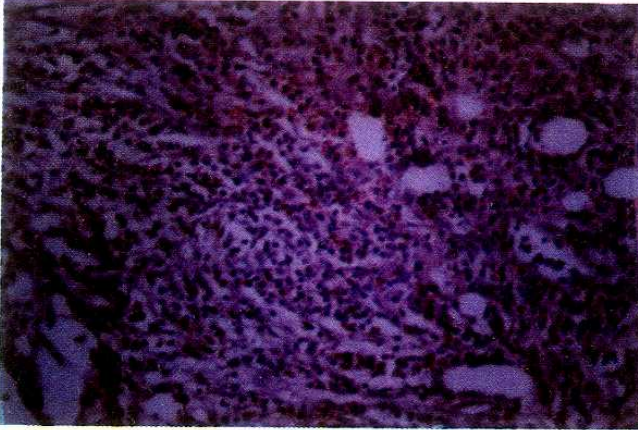
Stage I : No stenosis at the anastomosis side or less then 50% stenosis.

Stage II : 50% or more stenosis at the anastomosis side.

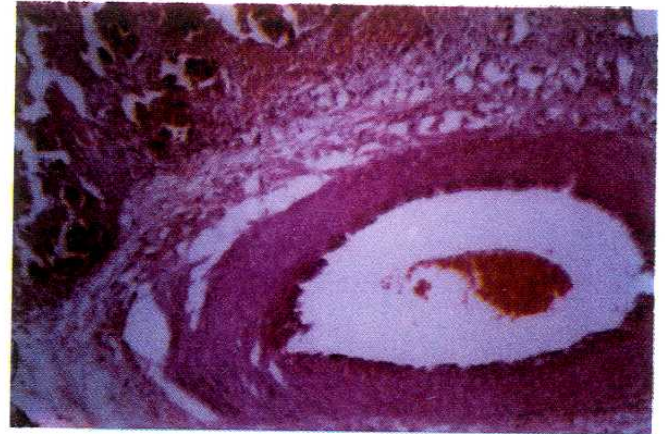Right Side : Microanastomosis with fibrin glue.

Left Side : Microanastomosis with classical technique.





**Figure 4.** The appearance eosinophilic infiltration in the anastomotic site. HE, X 100.



**Figure 5.** The foreign body giant cells in the anastomotic region. HE, X 40.

achieve a technically satisfactory arterial anastomosis and to reduce the duration of operative intervention (3,4,7,13). Using the technique of FG, we obtained a significant reduction (about % 40) of clampage time of the femoral artery.

According to Macchiarelli and co-workers (2) the structural changes occurring in the intimal layer lining the anastomotic site divided into three phases: 1) Early phase (1- 7 days) in which the degenerative phenomena of the injured endothelial cells were predominant. These phenomena were characterized by the presence of a high number of damaged endothelial cells and of large disendothelialized areas. 2) Intermediate phase (7- 30 days) in which regenerative figures were predominant. 3) Stabilization phase (60- 365 days), characterized by amelioration of the endothelial cell arrangement and structure, and persistence of the alterations of the vessel caliber.

Although the anastomotic site appeared completely covered by new endothelium after 30 to 60 days, nevertheless, endothelial cell morphology normalized only after 60 to 120 days. Furthermore, arterial wall thickening and occasional intraluminal caliber reduction were observed also after 180 to 365 days. During the first ten days postoperatively foreign-body reaction was seen (7) and up to 3 weeks after the operation lymphocytes and eosinophilic granulocytes were found in the adventitia and these participated in the reduction of the FG (1). According to Brunner (1), the inflammatory response have increased following the use of FG but Haase and

Bschorer (14, 15) have found no significant difference in the inflammatory response between sealed and non- sealed sites. According to Kletter, (8) foreign body giant cells were increased in non- sealed site.

We have done histologic examination at the first week postoperatively, so it was the end of the early phase and the beginning of the intermediate phase. Therefore we observed both disendothelialization and regenerative figures. Our results have supported the findings of Bschorer (14). We have not found increased foreign body giant cells in non- sealed site. Although it was statistically not significant, stenotic thrombosis rate was slightly higher in sealed site. According to Bschorer (14), regeneration in non- sealed anastomoses was complete at 4 days after surgery in contrast to 6 days in sealed anastomoses. A combination of thrombotic layers in sealed vessels and impaired regeneration of endothelial defects increased the occlusive thrombosis rate at 36 h after surgery. Kletter (8) have claimed that FG leads to a better physiological healing process than sutures, but Bschorer's and our findings did not support it.

Although our angiographic results were statistically similar between the two sites, late phase angiographic studies will supply more information about the stenosis and occlusion rates. Our study was the second angiographic examination in an animal experiment (16).

Caneschi and Aksik (13,17) reported good results in extracranial anastomosis with fibrin glue. In our animal experiment, the gluing of small



vessels was shown to be a reliable method. Additionally, in extracranial arterial bypass operation, FG give the chance to perform anastomoses

if such operations by suture technique seem to be difficult or when a reduction in clampage time is necessary.

## REFERENCES

1. Brunner FX. Histological findings in sutured and fibrin-glued microvascular anastomosis. *Arch Oto-Rhino-Laryngol.* 1984;8:240-311.
2. Macchiarelli G, Familiari G, Caggiati A, Magliocca FM, Riccardelli F, Miani A, et al. Arterial repair after microvascular anastomosis. *Acta Anatomica* 1991;16: 140-8.
3. Lei B, Robinson PH, Bartels HL, Wildevuur RH. Microarterial grafting into the carotid artery of the rabbit: some considerations concerning species dependent thrombogenicity. *Br J Plast Surg* 1989;64:42-59.
4. Padubidri AN, Browne E, Kononov A. Fibrin glue-assisted end-to-side anastomosis of rat femoral vessels: comparison with conventional suture method. *Ann Plast Surg* 1996;7:37- 41.
5. Isogai N, Fukunishi K, Kamiishi H. Use of fibrin glue to minimize bleeding of microvascular repairs in hypertensive rats. *Microsurg* 1992;4:321-4.
6. Ikossi-O'Connor MG, Ambrus JL, Rao U. The role of fibrin adhesive in vascular surgery. *J Surg Oncol* 1983;23: 151-2.
7. Karl P, Tilgner A, Heiner H. A new adhesive technique for microvascular anastomoses: A preliminary Report. *Br J Plast Surg* 1981;34:61-3.8. Kletter G. Fibrin adhesives in intracranial microvascular surgery. In: Schlag G, Redl H, editors. *Fibrin Sealant in Operative Medicine Ophthalmology- Neurosurgery Vol 2.* Berlin Heidelberg: Springer- Verlag; 1986: p.129-38.
9. Meyermann R, Anyai A, Kletter G, Pini C. Ultrastructural control of small vessels following microsurgical intervention by tissue adhesion with fibrin. In: Peerless SJ, McCormick CW, editors. *Microsurgery For Cerebral Ischemia.* New York :Springer Verlag; 1981: p. 190-7.
10. Brennan M. Fibrin glue. *Blood Rev* 1991;5:240- 4.
11. Zwiebel WJ. Cerebrovascular doppler applications. *Clinical applications of doppler ultrasound.* (Ed. Taylor Kenneth JW.) Raven Press. New York 1995 ; 109-31.
12. Flahiff C, Feldman D, Saltz R, Huang S. Mechanical properties of fibrin adhesives for blood vessel anastomosis. *J Biomed Mat Res* 1992;26: 481-91.
13. Caneschi S, Pirelli A, Morosi M. The use of human fibrin glue and of the suture in polyglactin 910 in extracranial by-pass. *J Neurosurg Sci* 1988;32:65- 8.
14. Bschorer R, Frerich B, Wolburg H, Gehrke G , Schwenzler N. Fibrin sealing and histometrical changes in conventionally sutured microvascular anastomoses. *J Cranio-Maxillo-Facial Surg* 1993;21:192-8.
15. Haase J, Falk E, Massen FF, Teglbjerg PS. Experimental and clinical use of tisseel (tissucol) and muscle to reinforce rat arteries and human cerebral saccular aneurysms. In: Schlag G, Redl H, editors. *Fibrin Sealant in Operative Medicine Ophthalmology- Neurosurgery Vol 2.* Berlin Heidelberg: Springer-Verlag;1986:p.172-5.
16. Sugiura K, Nakatsuchi Y, Yagi R, Sugimoto Y. A new method for venous interposition grafts using fibrin glue. *Microsurg* 1985;6(2):125-8
17. Aksik IA, Kikut RP, Apshkalne DL. Extracranial anastomosis performed by means of biological gluing materials: experimental and clinical study. *Microsurg* 1986;7: 2-8.