

End-to-side neurorrhaphy as a salvage procedure for irreparable nerve injuries: the results of three cases with review of the pertinent literature

Tunç Cevat ÖĞÜN, Mehmet ARAZİ, M.İ.Safa KAPICIOĞLU, Recep MEMİK

S.Ü.T.F. Ortopedi ve Travmatoloji Anabilim Dalı, KONYA

ÖZET

Amaç: Uç-yan sinir anastomozu ile ilgili ilk çalışmalar geçtiğimiz yüzyılın başında bildirilmiş, ancak daha sonra bir kenara bırakılan bu teknik, yakınlarda Viterbo ile tekrar gündeme kazandırılmıştır. Bu çalışmada, uç-yan sinir anastomozu yaptığımız üç vakaya ait sonuçları inceledik. **Metod:** Median sinir yaralanması nedeniyle 15-22 cm arasında sinir kaybı olan üç hastaya epinöral pencere açılarak uç-yan sinir anastomozu yapıldı. Takip süreleri 12 ve 18 ay arasında idi. Duyu muayenesi için hafif dokunma, yüzeysel ağrı ve iki nokta ayırımı testleri kullanıldı. Motor değerlendirme oppozisyona bakılarak ve abdüktör pollisis brevis kası palpe edilerek yapıldı. **Bulgular:** Tüm hastalarda median sinir dermatomunda duyu iyileşmesi olduğu gözlemlendi. Ancak, üçüncü vakada parmak uçlarında tam değildi. Motor iyileşme hiçbir hastada olmadı. Oppozisyon yapabilen üçüncü vakada bu bulgu ameliyat öncesinde de vardı. **Sonuç:** Uç-yan sinir anastomozu, sinir dokusunda uzun kayıpların olduğu vakalarda iyi bir alternatif tedavi yöntemi olabilir.

Anahtar Kelimeler: Median sinir, ulnar sinir, uç-yan onarım

SUMMARY

Purpose: After a few reports on end-to-side nerve repair at the beginning of this century, the technique was put aside until it has recently been reintroduced by Viterbo. We herein present the results of three cases treated by end-to-side median-to-ulnar neurorrhaphy. **Methods:** Three patients with median nerve defects between 15 and 22cm were treated by end-to-side nerve repair, through an epineurial window. The follow-up times were between 12 and 18 months. Sensory evaluation involved superficial touch, pin-prick, and two point discrimination tests. Motor evaluation was done by assessing the presence of opposition, and palpating the abductor pollicis brevis. **Results:** Sensory recovery was observed in all the patients, in the median nerve dermatome. In case-3 it was incomplete at the tips of his fingers. Motor recovery was absent, except in case-1, who could perform opposition before the operation, as well. **Conclusions:** End-to-side nerve repair is a viable alternative in cases with long gaps between the ends of the injured nerve.

Key Words: median nerve, ulnar nerve, repair, end-to-side

The concept of end-to-side nerve repair was initially introduced by Ballance et al.(1) at the turn of the century. Recently, Viterbo et al.(2) have reintroduced the procedure. The purpose of the technique is to use a donor nerve without sacrificing the

supply to its innervation area. It is suggested that the distal portion of an injured nerve regenerates after it is sutured to the side of an intact nerve.

Median or ulnar nerve injury with a long gap is very difficult to manage. Nerve grafts and conduits

Haberleşme Adresi: Yrd. Doç. Dr. Tunç Cevat ÖĞÜN, S.Ü.T.F. Ortopedi ve Travmatoloji Anabilim Dalı, KONYA

Geliş Tarihi : 02.02.2001

Yayına Kabul Tarihi : 17.05.2001

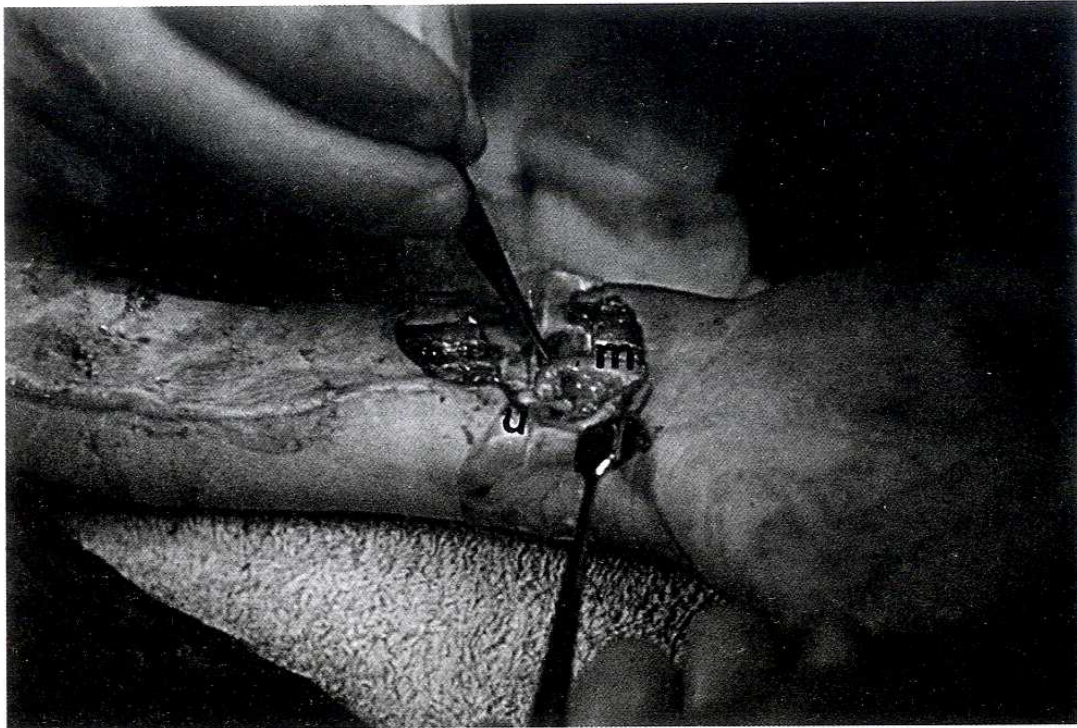


Figure 1. The end-to-side median-to-ulnar nerve repair, in Case-1. m, median nerve. u, ulnar nerve.

fail to provide regeneration when used for gaps longer than 6cm. Vascularized nerve grafts also do not yield reproducible results in long nerve gaps. End-to-side nerve repair may provide a viable solution for these difficult cases.

We present here the results of end-to-side nerve repairs in three patients with irreparable median nerve injuries.

PATIENTS AND RESULTS

Three patients with long defects in the median nerve were treated by end-to-side median to ulnar nerve repair after discussing the reconstructive options, with the patients and their families. Specific local ethical committee approval was sought and granted to perform the procedure. Following the operations three weeks of plaster splint immobilization was applied in all the patients, after which a rehabilitation programme was started. The patients were recalled for a final evaluation. Sensory assesment involved superficial touch with a cotton wool, pinprick and two point discrimination tests. Opposition of the thumb and feeling the contraction of the thenar muscles were assessed to determine motor activity. ENMG was done in all the patients.

Case-1: An 11 year old girl presented with skin and soft tissue loss together with a fracture of her right

radius after a traffic accident in which her forearm was caught between the ground and the wheel of a truck. On examination in the operating room, she had a large skin loss on the volar side of her right forearm. Superficial flexors were badly injured. The proximal part of the median nerve was found a few cm proximal to the elbow, and the distal part 5cm proximal to the wrist, revealing a gap of 16 cm. The ulnar nerve was intact. Intramedullary pin fixation of the radius and soft tissue debridement were performed, and a posterior plaster splint was applied. Following a few days of wound-care and antibiotic prophylaxis, the skin defect was covered with a split thickness graft. Four months later, the median nerve dermatome was completely anesthetic and there were skin lesions in the first and second fingers resulting from thermal burn, however opposition was present. End-to-side nerve reconstruction was planned. At the operation the distal stump of the median nerve was mobilized and coapted to the side of the ulnar nerve through an epineurial window(Fig.1). In addition, deep flexors of the second and third fingers were sutured side-to-side to the deep flexors of the fourth and fifth fingers, and the brachioradialis was transferred to the long flexor of the thumb. After three weeks of immobilization in a short arm plaster

splint, hand rehabilitation was begun. At fourteen months postoperatively, she was able to perceive superficial touch and pin-prick in the pulps of her thumb and the second and third fingers. Her cooperation was not good to perform the two point discrimination test. ENG revealed a conduction velocity from the median nerve dermatome close to that depicted from the ulnar nerve dermatome. The function of the fingers was reasonably well after the transfers (Fig.2a,b).

to his right mid-forearm with a rolling and cutting machine. He was operated on an emergency basis under supraclavicular block anesthesia, and all the flexor tendons of the fingers excluding the fourth and fifth fingers and the long thumb flexor were found to be cut to the radius. The median nerve was avulsed producing a gap of 15cm between its ends. The patient and his family were informed as to the type of the surgical procedure, and primary end-to-side suture of the median nerve to the intact ulnar nerve

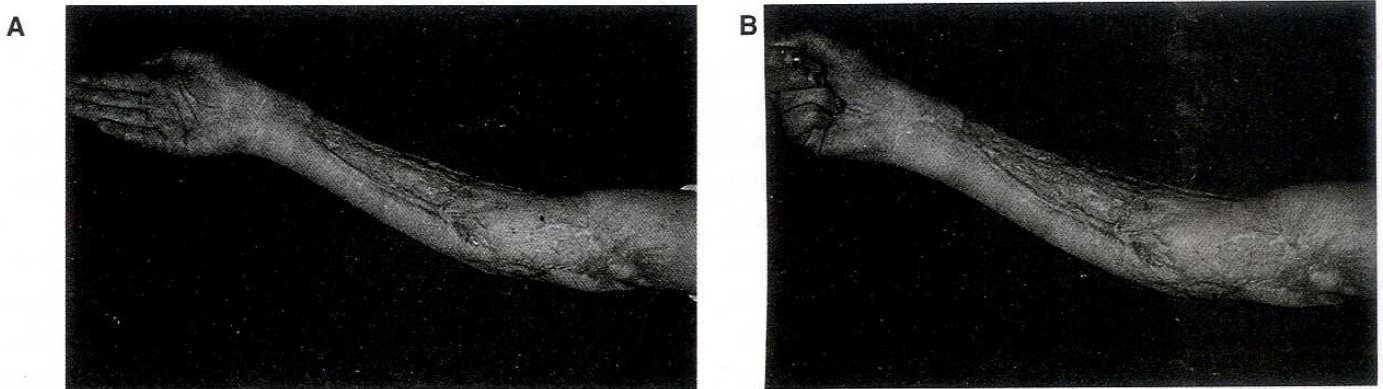


Figure 2. The same patient at fourteen months postoperatively, showing the function of the fingers, after tendon transfers.

Case-2: A fifteen year old boy sustained an injury to his right volar forearm with some kind of a rolling machine. Upon exploration the mobile-wad and the radial part of the flexor group of muscles were badly injured. The median nerve was defective, and its ends were found in the mid-arm region and in the mid-forearm, producing a gap of 22 cm, probably resulting from an avulsion injury. Three months after the primary debridement and repair and reconstruction of the muscles, the distal median nerve was sutured to the side of the ulnar nerve after excising 3cm of its fibrotic part, using an epineurial window. At eighteen months postoperatively, he was able to feel superficial touch and pain. Two point discrimination could not be done, but was felt as a single point. Opposition was absent and an opponensplasty using the extensor indicis proprius was performed. ENMG showed no motor unit potentials, and absence of voluntary contraction. Sensory potentials were present, although the conduction time was prolonged.

Case-3: A nineteen year old boy sustained an injury

was performed through an epineurial window, together with the flexor tendon repair. The skin closure was also done primarily. At the end of the postoperative 12 months, he was able to perceive superficial touch and pin-prick in the median nerve dermatome except in the distal phalanges of the first, second and third fingers. Two point discrimination was not successful. Opposition was absent and reconstructed later using the extensor indicis proprius tendon. ENMG showed prolonged sensory conduction time, but the sensory potentials were present. No motor potentials, and voluntary contractions could be obtained.

DISCUSSION

In 1903, Ballance (1) reported a case in which he sutured the distal end of the sectioned facial nerve to the side of the intact accessory spinal nerve. The patient had eventually, movement of the face together with the movement of the shoulder, and there was no deficiency in the function of the accessory nerve. Recently, the works by especially Viterbo et al. (2,3) and others (4-9) have opened opportunities

for the use of end-to-side neurorrhaphy, as they demonstrated successful axonal regeneration following experimental end-to-side coaptation in almost every case. On the other hand, a few other authors have reported studies with conflicting results (10,11).

The type of coaptation of the end of a sectioned nerve to the side of the donor nerve has been questioned widely with regard to the mechanism of axonal sprouting. The anastomosis may be done directly to the epineurial sheath or, through an epineurial or perineurial window. The perineurial way is accused of being an end-to-end technique indeed, since many endoneurial tubes can be sectioned in this way. Viterbo et al.(2) proposed that the absence of an incision on the axons of the donor nerve was no impediment to axonal regeneration by comparing the results of end-to-side neurorrhaphy with and without epiperineurium in an experimental study, and concluded that either type of neurorrhaphy led to the same morphology and electrophysiology. In contrast, Al-Qattan's et al.(4) reported a statistically significant difference between the epineurial and perineurial suture techniques. In their study the epineurial suture group showed no evidence of regenerating axons, but in the perineurial suture group there were thinly myelinated regenerating axons, the origin of which was attributed to injury from the perineurial sutures. In this study, one end of the fresh autogenous nerve grafts were sutured to the recipient nerve, so, there was perhaps a lack of neurotrophic and neurotropic factors from the distal end organ which have also been proposed to play a role in axonal sprouting. In another part of the study they tried to produce regeneration in silicone tubes, sutured to the epineurium or perineurium of the side of an intact nerve, but, no evidence of regeneration was obtained in any of the groups as a result.

Lundborg et al.(7) also stated that the rate of axonal regeneration was higher in the perineurial suture group owing to the injury to the parent nerve that is more likely to occur after perineurial sutures. However, the same injury was not sufficient to produce collateral sprouting using silicone tubes in Al-Qattan's study, that could be explained by the absence of Schwann cells in the transplanted silicone tubes. These cells synthesize nerve growth factors that are supposed to play a role in the induction of

collateral sprouting from the parent nerve. Lundborg et al.(7) explored the role of Schwann cells on the rate of axonal regeneration by using nerve grafts. Nerve grafts undergoing Wallerian degeneration showed a higher rate of regeneration than the fresh grafts, after end-to-side anastomosis. This was explained by the presence of more Schwann cells in degenerating nerve grafts.

In the study of Tarasidis et al.(9), retrograde nerve staining revealed minimal staining of motor neurons, however sensory neural regeneration occurred in an end-to-side neurorrhaphy at the end of 16 weeks. On the other hand, Lundborg et al.(7) obtained regeneration in both sensory and motor neurons, but sensory neurons regenerated better through a predegenerated nerve than across a fresh nerve graft in the no-window group.

Casella et al.(6) compared direct end-to-side repair with an end-to-side repair of an interposing nerve graft using the rat sciatic nerve model. Neural regeneration was reported to be equally satisfactory in both groups.

In Ross et al.'s study(8) using a rabbit model, a comparison was made between a cut-and-repair of the musculocutaneous branch of the median nerve, and experimental groups in which the cut musculocutaneous nerve was attached to the side of the median nerve in an end-to-side fashion. Half of the animals underwent immediate repair, and the other half had a delay of 4 weeks prior to coaptation. Subsequent reinnervation of the denervated muscle was comparable to the nerve function of the control. No difference was seen between the two experimental groups.

The electron microscopic findings support the studies mentioned above, and indicate that nerve regeneration following end-to-side repair is structurally similar to the repair process following end-to-end neurorrhaphy(4).

Viterbo(3) carried his work to the clinical arena by using the technique for cross-face nerve transplantation for facial reanimation and for brachial plexus reconstruction. Results were promising in only one patient, and follow-up was early for evaluation of the five patients reported. Kostakoğlu (12), is probably the first to report on the end-to-side nerve repair in the field of hand surgery. After a two year fol-

low-up of median-to-ulnar nerve end-to-side nerve repair in a patient with a 35 cm fibrosis of the median nerve, resulting from an attempt of suicide by injecting commercial thinner, he reported sensory recovery in the form of diminished protective sensation in the large part of the median nerve dermatome. Opposition of the thumb was weakly possible, which was augmented by an opponensplasty.

In our patients, there was a common presumably positive prognostic factor of young age. We used epineurial windows in all of them, but the sutures were through the walls of the epineurium, and did not include perineurium. The return of sensory function was satisfactory, after at least a year post-operatively. Incomplete sensory recovery in the third case may be attributed to the relatively higher age of the patient or, the shorter period of follow-up or, in relation with Lundborg's observation, primary anastomosis done before Wallerian degeneration hampering the effect of Schwann cells. Whether it will get better is a matter of time. The absence of motor recovery is somewhat discouraging, but the number of patients is small, and to make a comment requires large series, comparing the proposed different techniques of end-to-side anastomosis. Only the first case had opposition of the thumb, which was probably the result of ulnar innervated abductor

pollicis brevis. One additional interesting observation was that none of the patients complained of cold intolerance which is common after nerve repair. Thus, our results correlate well with the experimental studies concerning this type of nerve repair, especially with the ones claiming better sensory recovery. This technique provides the easiest way of returning sensory function to the hand which is the primary aim in median nerve injuries.

Although, Viterbo(2) reported that the gastrocnemii muscles were not altered after using the tibial nerve as a donor for the sectioned peroneal nerve, and other studies claim the same opinion, the possibility of loss of function in the donor nerve has not been demonstrated in detail. Whether regenerating axons represent true collateral sprouts or regenerated axon tips of fibres which were damaged during the attachment of the nerve graft also remains to be answered.

Frequently a reliable, expendable or adequate source of sensory or motor nerve tissue is not available after serious nerve injury. The end-to-side neurorraphy is an option for these cases where only the distal end is available. In addition, there is a wide range of choices for the donor nerve, as it is not sacrificed. Repair with vascularized nerve grafts still remains as an option if the procedure fails.

REFERENCES

1. Ballance CA, Ballance HA, Stewart P. Remarks on the operative treatment of chronic facial palsy of peripheral origin. *BMJ* 1903; 2:1009-1013.
2. Viterbo F, Trindade JC, Hoshino K, Neto AM. End-to-side neurorraphy with removal of the epineurial sheath: an experimental study in rats. *Plast Reconstr Surg* 1994; 94:1038-1047.
3. Viterbo F, Franciosi LF, Palhares A. Nerve graftings and end-to-side neurorraphies connecting the phrenic nerve to the brachial plexus. *Plast Reconstr Surg* 1995; 96:494-495.
4. Al-Qattan MM, Al-Thunyan A. Variables affecting axonal regeneration following end-to-side neurorraphy. *Br J Plast Surg* 1998; 51:238-242.
5. Battal MN, Hata Y. A review on the history of end-to-side neurorraphy. *Plast Reconstr Surg* 1997; 99:2110-2111.
6. Casella GTB, Sagggers GC, Manders EK, Gemperli R, Olson DJ. End-to-side peripheral nerve repair in the rat results in reinnervation by axonal sprouting. *J Reconstr Microsurg* 1997; 13:378-386.
7. Lundborg G, Zhao Q, Kanje M, Danielsen N, Kerns JM. Can sensory and motor collateral sprouting be induced from intact peripheral nerve by end-to-side anastomosis? *J Hand Surg* 1994; 19B:277-282.
8. Ross D, Zuker RM, Matsuda H. End-to-side nerve coaptation for muscle reinnervation. *J Reconstr Microsurg* 1995; 11:373-378.
9. Tarasidis G, Watanabe O, Mackinnon SE, Strasberg SR, Haughey BH, Hunter DA. End-to-side neurorraphy resulting in limited sensory axonal regeneration in a rat model. *Ann Otol Rhinol Laryngol* 1994; 106:506-512.
10. Kalliainen LK, Kuzon WM. Reinnervating skeletal muscle using terminolateral neurorraphy. *Can J Plast Surg* 1996; 4:25-30.
11. Shah MH, Kasabian AK, Karp NS, Kolker AR, Rublin BA, Zhang L, Sakuma J. Axonal regeneration through an autogeneous nerve bypass: an experimental study in the rat. *Ann Plast Surg* 1997; 38:408-415.
12. Kostakoğlu N. Motor and sensory reinnervation in the hand after an end-to-side median to ulnar nerve coaptation in the forearm. *Br J Plast Surg* 1999; 52:404-407.