

PULMONARY ALVEOLAR MICROLITHIASIS WITH PECTUS EXCAVATUM

Cevat ÖZPINAR M.D.*, Sami CERAN M.D.*, Mehmet YENİTERZİ M.D.*, Tahir YÜKSEK M.D.*

Güven Sadi SUNAM M.D.*, Mehmet GÖK M.D.** , Sadık ÖZMEN M.D.***

Hasan SOLAK M.D., F.C.C.P., F.I.C.A.*

* The Department of Thoracic and Cardiovascular Surgery, Faculty of Medicine, University of Selçuk

** The Department of Cardiology, Faculty of Medicine, University of Selçuk

*** The Department of Anesthesiology, Faculty of Medicine, University of Selçuk

ÖZET

Pectus Excavatumun Eşlik Ettiği Pulmoner Alveolar Mikrolithiasis

Pulmoner alveolar mikrolithiasis, etiolojisi bilinmeyen ve nadir olarak görülen bir hastalıktır. Alveoller içinde sayısız, toplu iğne başı büyüklüğünde kalsifikasyonlar mevcuttur. Dünya literatüründe 100'den daha az sayıda bildirilmiş olan nadir bir vaka grubudur. Bizim vakamızda pectus excavatumun da bulunuşu vakayı daha ilginç hale getirmiştir.

Anahtar Kelimeler : Pulmoner alveolar mikrolithiasis

SUMMARY

Pulmonary alveolar microlithiasis is a disease of unknown etiology and encountered infrequently. There is a formation of calcific bodies within the alveoli. The X-ray shows extensive infiltration of both lungs. So far less than 100 cases were reported. However, we are unaware of a case with pectus excavatum. In this report we discuss a case of pulmonary alveolar microlithiasis with pectus excavatum, and its treatment and medical intervention.

Key Words : Pulmonary alveolar microlithiasis

INTRODUCTION

Pulmonary alveolar microlithiasis is a rarely seen disease of unknown etiology. There is a formation of numerous small calcific bodies within the alveoli. There is no determined difference between the man and the woman. There is a formation of very tiny peripheral opacities in the lung radiograms.

CASE REPORT

A woman patient, 20 years of age with a peculiar diffuse bilateral calcific densities in her chest x-ray film had been recognized during routine field health screen in the rural areas.

Patient did not have a noticeable history of tuberculosis and lung infection. During screening, dense areas in the lung was noticed and the patient

was sent to our clinic. In the family anamnesis only her grandfather was told to have tuberculosis. On admission, she was asymptomatic. She had noticeable pectus excavatum and a hearing loss in the right ear. The laboratory findings were normal. Pulmonary function tests revealed somewhat medium vital capacity.

A posteroanterior chest radiograph revealed bilateral diffuse opacities existing throughout both lung fields (Fig. 1). Computerized Tomography of thorax showed the pectus excavatum related deformity. Widespread sand-like opacities markedly increased in the middle and lower zones of both lung fields presenting reticulonodular appearance. The fine bands of calcifications were evident in pleura and fissures (Fig. 2). Figure 2 also showed in

Correspondance : Y. Doç. Dr. Cevat ÖZPINAR S.Ü.T.F. Göğüs Kalp ve Damar Cerrahisi Anabilim Dalı, Konya

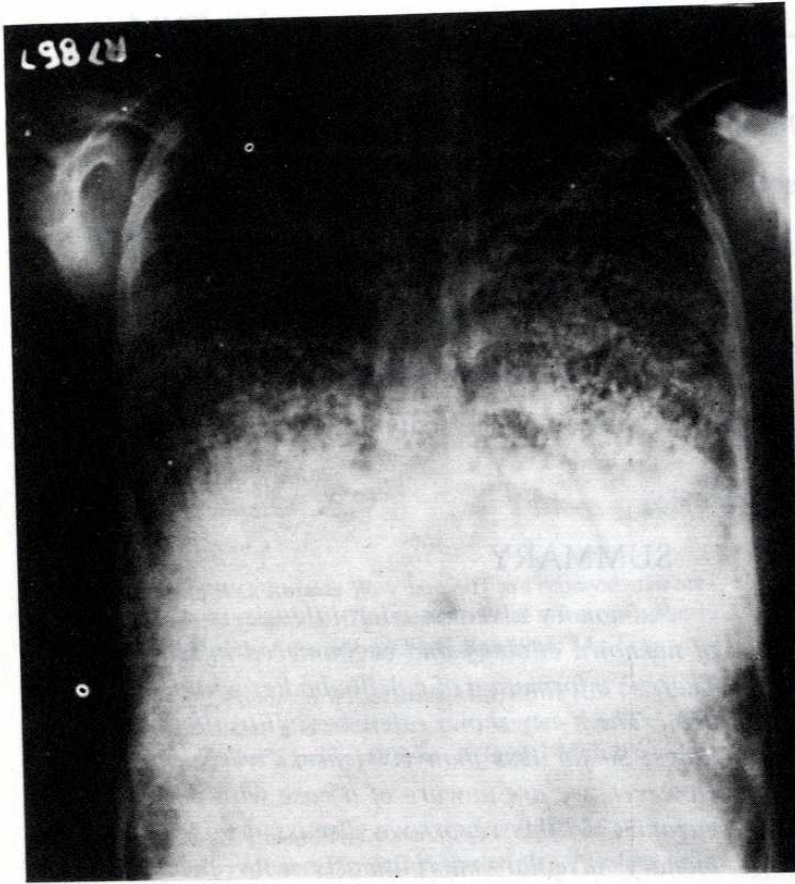


Figure 1. The posteroanterior chest graphy of the patient with pulmonary alveolar microlithiasis.

terstitial fibrosis and widespread calcification of parenchymal peribroncovasculars.

The disease was diagnosed with the lung biopsy. The definite diagnosis had been seen by means of with the lung biopsy. In crosscats disappearance of alveol walls in large areas and lumens holding of amorphu basophyle corpora amileseas containing was determined and the definite diagnosis had been reported as pulmonary alveolar microlithiasis (Fig. 3).

Since the patient's pectus excavatum had extremely effected her psychologically, she was taken for the pectus excavatum treatment and she was dicharged from the hospital her pectus excavatum successfully treated without any postoperative complication.

DISCUSSION

Pulmonary alveolar microlithiasis is a rarely seen disease of unknown etiology. There is a formation of numerous small calcific bodies within the alveoli. The dimensions of calcium crystal change from 0.01 mm to 0.3 mm (1,2). There is no difference observed between man and woman (3).

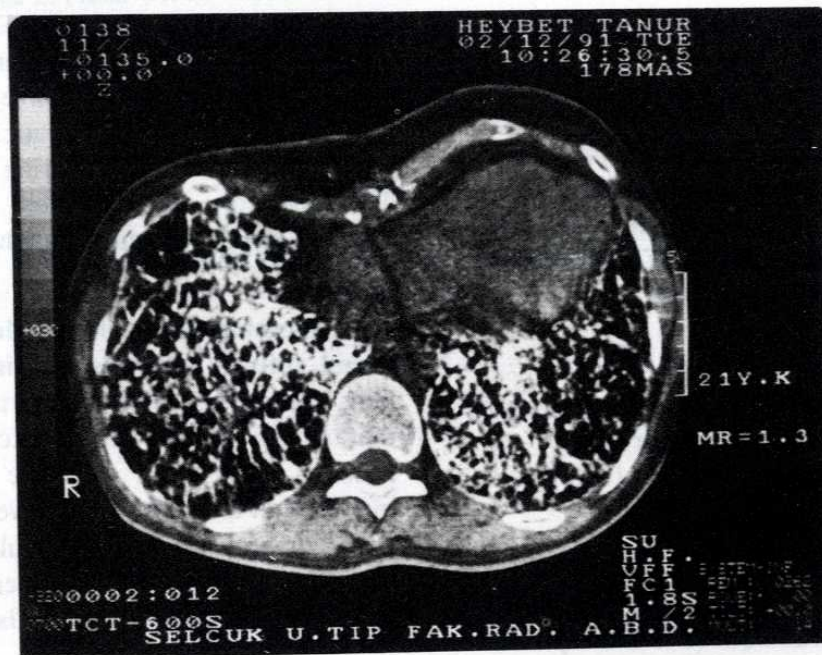


Figure 2. The thorax CT of the patient

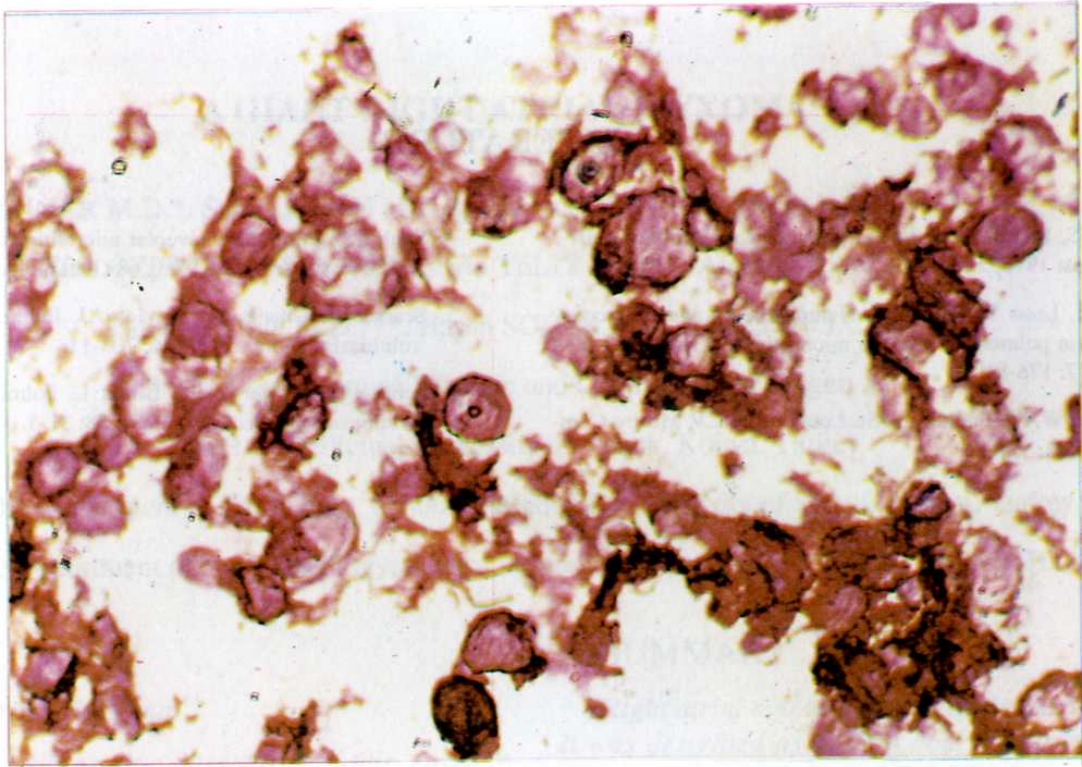


Figure 3. Microscopic view of the lung biopsy material of the patient

The moving of the disease in a course, from the point of structure seen in the lung and alveoli in early period has gone into fibrosis with the progress of the illness and list into a heavy cor-pulmonale. It has been estimated that the weight of the lungs has reached as much four times again. The major part of the lungs were filled with calcific bodies. The average weight was 2-4 kg (3).

There was a formation of very tiny periferic opacities in the lung radiograms. This observation was defined by Friederich (1856), has been accepted as the most determinative figure. Pulmonary alveolar microlithiasis patients may not show any symptoms despite the radiologic changes. But there are evidences that the disease starts during the early period of the life.

In progressed cases, gradual increase showing exercise dyspnea, cyanosis, polycythemia, mucus expectoration grow together with a slight cough. Sometimes clubbing in the fingers and hemoptysis are observed rarely. At last death is inevitable because of lavk of respiratory failure and cardiac insufficiency.

In most cases the disease is likely to progress. Sometimes it can pause. It can remain like this without any clinic change. The characteristic radiological appearance of pulmonary alveolar microlithiasis is like two sided sand-like in the form of micronodule

calcific density (4).

In some cases the illness can not be recognized for many years and in most cases it is recognized with an autopsy.

In most cases milliary tuberculosis, silicosis, sarcoidosis, hemosiderosis, mycotic infections, lipid embolism and cancer must be thought as differential diagnosis.

In more than half of the cases reported the first recognition has become miliary tuberculosis.

It has been observed that the vital capacity has decreased below 50 % with a slight effort. The interrelation between decreased vital capacity and interstitial lung illness has decreased both the parenchymal and vascular capacity in high degree. Moreover an increase has been determined in the polmonary arterial pressure. In all cases respiratory functions have been effected in negative way and the vital capacity has decreased below % 80 (5,6).

The definite diagnosis of our patient has been proved in result of lung biopsy under the lightening of clinical and radiological.

Providing that pulmonary alveolar microlithiasis cases have been so rare according to the literature. We thought it would be suitable to publish such a case.

LITERATURE

1. Thind GS, Bhatia JL. Pulmonary alveolar microlithiasis. *Br J Dis Chest* 1978; 72: 151-3.
2. Brown J, Leon W, Felton C. Hemodynamic and pulmonary studies in pulmonary alveolar microlithiasis. *The Am J Med* 1984; 77: 176-81.
3. Anderson WAD. Pathology. St. Louis : The CV Mosby Company, 1971: 921-2.
4. Nouh MS. Pulmonary alveolar microlithiasis : a report on four cases. *East Afr Med J* 1991; 68 (1) : 39-42.
5. Sears MR, Chang AR, Taylor AJ. Pulmonary alveolar microlithiasis. *Thorax* 1971; 26: 704-11.
6. Lebacoz E, Lauwerygns J, Billiet L. Pulmonary alveolar microlithiasis *Br J Dis Chest* 1964; 58: 31-5.