

## SUPRAVALVULAR AORTIC STENOSIS WITHOUT WILLIAMS SYNDROME

Cevat ÖZPINAR M.D.\*, Sami CERAN M.D.\*, Mehmet YENİTERZİ M.D.\*, Tahir YÜKSEK M.D.\*

Ufuk ÖZERGİN M.D.\*, Ali BAYRAM M.D.\*\*\*, Hasan GÖK M.D.\*\*\*, Sadık ÖZMEN M.D.\*\*\*

Ahmet SALBACAK PhD\*\*\*\*, Hasan SOLAK M.D. F.C.C.P., F.I.C.A.\*

\* The Department of Thoracic and Cardiovascular Surgery, Faculty of Medicine, University of Selçuk, Konya

\*\* The Department of Cardiology, Faculty of Medicine, University of Selçuk, Konya

\*\*\* The Department of Anesthesiology, Faculty of Medicine, University of Selçuk, Konya

\*\*\*\* The Department of Morphology, Faculty of Medicine, University of Selçuk, Konya

### ÖZET

#### *Williams Sendromsuz Supravalyüler Aort Darlığı*

*Bu makalede supravalyüler aort darlığı mevcut olan bir hasta sunuldu. Tanı konduğunda hasta 30 yaşındaydı ve klinik bulguları Williams Sendromu'na uymuyordu. Bu vaka dolayısıyla, nadir görülen supravalyüler aort darlıkları tartışıldı ve Williams Sendromu'ndan ayrı olarak da bulunabilecekleri vurgulandı.*

*Anahtar Kelimeler : Williams sendromu, supravalyüler aort darlığı*

### SUMMARY

*In this article, a patient with supravalyüler aortic stenosis is reported. She was thirty years old when her illness was diagnosed. Her clinical picture was completely different from Williams syndrome. Since supravalyüler aortic stenosis were rarely seen, the cases were discussed involving the subject and it was suggested that supravalyüler aortic stenosis might be present without Williams syndrome.*

*Key Words : Williams' syndrome, supravalyüler aortic stenosis*

### INTRODUCTION

Supravalyüler aortic stenosis is a congenital narrowing of the descending aorta, originating at the superior margin of the sinuses of Valsalva just above the levels of the coronary arteries. This anomaly was agreed to be as a coarctation of the ascending aorta. The clinical picture of supravalyüler obstruction usually differs in major respects from that observed in the other forms of aortic stenosis. Mainly among the differences is the association of supravalyüler aortic stenosis with idiopathic infantile hypercalcemia, a disease that may be related to deranged vitamin D metabolism (1,2).

### CASE REPORT

A thirty years old woman was admitted to the hospital with the complains of tachycardia, thoracic pain and dyspnea. Her complains had been present for one year. There was no history of any previous illness except that appendectomy in 1986, and she had given three births. In the family anamnesis, one of her parents had died from heart failure and other has same illness. Her three brothers and two sisters were reported to be healthy.

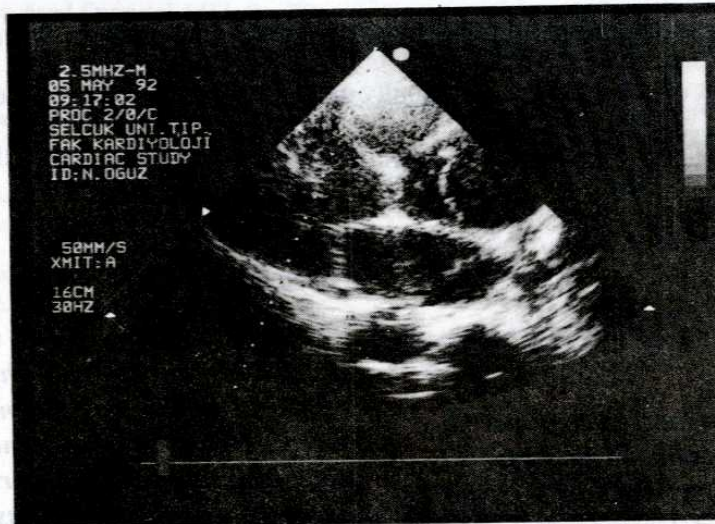
On physical examination, her mental status was normal and she has no elfin facies. There was a grade 3/6 systolic murmur best heard in the second

*Correspondance : Y. Doç. Dr. Cevat ÖZPINAR, S.Ü.T.F. Göğüs Kalp ve Damar Cerrahisi Kliniği, Konya*



intercostal space at the right border of sternum and early diastolic, decrescendo murmur best heard at the apex. The blood pressures measured on both arms were 120/70 mm Hg. with a heart rate of 76/min. A posteroanterior chest radiography revealed both left ventricle and ascending aorta enlargements.

The electrocardiogram showed left axis deviation and left ventricular hypertrophy. In echocardiogram, (Picture 1) an aortic membran originating at the superior margin of the sinuses of Valsalva was recognised. Its systolic pressure gradient was calculated as 64 mm Hg. In addition, a second degree



Picture 1 : Supralvalvular aortic membran seen in echocardiography

of aortic insufficiency was present, left ventricle performance was normal although it was dilated (left ventricle enddiastolic diameter was 63 mm). Aortic maximal velocity was 3.9 m/sec. The laboratory findings were in normal limits.

In surgical exploration, the membran was adhere to aortic wall just above the sinuses of Valsalva of the right and the left coronary cusps comissures (Figure 1). It was stretching toward the posterior wall of the ascending aorta, below the root of the innominate artery. The left coronary artery was leaving from just below the membran. Interestingly, the right one was leaving just above it, and there was a small, secondary opening on the membran here. A small patch of the membran remained under the crossclamp although it was placed more superior than normal level. After the membran had been excised, this patch was sutured on the aortic wall to prevent developing a poche. Since the ascending aorta dilated, plication of aorta was added to procedure.

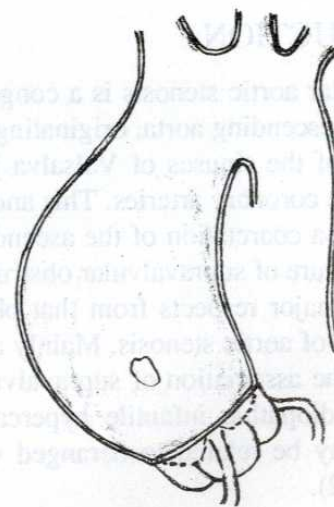
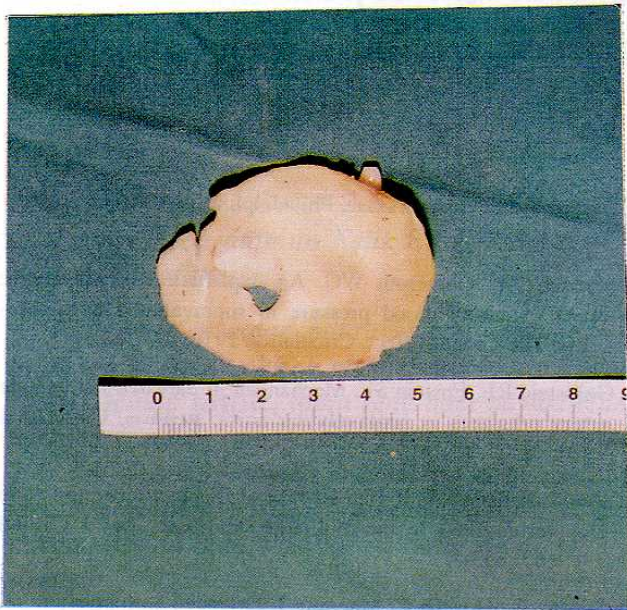


Figure 1. Supralvalvular aortic membran and dilated descending aorta



The excised membran (Picture 2) was 57x43 mm (19.24 cm<sup>2</sup>) and its central opening was 6x10 mm (0.47 cm<sup>2</sup>). Histologic structure of the membran was defined as endothelial and fibrous tissue by the Department of Pathology.

The patient was discharged 11th days after operation without any complication.



Picture 2. Superior view of the excised membran

## DISCUSSION

Most patients with supravalvular aortic stenosis syndrome are mentally retarded and resemble one another in their facial features. The typical appearance is similar to that of the elfin facies observed in the severe form of idiopathic infantile hypercalcemia and is characterized by a high prominent forehead, epicanthal folds, underdeveloped bridge of the nose and mandible, overhanging upper lip, strabismus, and abnormalities of dental development. Additional manifestations of this syndrome include auditory hyperacusis, narrowing of peripheral systemic and pulmonary arteries and inguinal hernia (3,4).

In some patients, moderate thickening of the aortic cusps and valvular pulmonary stenosis may occur in association with peripheral pulmonary artery stenosis, however, in familial and sporadic forms unassociated with the other features of the

syndrome (5). Rarely, patients have mitral valve abnormalities with prolapse and mitral regurgitation. Patients with supravalvular aortic obstruction appear to be subject of the same risk of unexpected sudden death and infective endocarditis as those with valvular aortic stenosis.

Genetic studies suggest that the familial anomaly is transmitted as an autosomal dominant with variable expression (6).

Three anatomical types of supravalvular aortic stenosis are recognized, although some patients may have findings more than one type. Most common is the hourglass type, in which marked thickening and disorganization of the aortic media produce a constricting annular ridge at the superior margin of the sinuses of Valsalva. The membranous type is the result of fibrous and fibromuscular semicircular diaphragma with a central opening stretched across the lumen of the aorta. Uniform hypoplasia of the ascending aorta characterizes the hypoplastic type.

In these patients, aortic valve closure are accentuated due to elevated pressure in the aorta proximal to the stenosis, an infrequent systolic ejection sound and the especially prominent transmission of a thrill and murmur into the jugular notch and along the carotid vessels. The narrowing of the peripheral pulmonary arteries that often coexists in these patients frequently produces a late systolic or continuous murmur that may help to distinguish this anomaly from valvular aortic stenosis. The systolic pressure in the right arm tends to be higher of the two and occasionally exceeds that in the femoral arteries. The disparity in pulses may relate to the tendency of a jet stream to adherence to a vessel wall (Coanda effect) and selective streaming of blood into the innominate artery (7,8).

Electrocardiography usually reveals left ventricular hypertrophy when obstruction is severe. Radiographically, in contrast to valvular and discrete subvalvular aortic stenosis, poststenotic dilatation of the ascending aorta seldom is seen. Echocardiography is the most valuable technique for localizing the site of obstruction to the supravalvular area and Doppler examination and retrograde aortic catheterization can determine of hemodynamic abnormalities (9).



Operation may be recommended when relatively little hypoplasia of the ascending aorta, and when the obstruction is discrete and significant, i.e., with a systolic gradient exceeds 50 mm Hg. The supra-avalvular aortic lumen may be widened by the insertion of an oval or diamond-shaped fabric patch in those patients. Stewart and colleagues suggest that the extended aortoplasty provides a more anatomical re-

pair for supra-ventricular aortic stenosis than does simple patch enlargement. It more closely restores the normal relationship between the aortic sinuses, their cusps, and their commissures. The procedure can be done at no greater operative risk and will excellent relief of the pressure gradient between the left ventricle and the aorta (10). In membranous types, excising the membran may be adequate only.

## REFERENCES

1. Freidman WG, Roberts W. Vitamin D and supra-avalvular aortic stenosis syndrome: The transplacental effects of vitamin D on the aorta of the rabbit. *Circulation* 1966; 34 : 77.
2. Garcia RC, Preidman WF, Kaback MM, Rowe RD. Idiopathic hypercalcemia and supra-avalvular aortic stenosis: Documentation of a new syndrome. *N Engl J Med* 1964; 271: 117-20.
3. Morris CA, Demsey SA, Leonard CO, et al. Natural history of Williams syndrome: Physical characteristics. *J Pediatr* 1988; 113: 318-25.
4. Zalstein E, Moes CAF, Musewe NN, Preedom RM. Spectrum of cardiovascular anomalies in Williams-Beuren syndrome. *Pediatr Cardiol* 1991; 12: 219-23.
5. Kahler RL, Braunwald E, Plauth WH Jr, Morrow AG. Familial congenital heart disease. *Am J Med* 1966; 40: 384-99.
6. Braunwald E. *Heart disease*. Philadelphia: WB Saunders Company, 1992; 926-8.
7. French JW, Gunteroth WG. An explanation of asymmetric upper extremity blood pressure in supra-avalvular aortic stenosis: The Coanda effect. *Circulation* 1970; 42: 31-6.
8. Goldstein RE, Epstein SE. Mechanism of elevated innominate artery pressures in supra-avalvular aortic stenosis. *Circulation* 1970; 42: 23-9.
9. Brand A, Keren A, Reifen RM, et al. Echocardiographic and Doppler findings in the Williams syndrome. *Am J Cardiol* 1989; 63: 633-5.
10. Stewart S, Alexson C, Manning J. Extended aortoplasty to relieve supra-avalvular aortic stenosis. *Ann Thorac Surg* 1988; 46: 427-9.