






Acute Coronary Syndrome In Patient With Susac Syndrome: A Case Report

Susac Sendromu Olan Hastada Akut Koroner Sendrom: Olgu Sunumu

 Ahmet Seyfeddin Gurbuz¹,  Sener Gur¹,  Ahmet Taha Sahin¹,  Serhat Kesriklioglu¹,  Yunus Emre Yavuz²

¹Necmettin Erbakan University, Medical Faculty, Department of Cardiology, Konya, Türkiye
²Siirt Training and Research Hospital, Department of Internal Medicine, Cardiology, Siirt, Türkiye

ÖZET

Susac sendromu beyin, iç kulak ve retinadaki mikrovasküler hasara sekonder geliştiği düşünülmekte olup nadir görülen bir hastalıktır. Patogenezinde anti endotelial hücre antikorlarının rol oynadığı göz önüne alındığında tedavi büyük ölçüde immünsüpresif ilaçlar ile sağlanmaktadır. Sendromun tedavisine erken başlanması ve agresif tedavi, uzun vadeli sonuçlar üzerinde olumlu etkiye sahiptir. Susac sendromunun tromboza yatkınlık oluşturduğuna dair net bir kanıt bulunmamakla birlikte, olgumuzda göğüs ağrısı şikayeti ile başvuran, bilinen Susac sendromu tanısı olan ve akut koroner sendrom ön tanısı ile koroner anjiyografi yapılan bir hastada revaskülarizasyon gerektirecek ciddi koroner arter hastalığının saptanması bu düşüncüyü desteklemektedir. Hastada uygun revaskülarizasyon sağlandıktan sonra şikayetleri gerilemiş ve takiplerinde tekrar revaskülarizasyon gereksinimi olmamıştır. Bu olgu sunumunda Susac sendromlu hastada revaskülarizasyon sürecinde yaşanan zorluklar, alınan kararlar ve diğer alternatif yaklaşımlar gözden geçirilecektir. Olgumuz Susac sendromu ile akut koroner sendromun birlikteliği açısından literatürde ilk olma özelliği taşımaktadır. Susac sendromunu ve kardiyak etkilerini aydınlatmak için daha fazla vaka raporuna ihtiyaç vardır. .

Anahtar Kelimeler: Akut Koroner Sendrom, Susac Sendromu, Koroner Arter Hastalığı

ABSTRACT

Susac syndrome is a rare disease thought to develop secondary to microvascular damage in the brain, inner ear, and retina. Considering that anti-endothelial cell antibodies are involved in its pathogenesis, treatment is largely provided with immunosuppressant drugs. Early initiation of treatment and aggressive therapy have a positive effect on long-term outcomes. Although there is no clear evidence that Susac syndrome creates a predisposition to thrombosis, in our case, the detection of significant coronary artery disease that would require revascularization in a patient diagnosed with Susac syndrome who presented with acute coronary syndrome clinic supports this idea. In this case report, the difficulties in the revascularization process, the decisions made, and other alternative approaches in the patient with Susac syndrome will be reviewed. Our case is the first in the literature to describe the coexistence of Susac syndrome and acute coronary syndrome. More case reports are needed to further elucidate Susac syndrome and its cardiac effects.

Keywords: Acute Coronary Syndrome, Susac Syndrome, Coronary Artery Disease

Geliş Tarihi/Received: 18 Haziran/June 2024 **Kabul Tarihi/Accepted:** 20 Kasım/November 2024 **Yayın Tarihi/Published Online:** 27 Aralık/December 2024

INTRODUCTION

Susac syndrome is characterized by encephalopathy, hearing loss, and retinal artery disease. It was first described by John Susac in 1979 (1). Approximately 300 cases have been reported worldwide, and it is generally diagnosed in individuals aged 20 to 40. It is more common in women than in men (2). Patients typically present with severe headaches, behavioral changes, apathy, hearing loss, tinnitus, and partial vision loss. The diagnosis of Susac syndrome can be missed or delayed due to its rarity and because similar symptoms are also seen in more commonly diagnosed conditions, such as acute disseminated encephalomyelitis and multiple sclerosis. In this case report, we present the acute coronary syndrome and its management in a

patient with Susac syndrome.

CASE REPORT

A 50-year-old male patient with a known diagnosis of hypertension and Susac syndrome (diagnosed 5 years ago after the development of bilateral hearing loss and vision impairment, and currently on 50 mg Azathioprine twice daily) presented to an external center with complaints of chest pain and nausea of a compressive nature in November 2021. The patient's electrocardiogram (ECG) was unremarkable, with no ST-segment changes (Figure 1). Echocardiography did not reveal any left ventricular wall motion defects or major valve pathology. The patient was taken to the coronary angiography laboratory with

Sorumlu Yazar/Corresponding Author: Ahmet Seyfeddin Gurbuz, Necmettin Erbakan University, Medical Faculty, Department of Cardiology, Konya, Türkiye
e-mail: ahmetseyfeddingurbuz@hotmail.com

Atf yapmak için/ Cite this article as: Gurbuz AS, Gur S, Sahin AT, Kesriklioglu S, Yavuz YE. Acute Coronary Syndrome In Patient With Susac Syndrome: A Case Report. Selcuk Med J 2024;40(4): 199-201

Disclosure: Author has not a financial interest in any of the products, devices, or drugs mentioned in this article. The research was not sponsored by an outside organization. Author has agreed to allow full access to the primary data and to allow the journal to review the data if requested.

"This article is licensed under a [Creative Commons Attribution-NonCommercial 4.0 International License](https://creativecommons.org/licenses/by-nc/4.0/) (CC BY-NC 4.0)"



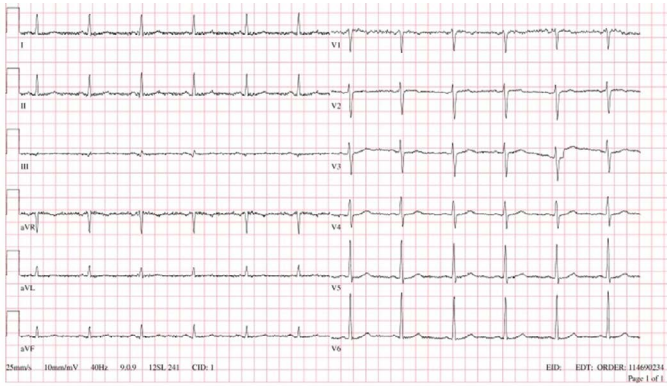


Figure 1. The patient's admission ECG with no ST-T changes.

a diagnosis of acute coronary syndrome, as his troponin level was elevated and his chest pain persisted.

During coronary angiography, advanced ectasia of the left main coronary artery (LMCA) and proximal left anterior descending artery (LAD) was observed. There was 80% stenosis in the LAD after the ectasia, and 85% stenosis was noted in the proximal D1 branch arising from the distal end of the ectasia. The circumflex artery (CX) obtuse marginalis (OM1) branch showed 90% ostial stenosis, and after the separation of OM1, 99% stenosis was observed in the CX. Additionally, there was 70% stenosis in the mid-region of the right coronary artery (RCA). The responsible lesion was considered to be in the CX. A 3.5x16 mm bare-metal stent (BMS) was implanted, and the heart team recommended intervention for the other vessels.

The patient was referred to the Cardiovascular Surgery clinic of our hospital, where coronary artery bypass grafting (CABG) was recommended following consultation with the heart team, and the operation was performed in December 2021. However, during the CABG procedure, the patient's pericardium was found to be highly adherent. The RCA and diagonal (D1) vessels could not be located due to pericardial adhesions, and the operation was terminated with the bypassing of the left internal mammary artery (LIMA) to the LAD.

The patient returned one month later, in January 2022, with chest pain and exertional angina similar to his initial myocardial infarction. After evaluation, a control coronary angiography was planned. In the recent coronary angiography, the LIMA-LAD graft was patent (Figure 2A). Ectasia of the distal and proximal LMCA and LAD was noted, with 95% stenosis at the D1 ostium (Figure 2B). The proximal and mid-region stent in the CX was patent, and the mid-region stenosis of the RCA was assessed as 40%.

Considering that the patient's symptoms were primarily related to the D1 branch, percutaneous coronary intervention

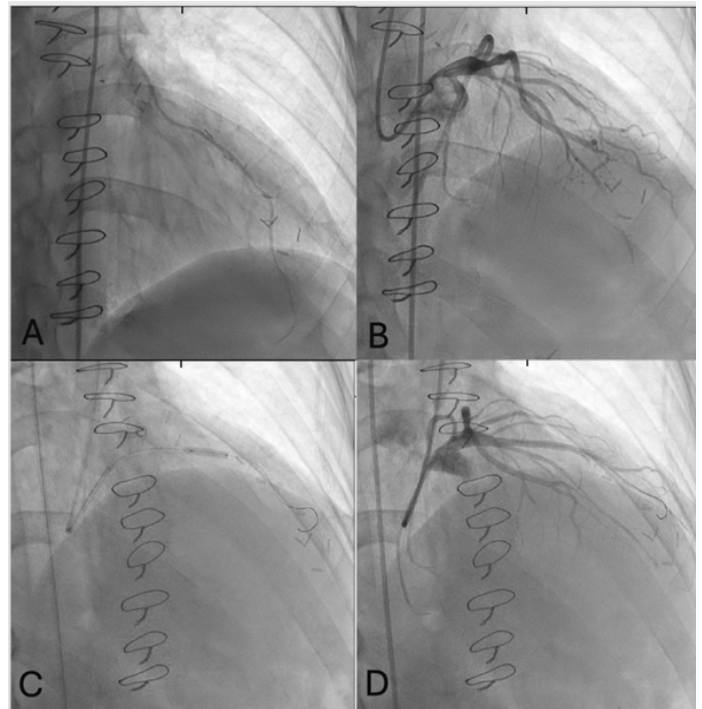


Figure 2. Coronary angiography images

A) LIMA-LAD graft is patent with no significant stenosis. **B)** 95% stenosis at the ostium of diagonal artery. **C)** Implantation of a 3x29 mm DES at the ostial segment of D1. **D)** Post-DES implantation and POT application, the D1 image.

was decided upon for the D1 branch. A 3x29 mm drug-eluting stent (DES) was implanted in the D1 branch extending to the LAD (Figure 2C), followed by POT (proximal optimization technique) with a 4x8 mm non-compliant balloon. No complications occurred, and the procedure was completed successfully (Figure 2D). The patient was discharged with appropriate cardiac medical treatment, including the initiation of dual antiplatelet therapy. In his one-month follow-up, it was observed that his anginal complaints had regressed, and he was clinically stable.

DISCUSSION

Susac Syndrome is recognized as a condition that occurs due to damage to microvascular structures in the brain, inner ear, and retina, as indicated by its clinical triad. In 2011, Susac et al. conducted studies suggesting that anti-endothelial cell antibodies (AECA) may be a cause in the pathogenesis of the disease (3). Indeed, a recent cohort study by Jarius et al. found AECA to be positive in almost 30% of Susac syndrome patients (4). For these reasons, it is accepted that immune mechanisms

contribute to the disease's pathogenesis, leading to the initiation of treatments with immunosuppressive agents (5).

The treatment approaches for this disease are primarily based on clinical experience and expert opinions. It has been observed that patients often have a long-term stable course when aggressive treatments are initiated early. Since the disease progresses in episodes, the goal is to reduce these relapses as much as possible. During these relapse periods, the predisposition to thrombosis remains unclear, and antiplatelet and anticoagulant agents have been initiated in some patients with limited benefit. However, widespread expert opinion recommends the use of antithrombotic agents in the presence of procoagulant risk factors (6).

The cardiac effects of this disease are not yet well understood. It is thought that the severe coronary lesions and coronary ectasia observed in our case may be due to immune-mediated vascular complications of Susac syndrome. Additionally, coronary ectasia can occur in rheumatologic patients who use long-term intensive immunosuppressants. The presence of severe epicardial adipose tissue encountered during coronary artery bypass grafting, along with the inability to perform coronary grafts due to pericardial adhesions, is a complication that should be considered during the course of the disease.

Our case serves as a guide for potential cardiac events that may arise during the course of the disease. It highlights the need for more frequent evaluations for cardiac involvement in the follow-up of patients with Susac syndrome.

Conflict of interest: *The authors declared no conflicts of interest with respect to the authorship and/or publication of this article.*

Financial conflict of interest: *Author declares that he did not receive any financial support in this study.*

Address correspondence to: *Ahmet Seyfeddin Gurbuz, Necmettin Erbakan University, Medical Faculty, Department of Cardiology, Konya, Türkiye*

e-mail: *ahmetseyfeddingurbuz@hotmail.com*

REFERENCES

1. Susac JO, Hardman JM, Selhorst JB. Microangiopathy of the brain and retina. *Neurology*. 1979;29(3):313–6. <https://doi.org/10.1212/wnl.29.3.313>
2. Pereira S, Vieira B, Maio T, et al. Susac's Syndrome: An Updated Review. *Neuro-ophthalmology (Aeolus Press)*. 2020;44(6):355–60. <https://doi.org/10.1080/01658107.2020.1748062>
3. Magro CM, Poe JC, Lubow M, et al. Susac syndrome: an organ-specific autoimmune endotheliopathy syndrome associated with anti-endothelial cell antibodies. *Am J Clin Pathol*. 2011;136(6):903–12. <https://doi.org/10.1309/AJCPERI7LC4VNFYK>
4. Jarius S, Kleffner I, Dörr JM, et al. Clinical, paraclinical and serological findings in Susac syndrome: an international multicenter study. *J Neuroinflammation*. 2014;11:46. <https://doi.org/10.1186/1742-2094-11-46>
5. Bose S, Papathanasiou A, Karkhanis S, et al. Susac syndrome: neurological update (clinical features, long-term observational

- follow-up and management of sixteen patients). *J Neurol*. 2023;270(12):6193–206. <https://doi.org/10.1007/s00415-023-11891-z>
6. Kleffner I, Ringelstein EB, Stupp N, et al. Neurological picture. Susac's syndrome: effective combination of immunosuppression and antiplatelet treatment. *J Neurol Neurosurg Psychiatry*. 2006;77(12):1335. <https://doi.org/10.1136/jnnp.2006.095596>