



e-ISSN: 2149-8059

ISSN: 1017-6616

SELÇUK TIP DERGİSİ SELÇUK MEDICAL JOURNAL

Selçuk Tıp Dergisi, Türk Atıf Dizini (ULAKBİM) ve EBSCO tarafından indekslenmektedir.

Cilt: 39 Sayı: 3 EYLÜL 2023

Araştırma Makalesi / Research Article

How Can Hyperbaric Oxygen Therapy Affect The Diaphragm and Respiratory Functions of The Patients?
Sumen SG, Sener Comert S, Caglayan B.

An Overview of The Results of Direct Immunofluorescence in Mucocutaneous Biopsies: Single Center Experience
Kilinc F, Gulper U, Ozer I, Kilinc I.

The Efficacy of Interfacial Plan Block Procedures on Postoperative Satisfaction of Surgeons: A Survey Study
Alver S.

Is Vitamin D Associated with The Presence, Type and Severity of Migraine?
Altas M, Yarar Z, Caliskan Burgucu H, Kir HH, Kulaksizoglu M.

The Use of Groin Flap for Hand Defects: Which Should Be Prior, Free or Pedicled, Based on Patient-Reported Outcomes?
Altuntas SH, Dilek OF, Gurdal O, Uslusoy F, Aydin MA.

Comparison of Tranexamic Acid and Haemostatic Net in Reducing the Risk of Hematoma in Facelift Surgery
Yildirim MEC, Uyar I.

Efficacy of Ultrasound-Guided Caudal Epidural Steroid Injection for Axial or Radicular Low Back Pain
Yilmaz R, Goksu H, Karpuz S, Tekin L, Yilmaz H.

Olgu Sunumu / Case Report

A Case Report of Alveolar Lobular Breast Cancer Metastasized to the Whole Female Reproductive System
Boluk SE, Boluk S.



SELCUK TIP DERGISI

Cilt: 39 Sayı: 3 EYLÜL 2023

e-ISSN: 2149-8059

ISSN: 1017-6616

Editör (Editor-in-Chief)

BilseV İnce, MD

Yayın Kurulu (Editorial Board)

Hüseyin Ataseven, MD
Talal Chatila, MD
Sevgi Keles, MD
Vijay Shankar, MD
Steven D Wexner, MD Phd
Zerrin Defne Dündar, MD
Sunil Swami, MD
Genevieve M. Crane, MD
Refik Oltulu, MD
Mustafa Özer, MD
Phillip Pirgousis, MD
Earl Stephenson Jr, MD
Khin Soe, MD Phd
Raimundo Geronimo Jr, MD
Pin-Keng Shih, MD
Mehmet Ak, MD
Mehmet Tuğrul Yılmaz, MD
Abdullah Arslan, MD

Uluslararası Danışma Kurulu

Ahmet Topal, MD
Aida Sarac, MD
Ali Mübin Aral, MD
Can Öztürk, MD
Fatema Al Hajeri, MD
Habibah Abdul Hamid, MD
Hasan Energin, MD
Hiroyuki Takamaru, MD
Hürkan Kerimoğlu, MD
I. Emre Gorgun, MD
Koichiro Mori, MD
Laura Orsolini, MD
Mehmet Akif Düzenli, MD
Mehmet Mesut Pişkin, MD
Monzer Hamze, MD
Munise Daye, MD
Mustafa Büyükmumcu, MD
Sandeep Grover, MD
Selim Kutlu, MD
Sertaç Yazıcı, MD
Syed Mehmood Ali, MD
Şafak Uygur, MD
Tevfik Küçükkartallar, MD

İstatistik Editörü (Statistical Editor)

Mehmet Sinan İyisoy, Biyoistatistik Uzm.

Sahibi (Owner)

Prof.Dr. Cem ZORLU
Necmettin Erbakan Üniversitesi
Rektörü

Yayın Sekreteri (Secretary)

İlkay KURT

Haberleşme (Communication)

Selçuk Tıp Dergisi Editörlüğü
Necmettin Erbakan Üniversitesi Meram Tıp Fakültesi 42080
Meram, KONYA
Tel: 0332 223 60 00 Fax: 0332 223 61 81
e-posta: info@selcukmedj.org
Web adresi: www.selcukmedj.org

Selçuk Tıp Dergisi yılda dört sayı (Mart, Haziran, Eylül, Aralık) yayınlanan "peer review" yöntemi ile çalışan hakemli bir dergidir. Selçuk Tıp Dergisi Türkiye Atıf Dizini, Index Copernicus, International Citation Index, Türk Atıf Dizini (ULAKBİM) ve EBSCO tarafından indekslenmektedir.

Grafik-Tasarım

İlkay KURT, 0332 223 62 54

Araştırma Makalesi / Research Article

How Can Hyperbaric Oxygen Therapy Affect The Diaphragm and Respiratory Functions of The Patients?
Hiperbarik Oksijen Tedavisi Uygulanan Hastalarda Solunum Fonksiyonları ve Diafram Üzerine Etkisi Nedir?.....97
Sumen SG, Sener Comert S, Caglayan B.

An Overview of The Results of Direct Immunofluorescence in Mucocutaneous Biopsies: Single Center Experiences
Mukokutanöz Biyopsilerde Direkt İmmüno Floresan Değerlendirme Sonuçlarına Bir Bakış, Tek Merkez Deneyimi.....104
Kilinc F, Gulper U, Ozer I, Kilinc I.

The Efficacy of Interfacial Plan Block Procedures on Postoperative Satisfaction of Surgeons: A Survey Study
İnterfasial Plan Blok Uygulamalarının Cerrahların Postoperatif Memnuniyeti Üzerindeki Etkisi: Anket Çalışması.....114
Alver S.

Is Vitamin D Associated with The Presence, Type and Severity of Migraine?
D Vitamini Migren Varlığı, Tipi ve Şiddeti ile İlişkili Midir?.....122
Altas M, Yazar Z, Caliskan Burgucu H, Kir HH, Kulaksizoglu M.

The Use of Groin Flap for Hand Defects: Which Should Be Prior, Free or Pedicled, Based on Patient-Reported Outcomes?
El Defektleri İçin Kasık Flebinin Kullanımı: Serbest veya Pediküllü, Hasta Bildirim Sonuçlarına Göre Hangisi Öncelikli Olmalı?.....128
Altuntas SH, Dilek OF, Gurdal O, Uslusoy F, Aydın MA.

Comparison of Tranexamic Acid and Haemostatic Net in Reducing the Risk of Hematoma in Facelift Surgery
Yüz Germe Ameliyatında Hematom Riskini Azaltmada Traneksamik Asit ve Hemostatik Netin Karşılaştırılması.....135
Yıldırım MEC, Uyar I.

Efficacy of Ultrasound-Guided Caudal Epidural Steroid Injection for Axial or Radicular Low Back Pain
Lomber Aksiyel veya Radiküler Ağrılı Hastalarda Ultrason Kılavuzluğunda Kaudal Epidural Steroid Enjeksiyonunun Etkinliği.....139
Yılmaz R, Goksu H, Karpuz S, Tekin L, Yılmaz H.

Olgu Sunumu / Case Report

A Case Report of Alveolar Lobular Breast Cancer Metastasized to the Whole Female Reproductive System
Kadın Üreme Sisteminin Tamamına Metastaz Yapan Alveolar Lobüler Meme Kanseri Vaka Sunumu.....147
Ozbiğce S, Turen Demir E, Oltulu P, Korkmaz M, Artac M, Acar A.

YAZARA AÇIKLAMA

Selçuk Tıp Dergisi (Selcuk Med J) Necmettin Erbakan Üniversitesi, Meram Tıp Fakültesi Dekan'lığının yayın organıdır. Dergimize yazı hazırlanırken aşağıdaki açıklamaları lütfen bütünüyle okuyunuz.

Selçuk Tıp Dergisi (Selcuk Med J) tıp bilimine ve akademik çalışmalara katkısı olan, klinik ve deneysel çalışmaları, editöryal yazıları, kısa raporları, klinik olgu bildirimlerini, teknik ve eğitici derlemelerini, tıp konusundaki son gelişmeler ile orijinal görüntü raporlarını, görüntülü hastalık tanımlama sorularını ve editöre mektupları yayımlar. Ayrıca daha önce yayınlanmış makale ve deneysel çalışmalarla ilgili okuyucu soru ve katkıları kısaca yayımlanır. Yayına kabul edilme, editöryal komite ile en az iki hakem kararı ile alınır. Bir hakem, hakemlik talebini kabul etmeye karar vermeden önce, hakem değerlendirme süreci ve gözden geçirmenin nasıl yapılacağı hakkında daha fazla bilgi edinmek isteyebilir.

Hakemler, Selçuk Tıp Dergisi'nin gereklerine, önceden tanımlanmış kriterlere ve sunulan araştırmanın kalitesine, eksiksizliğine ve doğruluğuna dayanarak makale gönderimini değerlendirir. Hakemler makale hakkında geri bildirimde bulunur, iyileştirmeler önerir ve makalede yapılan değişiklikleri kabul edip etmeme, talep etme veya reddetme konusunda editöre tavsiyede bulunur. Nihai karar her zaman baş editöre aittir, ancak hakemler sonucu belirlemede önemli bir rol oynamaktadır. Bir hakemin makaleyle çıkar çatışması varsa, editöre bildirmesi gerekir. Hakemler, hakem gözden geçirme sistemine katılarak bilimsel sürecin katı standartlarını sağlamalıdır. Ayrıca, geçersiz araştırmaları tespit ederek ve derginin kalitesini korumaya yardımcı olarak derginin bütünlüğünü korumalıdır. Hakemler, intihal, araştırma sahtekarlığı ve diğer sorunları tespit ederek etik konuların ihlal edilmesini önlemeye gönüllü olmalıdır.

Yayına kabul edilen yazıların her türlü yayın hakkı dergiye aittir. Bu hak özel düzenlenmiş yayın hakkı devir formu ile bütün yazarların imzası ile tespit edilir. Dergi 3 ayda bir, yılda 4 kez yayımlanır. Derginin yayın dili Türkçe ve/veya İngilizcedir. Gönderilen yazılar daha önce herhangi bir dergide yayınlanmamış olmalıdır (Bilimsel kongrelerde sunulan sözlü bildiri ve posterler bildirmek kaydı ile hariçtir). Dergide yayımlanan yazıların her türlü sorumluluğu (etik, bilimsel, yasal vb.) yazarlara aittir. Yazım kurallarına uygun olarak hazırlanmamış olan yazıların incelenmeye alınıp alınmaması Yayın Kurulu'nun inisiyatifindedir.

Makalelerin daha önce hiçbir yerde yayınlanmamış ve yayın için başka bir dergiye gönderilmemiş olması gerekir. Selçuk Tıp Dergisi'nde intihal programı (iThenticate) kullanılmaktadır. Akademik atıf sınırını aşan benzerlik taşıyan makaleler ve yayın kurallarına uygun olarak hazırlanmamış

makaleler değerlendirmeye alınmayacaktır. Tüm çalışmalarda etik kurul onayı gerekmektedir ve bu onamın belgelendirilmesi yazıların yayınlanmasında esas teşkil edecektir.

Tüm çalışmalarda yazarların çalışmaya katkı düzeyi ve onayı bildirilmelidir. Çalışmada veri toplanması, deney aşaması, yazım ve dil düzenlemesi dahil olmak üzere herhangi bir aşamasında finansal çıkar çatışması olmadığı bildirilmelidir. Çalışmada varsa ticari sponsorluk bildirilmelidir.

Derginin editöryal ve yayın süreçleri International Committee of Medical Journal Editors (ICMJE), World Association of Medical Editors (WAME), Council of Science Editors (CSE), Committee on Publication Ethics (COPE), European Association of Science Editors (EASE) ve National Information Standards Organization (NISO) organizasyonlarının kılavuzlarına uygun olarak biçimlendirilmiştir. Selçuk Tıp Dergisi'nin editöryal ve yayın süreçleri, Principles of Transparency and Best Practice in Scholarly Publishing (doaj.org/bestpractice) ilkelerine uygun olarak yürütülmektedir. Yayın Kurulu, dergimize gönderilen çalışmalar hakkındaki intihal, atıf manipülasyonu ve veri sahteciliği iddia ve şüpheleri karşısında COPE kurallarına uygun olarak hareket edecektir.

Derginin Yayın Kurulu, itiraz ve şikayet vakalarını, COPE rehberleri kapsamında işleme almaktadır. Yazarlar, itiraz ve şikayetleri için doğrudan baş editör veya yayın kurulu ile temasa geçebilirler. İhtiyaç duyulduğunda Yayın Kurulu'nun kendi içinde çözemediği konular için tarafsız bir temsilci atanmaktadır. İtiraz ve şikayetler için karar verme süreçlerinde nihai kararı Baş Editör verecektir. Yayıncı ve editör gerektiğinde düzeltmeler, açıklamalar, geri çekilmeler ve özürler yayınlamaya her zaman hazırdır.

Selçuk Tıp Dergisi (Selcuk Med J) ile ilgili tüm yazışmalar, makale gönderme, makalenin takibi, danışman raporları, düzeltmelerin yapılıp yüklenmesi, kabul yazısı gönderimi ve diğer tüm makale ile ilgili formların yüklenmesi <https://www.selcukmedj.org> sayfasından yapılacaktır. Bu site üzerinden yüklenecek makaleler için kurallar aşağıda belirtilmiştir.

YAZIM KURALLARI

Yayına gönderilen yazılar Microsoft Word programında yazılmalıdır. Yazı, şekil ve grafiğin tamamı elektronik ortamda <https://www.selcukmedj.org> word ve pdf formatında gönderilmelidir.

Tüm yazılar:

1. Başlık sayfası,
2. Türkçe özet,
3. İngilizce özet,

4. Makale kısmı,
5. Kaynaklar,
6. Tablolar,
7. Şekiller ve resimler,
8. Alt yazılar şeklinde dizilmelidir.

Araştırma inceleme yazılarının makale kısmı (özet, referanslar, tablo, şekil ve alt yazılar hariç) toplam 4000 kelimeyi, özet kısmı 400 kelimeyi, referanslar 60'ı, tablo ve şekil sayısı 10'u geçmemelidir. Özet amaç, gereç ve yöntemler, bulgular ve sonuç bölümlerini içermelidir.

Olgu bildirileri şu bölümlerden oluşmalıdır: Başlık, İngilizce başlık, Türkçe ve İngilizce özet, giriş, olgunun/olguların sunumu, tartışma ve kaynaklar. Olgu sunumları toplam 8 sayfayı geçmemeli ve 3 resimden fazla olmamalıdır. Özet 200 kelimeyi geçmemeli ve tek bir paragraf şeklinde olmalıdır.

Derlemeler İngilizce ve Türkçe özet içermeli ve özet kelime sayısı 300'ü aşmamalıdır. Tablo sayısı ve şekiller (veya resimler) toplam 6 adedi aşmamalıdır. REferanslar 80'i geçmemelidir. Özet tek bir paragraf şeklinde olmalıdır. Editöre mektup, kısa raporlar, görüntü raporları, teknik ve tıp alanındaki gelişmelere ait yazılar ve orijinal konulara ait görüntü sunumları 2 sayfayı geçmemelidir. Kısa bir (100 kelime) İngilizce ve Türkçe özet içermelidir.

YAZILARIN HAZIRLANMASI

Yazının başlığı hem İngilizce hem de Türkçe olarak yazılmalıdır. Yazıda çalışmaya katkısı olan yazarların ad ve soyadları açık olarak yazılmalı. Yazıların altına çalışmanın yapıldığı kurumun açık adresi yazılmalıdır. Çalışma daha önce herhangi bir kongrede sunulmuş ise kongre adı, zamanı (gün-ay-yıl olarak) belirtilmelidir. Başlık sayfasının en altına iletişim kurulacak yazarın adı, soyadı, açık adresi, posta kodu, telefon ve faks numaraları ile e-posta adresi yazılmalıdır.

Özetler

Ayrı bir sayfa olarak verilmelidir. İngilizce özetin başında İngilizce başlık bulunmalıdır. Araştırma inceleme yazılarında 400, olgu sunumlarında 200 kelimeyi geçmemelidir. Araştırma makalelerinde özet amaç, gereç ve yöntemler, bulgular ve sonuç bölümlerini içermelidir. Araştırma ve inceleme yazılarında özetlerden sonra Türkçe ve İngilizce anahtar kelimeler verilmelidir. Anahtar kelime sayısı 5'i geçmemelidir. Anahtar Kelimelerin İngilizcesi Index Medicus'daki Medical Subjects Headings'e uygun olmalı, Türkçe Anahtar kelimeler ise Türkiye Bilim Terimleri'nden (<http://www.bilimterimleri.com>) seçilmelidir. Özetlerde kısaltma olmamalıdır.

Makale

Yazı Giriş, Gereçler ve Yöntem, Bulgular ve Tartışma bölümlerinden oluşur.

Giriş: Konuyu ve çalışmanın amacını açıklayacak bilgilere yer verilir.

Gereçler ve Yöntem: Çalışmanın gerçekleştirildiği yer, zaman ve çalışmanın planlanması ile kullanılan elemanlar ve yöntemler bildirilmelidir. Verilerin derlenmesi, hasta ve bireylerin özellikleri, deneysel çalışmanın özellikleri ve istatistiksel metotlar detaylı olarak açıklanmalıdır. Çalışma klinik bir çalışma ise başlık 'Hastalar ve Yöntem' şeklinde olmalıdır.

Bulgular: Elde edilen veriler istatistiksel sonuçları ile

beraber verilmelidir.

Tartışma: Çalışmanın sonuçları literatür verileri ile karşılaştırılarak değerlendirilmelidir.

Tüm yazımlar Türkçe yazım kurallarına uymalı, noktalama işaretlerine uygun olmalıdır. Kısaltmalardan mümkün olduğunca kaçınılmalı, eğer kısaltma kullanılacaksa ilk geçtiği yerde () içerisinde açıklanmalıdır. Kaynaklar, şekil tablo ve resimler yazı içerisinde geçiş sırasına göre numaralandırılmalıdır. Metin içerisindeki tüm ölçüm birimleri uluslararası standartlara uygun biçimde verilmelidir.

Kaynaklar

Kaynaklar iki satır aralıklı olarak ayrı bir sayfaya yazılmalıdır. Kaynak numaraları cümle sonuna nokta konmadan () içinde verilmeli, nokta daha sonra konulmalıdır. Kaynak yazar isimleri cümle içinde kullanılıyorsa ismin geçtiği ilk yerden sonra () içinde verilmelidir. Birden fazla kaynak numarası veriliyorsa arasına “,”, ikiden daha fazla ardışık kaynak numarası veriliyor ise rakamları arasına “,-” konmalıdır [ör.(1,2), (1-3)gibi]. Kaynak olarak dergi kullanılıyorsa: yıl, cilt, başlangıç ve bitiş sayfaları verilir. Kaynak olarak kitap kullanılıyorsa: sadece yıl, başlangıç ve bitiş sayfaları verilir. Kaynaklarda yazarların soyadları ile adlarının baş harfleri yazılmalıdır. Dergi isimleri Index Medicus'a göre kısaltılmalıdır. Kaynak yazılma şekli aşağıdaki örnekler gibi olmalıdır. Yazar sayısının üçten fazla olması durumunda ise ilk üç yazarın ismi yazılmalı, sonrasında “et al.” eklenmelidir.

Dergiler için

1) Kocakuşak A, Yücel AF, Arıkan S. Karına nafiz delici-kesici alet yaralanmalarında rutin abdominal eksplorasyon yönteminin retrospektif analizi. Van Tıp Dergisi 2006;13(3):90-6.

2) Vikse BE, Aasard K, Bostad L, et al. Clinicalprognostic factors in biopsy-proven benign nephrosclerosis. Nephrol Dial Transplant 2003;18:517-23.

Kitaplar için

1) Danovitch GM. Handbook of Kidney Transplantation. Boston: Little, Brown and Company (Inc.), 1996: 323-8.

Kitaptan Bölüm İçin

1) Soysal Z, Albek E, Eke M. Fetüs hakları. Soysal Z, Çakalır C, ed. Adli Tıp, Cilt III, İstanbul Üniversitesi Cerrahpaşa Tıp Fakültesi Yayınları, İstanbul, 1999:1635-50.

2) Davison AM, Cameron JS, Grünfeld JP, et al. Oxford Textbook of Clinical Nephrology. In: Williams G, ed. Mesengiocapillary glomerulonephritis. New York: Oxford University Press, 1998: 591- 613.

Tablolar

Tablolar ayrı sayfaya iki satır aralıklı yazılmalı, her tablonun üzerinde numara ve açıklayıcı ismi olmalıdır. Tabloda kısaltmalar varsa tablonun altında alfabetik sıraya göre açıklamaları yazılmalıdır. Örnekler: PS: pulmoner stenoz, VSD: ventriküler septal defekt. Tablolar yazı içindeki bilgilerin tekrarı olmamalıdır.

Şekil ve Resimler

Şekil ve resimler mutlaka isimlendirilmeli ve numaralandırılmalıdır. Resimler minimum 300 dots per inch (dpi) çözünürlüğünde ve net olmalıdır. Resimler makaleden ayrı bir şekilde makale gönderimi esnasında elektronik olarak JPEG formatında gönderilmelidir.

Makale içerisinde geçen resimler kabul edilmeyecektir. Renkli resimlerin basımı ancak yazarın basım ücretini kabul etmesi ve bu ücreti ödemesi halinde mümkün olacaktır. Aksi takdirde resim siyah-beyaz olarak basılır. Şekil ve resim altlarında kısaltmalar kullanılmış ise, kısaltmaların açılımı alfabetik sıraya göre alt yazının altında belirtilmelidir. Mikroskopik resimlerde büyütme oranı ve tekniği açıklanmalıdır. Yayın kurulu, yazının özünü değiştirmeden gerekli gördüğü değişiklikleri yapabilir.

HAKEM RAPORU SONRASINDA DEĞERLENDİRME

Yazarlar hakem raporunda belirtilen düzeltme istenen konuları maddelendirerek bir cevap olarak kendilerine ayrılan cevap bölümüne yazmalıdırlar ve ek bir dosya şeklinde yüklenmelidir <https://www.selcukmedj.org>. Ayrıca makale içerisinde de gerekli değişiklikleri yapmalı ve bunları makale içerisinde belirterek (boyayarak) online olarak tekrar göndermelidirler.

SON KONTROL

1. Yayın hakkı devir ve yazarlarla ilgili bildirilmesi gereken konular formu gereğince doldurulup imzalanmış,
2. Özet makalede 400, olgu sunumunda 200 kelimeyi aşmamış,
3. Başlık Türkçe ve İngilizce olarak yazılmış,
4. Kaynaklar kurallara uygun olarak yazılmış,
5. Tablo, resim ve şekillerde bütün kısaltmalar açıklanmış olmalıdır.

ONLİNE YÜKLEME BASAMAKLARI

<https://www.selcukmedj.org> sayfasında

1. Makale şekli *
2. Türkçe ve İngilizce başlık *
3. Kısa başlık *
4. Türkçe ve İngilizce özet*
5. Türkçe ve İngilizce anahtar kelimeler *
6. Yüklenmesi gerekli bölümler (word makale dosyası, makale dosyasının pdf formatı, Başlık sayfası, copyright formu, ek dosyalar (resim, şekil ve tablolar) şeklinde 5 basamakta tamamlanmalıdır.

INSTRUCTIONS FOR AUTHORS

Selcuk Medical Journal (Selcuk Med J) is a scientific publication of Necmettin Erbakan University, Meram Faculty of Medicine.

Please entirely read the instructions discussed below before submitting your manuscript to the journal. Selcuk Medical Journal publishes original articles on clinical or experimental work, case histories reporting unusual syndromes or diseases, brief reports, technical and educative reviews, recent advancement of knowledge of the medical sciences with original images, questionnaires of defining disease, and letters to the editor.

Final recommendation for publication is made by the editorial board and at least two independent reviewers. Before reviewers decide to accept a request to review, they might want to know more about the peer review process and how to conduct a review. Reviewers evaluate article submissions to journal based on the requirements of Selcuk Medical Journal, predefined criteria, and the quality, completeness and accuracy of the research presented. Reviewers provide feedback on the paper, suggest improvements and make a recommendation to the editor about whether to accept, reject or request changes to the article. The ultimate decision always rests with the chief editor but reviewers play a significant role in determining the outcome.

If a reviewer has conflict of interest regarding article, he should inform it to the editor. Reviewers should ensure the rigorous standards of the scientific process by taking part in the peer-review system. Also they should uphold the integrity of the journal by identifying invalid research, and helping to maintain the quality of the journal. Reviewers should be volunteer to prevent ethical breaches by identifying plagiarism, research fraud and other problems by dint of their familiarity with the subject area. The copyrights of articles accepted for publication is belonged to journal. This is determined by the assignment of copyright statement, signed by all authors.

The journal is published four times in a year. The language of the journal is Turkish and/or English. Manuscripts submitted to the journal should not be published before or not under consideration elsewhere (in the case of previous oral or poster presentation of the paper at scientific meetings author should inform the journal). The full responsibility of the articles (ethic, scientific, legal, etc.) published in the journal belong to the authors. If the paper is not prepared in conformity with the writing instructions, decision for its evaluation will be made by the members of the editorial board. The articles have not been published anywhere before and no other journal has been sent for the publication. Plagiarism program (iThenticate) is used in Selcuk Medical Journal. Articles with similarities that exceed the academic citation limit and/or articles that are not prepared in accordance with the publication rules will not be evaluated. All studies require approval of the ethics committee and certification of this certificate will be the basis for the publication of the manuscripts.

All studies should be informed of the level of authors' contribution and approval. The study should also be informed that there is no financial conflict of interest at any stage, including data collection, experimentation,

writing and language editing. Commercial sponsorship should be reported if it is in work.

The editorial and publication processes of the journal include the International Committee of Medical Journal Editors (ICMJE), the World Association of Medical Editors (WAME), the Council of Science Editors (CSE), the Committee on Publication Ethics (COPE), the European Association of Science Editors (EASE) and the National Information Standards Organization (NISO). The editorial and publishing processes of the Selcuk Medical Journal are conducted in accordance with the principles of Transparency and Best Practice in Scholarly Publishing (doaj.org/bestpractice).

The Editorial Board will act in accordance with COPE rules in the face of claims and suspicions of plagiarism, citation manipulation and data forgery of works submitted to our journal. The Editorial Board of the journal handles cases of objections and complaints within the scope of COPE guidelines. Authors can contact the Chief Editor or Editorial Board directly for objections and complaints. When necessary, an impartial representative is appointed for issues that the Editorial Board cannot solve within itself. The Chief Editor will make the final decision in the decision-making process for appeals and complaints.

Publisher and editor always be willing to publish corrections, clarifications, retractions and apologies when needed.

The all correspondences (manuscript submission, follow up, reviewers reports, revision files, acceptance form and other forms about publications) about Selcuk Medical Journal should be made online at <https://www.selcukmedj.org>. The rules about the manuscripts that would be submitted are given below.

WRITING INSTRUCTIONS

Submitted manuscripts should be prepared using Microsoft Word program. All manuscripts, figures and pictures must be submitted electronically as word and pdf format h <https://www.selcukmedj.org> . Authors should ensure that (apart from the title page) the manuscript should contain no clues about the identity of authors and institution where the study was performed.

All papers should be arranged on the basis of following sequence: 1. Title page, 2. Turkish abstract, 3. English abstract, 4. Text of the article, 5. References, 6. Table(s), 7. Figure(s) and illustration(s), 8. Figure legend(s). In the original (research) articles number of words should not exceed 4000 (except abstract, references, tables, figures and legeds) for the text of article and 400 for the abstract. Upper limit for reference number is 60, and this limit is 10 for tables and figures. The abstracts should include objective, materials and methods, results and conclusion sections. Case reports should be composed of Turkish and English title, Turkish and English abstracts, introduction, case report, discussion and references. The number of typewritten pages should not exceed 8 pages and 3 picture in case reports. In abstract, numbers of words should not exceed 200 and should be written as a paragraph.

Reviews should be composed of Turkish and English title. In abstract, numbers of words should not exceed

400. In reviews number of tables and figures (or pictures) should not exceed 6. Upper limit for reference number is 80. Abstracts should be written as a paragraph.

Letter to editor, brief report, image report, advancements in technical and medical topics and questionnaires of original issues should not exceed 2 typewritten pages. Its should be composed of Turkish and English abstracts (100 words).

PREPARATION OF MANUSCRIPT

Title Page

Title of the article should be written both in English and Turkish. The first and last names for all contributors designated as author should be written clearly. Subsequently, address of the institution where the study was performed should be written clearly. If the study was previously presented in any scientific meeting, name and date (as day-month-year) of the organization should be written. The name and mailing address of the corresponding author, accompanied by telephone and fax numbers, and e-mail should be written at the bottom of title page.

Abstracts

Abstracts should be given in separate sheets. English title should be used for English abstracts. The abstracts should not exceed 400 words in original articles and 200 words in case reports. The abstract should include objective, materials and methods, results and conclusion sections in research articles. Turkish and English key words should be listed at the bottom of the abstract page in original articles and should not be more than 5 words. In selecting key words, authors should strictly refer to the Medical Subject Headings (MeSH) list of the Index Medicus. Turkish key words should be selected from Turkish Science Term (<http://www.bilimterimleri.com>). The abbreviations should not be used in the abstract.

Text

Text is composed of Introduction, Materials and Methods, Results and Discussion.

Introduction: The matter and purpose of the study is clearly defined.

Materials and Methods: This should include the date and design of the study, the setting, type of participants or materials involved, a clear description of all interventions and comparisons, and the statistical analysis. If the study is a clinical study the title should be 'Patients and Methods'.

Results: Collected data and results of statistical analysis should be outlined in this section.

Discussion: The discussion section should include interpretation of study findings and results should be considered in the context of results in other trials reported in the literature. All written content should be prepared in conformity with grammar and punctuation rules. Avoid abbreviations whenever possible; in case of necessary, it should be given in parentheses when they are first used. References, figures, tables and illustrations should be consecutively numbered in the order in which they have been cited in the text. All measurement units in the text should be used in accordance with

international standards for units of measurement.

References

References should be given in a separate sheet with double spaced. References should be consecutively numbered in the order in which they are first mentioned in the text using Arabic numerals (in parentheses). If the author names in references are used in a sentence, it should be given in parentheses when they are first used. Reference number should be placed at the end of sentence before the period. If there are multiple references number use “,” between them and “-” should be inserted between digits when three or more consecutive references are used [e.g. (1,2), (1,3)]. Journal references should include the following information: year, volume, first and last pages of article. Book references should include only year and first and last pages of the article. Authors in the references should be cited with last names and first initials. Journal's title should be abbreviated in conformity with the Index Medicus system. References should be cited as per the examples below. If there are more than 3 authors, only first 3 may be listed followed by “et al” for references.

Journal references:

1) Kocakuşak A, Yücel AF, Arıkan S. Karına nazif kesici-delici batin yaralanmalarında rutin abdominal eksplorasyon yönteminin retrospektif analizi. Van Tıp Dergisi 2006;13(3):90-6.

2) Vikse BE, Aasard K, Bostad L, et al. Clinicalprognostic factors in biopsyproven benign nephrosclerosis. Nephrol Dial Transplant 2003;18:517-23.

Book references:

1) Danovitch GM. Handbook of kidney transplantation. Boston: Little, Brown and Company (Inc.), 1996: 323-8. Chapter in book references:

1) Soysal Z, Albek E, Eke M. Fetüs hakları. Soysal Z, Çakalır C, ed. Adli Tıp, Cilt III, İstanbul Üniversitesi, Cerrahpaşa Tıp Fakültesi Yayınları, İstanbul, 1999: 1635-50.

2) Davison AM, Cameron CS, Grünfeld CF, et al. Oxford textbook of clinical nephrology. In: Williams G, ed. Mesengiocapillary glomerulonephritis. New York: Oxford University Press, 1998: 591- 613.

Tables

Tables should be printed on a separate sheet with double spaced. Each table should contain a table number in the order in which they are first mentioned in the text and title that summarizes the whole table. All abbreviations used in the table should be alphabetically arranged and defined under the table (e.g., PS; pulmonary stenosis, VSD: ventricular septal defect).

Figures and Illustrations

Figures and illustrations should be named and numbered. Figures should be provided with a minimum of 300 dots per inch (dpi) in JPEG format and should be clear. Figures must be submitted online during manuscript submission. Figures embedded into article will not be accepted. If authors accept to charge extra cost, colored publication of the illustrations is possible; otherwise all illustrations will be published as black and white. All abbreviations used in the figures and illustrations should be alphabetically arranged and defined under the footnote. Technique and ratio of magnification for

photomicrographs should be indicated. The editorial board has the right to make any revisions on the manuscript unless such changes interfere with the scientific data presented.

REVISION AFTER REFEREE REPORT

Authors should point by point reply the items on which revision is demanded via referee report to the reserved box in the online system and as additional files should be uploaded <https://www.selcukmedj.org>. Additionally they should do necessary changes in article and highlight them and submit online again.

FINAL CHECKING

1. All pages have been numbered beginning from first page of the text. 2. Assignment of copyright form has been properly filled and signed. 3. The abstract should not exceed 400 words in original articles and 200 words in case reports. 4. The title has been separately written in Turkish and in English. 5. References is in conformity with the instructions. 6. All abbreviations used in tables, figures and illustrations have been defined.

ONLINE STEPS

At <https://www.selcukmedj.org>

1. Article Type *
2. Article Title in English *
3. Running Title *
4. Manuscript Abstract in English *
5. Key Words in English and Turkish *
6. This sections should be uplodged at 5 steps(Article File, Article File in PDF

Format, Title Page,

Form of Matters Related to Copyright Transfer Agreement and Instructions for Authors, Uploaded Main Files, Additional Files (figures, pictures and tables).

DERGİ HAKKINDA

İlk olarak 1984 yılında yayın hayatına başlayan Selçuk Tıp Dergisi (Selcuk Med J) (ISSN: 1017-6616, e-ISSN: 2149-8059), Necmettin Erbakan Üniversitesi, Meram Tıp Fakültesi'nin bağımsız, çift kör, hakemli bilimsel yayın organıdır. Dergimiz Mart, Haziran, Eylül ve Aralık aylarında üç ayda bir yayımlanmaktadır.

Derginin sayılarına tam erişim aşağıdaki adresten temin edilebilir.

<http://www.selcukmedj.org>

Selçuk Tıp Dergisi (Selcuk Med J) dünya genelinden yayınları kabul etmektedir. Yayınlar en az iki hakem tarafından orijinal bilgi, fikir ve sunum açısından değerlendirilmektedir.

Selçuk Tıp Dergisi (Selcuk Med J), Türkçe ve/veya İngilizce makaleleri yayınlar, dergi içeriklerine ücretsiz erişim sağlar (Open Access) ve yazarların makalelerin son kabul edilmiş halini OAI uyumlu kurumsal / konu bazlı bir havuzda kendi arşivleyebilmelerine izin verir.

Selçuk Tıp Dergisi (Selcuk Med J) tıp doktorları, araştırmacılar ve bilim adamlarından oluşan bir kitleye yönelik çok disiplinli bir dergidir.

Etik Kurallara Uygunluk

Derginin yayın ve yayın süreçleri Uluslararası Medikal Dergisi Editörleri Komitesi (International Committee of Medical Journal Editors) (ICMJE), Dünya Tıbbi Editörler Birliği (World Association of Medical Editors) (WAME), Bilim Editörleri Konseyi (Council of Science Editors) (CSE), Yayın Etiği Komitesi (Committee on Publication Ethics) (COPE), Avrupa Bilim Editörleri Derneği (European Association of Science Editors) (EASE) ve Ulusal Bilgi Standartları Örgütü (National Information Standards Organization) (NISO) yönergelerine uygun olarak şekillendirilmiştir.

Dergimiz 'Şeffaflık ve Akademik Yayıncılık En İyi Uygulamalar İlkelerine' (Principles of Transparency and Best Practice in Scholarly Publishing) (doaj.org/bestpractice) uygundur.

Makalelerin daha önce hiçbir yerde yayınlanmamış ve yayın için başka bir dergiye gönderilmemiş olması gerekir. Selçuk Tıp Dergisi'nde intihal programı (iThenticate) kullanılmaktadır. Akademik atfı aşan benzerlik taşıyan makaleler ve yayın kurallarına uygun olarak hazırlanmamış makaleler değerlendirmeye alınmayacaktır. Tüm çalışmalarda etik kurul onayı gerekmektedir ve bu onayın belgelendirilmesi yazıların yayınlanmasında esas teşkil edecektir.

Tüm çalışmalarda yazarların çalışmaya katkı düzeyi ve onayı bildirilmelidir. Çalışmada veri toplanması, deney aşaması, yazım ve dil düzenlemesi dahil olmak üzere herhangi bir aşamasında finansal çıkar çatışması olmadığı bildirilmelidir. Çalışmada varsa ticari sponsorluk bildirilmelidir.

Yazarlardan Selçuk Tıp Dergisi'nde yayımlanacak makaleleri için herhangi bir ödeme istenmez.

Bütün makaleler editor ve yayın kurulu tarafından üç ay içerisinde sonuçlandırılacaktır. Fakat elde olmayan gecikmelerden dolayı bu süre uzayabilir.

Dergi Amaç ve Kapsamı

Selçuk Tıp Dergisi amacı, genel tıp alanında tanı ve tedavideki güncel gelişmeler, cerrahi yenilikler ve bilim dünyasına katkıda bulunacak deneysel çalışmaların ulusal ve uluslararası literatürde paylaşımının sağlanmasıdır.

Selçuk Tıp Dergisi, sağlık bilimlerindeki tüm etik yönergelere uygun olarak hazırlanmış klinik ve deneysel araştırma makaleleri, olgu bildirimleri, derleme makaleleri, teknik notlar ve editöre mektupları yayımlamaktadır.

How Can Hyperbaric Oxygen Therapy Affect The Diaphragm and Respiratory Functions of The Patients?

Hiperbarik Oksijen Tedavisi Uygulanan Hastalarda Solunum Fonksiyonları ve Diyafram Üzerine Etkisi Nedir?

Selin Gamze Sumen¹, Sevda Sener Comert², Benan Caglayan³

¹University of Health Sciences, Hamidiye International Faculty of Medicine, Kartal Dr. Lutfi Kırdar City Hospital, Department of Underwater and Hyperbaric Medicine, Istanbul, Turkey

²University of Health Sciences, Hamidiye International Faculty of Medicine, Kartal Dr. Lutfi Kırdar City Hospital, Department of Chest Diseases, Istanbul, Turkey

³Istanbul Oncology Hospital, Department of Chest Diseases, Istanbul, Turkey

Address correspondence to: Selin Gamze Sumen, University of Health Sciences, Hamidiye International Faculty of Medicine, Kartal Dr. Lutfi Kırdar City Hospital, Department of Underwater and Hyperbaric Medicine, Istanbul, Turkey
e-mail: sgsumen@gmail.com

Geliş Tarihi/Received: 24 May 2023

Kabul Tarihi/Accepted: 29 August 2023

Öz

Amaç: Bu retrospektif çalışmada, hiperbarik oksijen tedavisinin ardışık uygulamalarda hastaların solunum fonksiyonları ve diyafragma hareketleri üzerindeki etkilerini değerlendirmeyi amaçladık.

Hastalar ve Yöntem: Çalışma grubu, Haziran 2019-Aralık 2021 tarihleri arasında hiperbarik oksijen tedavisi uygulanan çeşitli hastalık tanısı alan 22 hastadan oluşuyordu. Dinamik ve statik akciğer hacimleri, difüzyon kapasitesi, maksimum inspiratuar ve ekspiratuar basınçlar gibi solunum fonksiyonları tedavi seanslarının başlamasından ve bitiminden önce değerlendirildi. Ayrıca torasik ultrasonografi ile diyafram kalınlığı, gelgit volümü ve derin inspirasyon sırasındaki diyafram hareketleri ölçüldü.

Bulgular: Çalışmaya yaş ortalaması 53.3±10.0 yıl olan yirmi iki hasta (16 erkek;6 kadın) dahil edildi. Hastaların hiperbarik oksijen tedavilerinin sonunda yapılan ölçümlerde total akciğer kapasitesi, vital kapasite ve rezidüel volüm de artış görüldü (p<0.05). Diğer statik akciğer hacimleri, maksimum inspiratuar ve ekspiratuar basınçlar, akciğer karbon monoksit difüzyon kapasitesinde değişiklik gözlenmedi. Tidal volümü hareketi ve vital kapasite sırasında diyafram kalınlığı ve diyafram hareketi artmıştır (p<0.05).

Sonuç: Çalışmamızda hiperbarik oksijen tedavisinin diyafram ve solunum fonksiyonları üzerindeki etkisini, spirometri, diyafram görüntüleme teknikleri ve difüzyon kapasitesi yöntemleri ile değerlendirdik. Sonuç olarak, hiperbarik oksijen tedavisi pulmoner ve diyafram kası fonksiyonlarında anlamlı bir değişikliğe yol açmıştır.

Anahtar Kelimeler: Akciğer, difüzyon kapasitesi, diyafram, hiperbarik oksijen, toksisite

Abstract

Aim: In this retrospective study, we aimed to evaluate the repetitive effects of hyperbaric oxygen treatment on patients' pulmonary functions and diaphragmatic movement.

Patients and Methods: The study group consisted of 22 patients diagnosed with various diseases who were administered hyperbaric oxygen treatment between June 2019 and December 2019. Respiratory functions such as dynamic and static lung volumes, diffusion capacity, and maximum inspiratory and expiratory pressures were evaluated before the start and end of the treatment sessions. Besides, the diaphragm thickness and the diaphragm movements during tidal volume and deep inspiration were measured with thoracic ultrasonography.

Results: Twenty-two patients (16 male;6 female) with a mean age of 53.3±10.0 years were included. At the end of hyperbaric oxygen therapy total lung capacity, vital capacity, and residual volume were significantly increased (p<0.05). The other static lung volumes, maximum inspiratory and expiratory pressures, and diffusing capacity of the lungs for carbon monoxide did not change. The thickness of the diaphragm and diaphragmatic movement during tidal volume and vital capacity were also increased (p<0.05).

Conclusion: In our study, we evaluated the effect of hyperbaric oxygen therapy on diaphragmatic and respiratory functions by using, diffusing capacity, as well as spirometry and diaphragmatic imaging techniques. As a result, hyperbaric oxygen treatment led to a significant change in pulmonary and diaphragmatic functions.

Keywords: Lung, diffusing capacity, diaphragm, hyperbaric oxygen, toxicity

Cite this article as: Sumen SG, Sener Comert S, Caglayan B. How Can Hyperbaric Oxygen Therapy Affect The Diaphragm and Respiratory Functions of The Patients? Selcuk Med J 2023;39(3): 97-103

Disclosure: None of the authors has a financial interest in any of the products, devices, or drugs mentioned in this article. The research was not sponsored by an outside organization. All authors have agreed to allow full access to the primary data and to allow the journal to review the data if requested.



"This article is licensed under a [Creative Commons Attribution-NonCommercial 4.0 International License](https://creativecommons.org/licenses/by-nc/4.0/) (CC BY-NC 4.0)"

INTRODUCTION

Hyperbaric oxygen treatment (HBOT) has been widely preferred as an adjunctive treatment to improve the healing process of many ailments, and therapeutic indications are determined by international medical societies. Hyperbaric oxygen increases tissue oxygenation, improves wound healing, may exert bacteriostatic effect, regulates immune system which is compromised due to the local tissue hypoxia. Treatment is usually applied systemically with the patient inside a pressurized chamber (1-3). Although the clinical practice of hyperbaric oxygen and its scientific basis has proceeded significantly, the clinical use of HBOT is limited due to the low availability of pressurised chambers, problems concerning patient compliance, and belief of high oxidative potential.

HBOT has been accepted as a successful treatment modality with better outcomes in various diseases. Although it has been suggested as a successful tool for the treatment of many ailments, it is also stated that functional changes of some organs may also occur in the long term. The main organs on which temporary or permanent effects have been observed in scientific studies are eye, central nervous system and respiratory system (4).

It is commonly known that oxygen toxicity of the lungs may appear after exposure to oxygen at more than 0.5 ATA (1 ATA: one atmosphere absolute). Toxic effects in the pulmonary system are encountered mostly after long-term or prolonged treatments rather than acute exposures (4,5). Diaphragm muscle is one of the vital anatomical structures that plays significant role in the function of the respiratory system with its neighbor of the tissue. Naturally, it supports breathing function with its mobility in inspiration and expiration. The effect of HBOT on the function of the diaphragm muscle was shown in a few experimental studies (6,7).

Several laboratory tests are commonly used to evaluate the anatomical and functional changes of the tissues in order to determine and follow the possible toxic effects. Pulmonary function tests and ultrasound guided evaluation of diaphragmatic movements related to this issue are considered to be valuable tests with their easy applicability. Additionally, pulmonary function tests are performed and changes are monitored in order to detect the toxic effects of oxygen early in some studies related to the administration of HBOT (8,9).

After searching in the scientific literature, we have noticed that there is not much published clinical

research regarding effects of the HBOT on respiratory and diaphragm functions. Therefore, we aimed to evaluate the cumulative effects of the daily HBOT on pulmonary functions and diaphragmatic movement in this study.

PATIENTS AND METHODS

The study group consisted of 22 patients who are above 17 years and underwent HBOT for various diseases between June 2019 and December 2019. None of these patients had risk enhancers for oxygen toxicity and history of previous lung disease. Exclusion criteria included pregnancy, previous HBOT within one year prior to inclusion, ear disease, claustrophobia, pulmonary disease, active smoking and contraindication for HBOT.

The patients were mostly diagnosed with the delayed wound healing problems from different causes. Patients who had radiological image of chest and lung function at the start of the study participated to the study. The study was approved by the medical ethics committee of the hospital (06.12.2019-2019/514/167/14). Informed consent was obtained from the participants after comprehensive explanation of the study. They all agreed to participate the study and signed the written informed consent. The procedures followed were in accordance with the ethical standards of the responsible committee on human experimentation (institutional or regional) and with the Helsinki Declaration of 1975, as revised in 2000.

Patients underwent hyperbaric oxygen treatment at 2.4 ATA for routine sessions in the multiplace chamber for twelve patients (Zyron 12 multiplace MLT 09, Hipertech). The treatment protocol consisted of 90 minutes of oxygen in three 30-minute periods with a 5-minute air breaks, 5 times a week. Patients breathed 100 % of oxygen via a mask during the therapy. All measurements were repeated by the same physician at the start and end of series of therapy administered for each medical indication (over more than 10 consecutive sessions). A number of total sessions per patient ranged from 10 to 60 consecutive treatments depending on the diagnosis of disease.

The dynamic and static lung volumes, diffusion capacity as well as the maximum inspiratory and expiratory pressures (MIP and MEP) were evaluated. Besides, the diaphragm thickness, as well as the diaphragm movements during tidal volume and deep inspiration, were measured with thoracic ultrasonography by a pulmonary medicine specialist

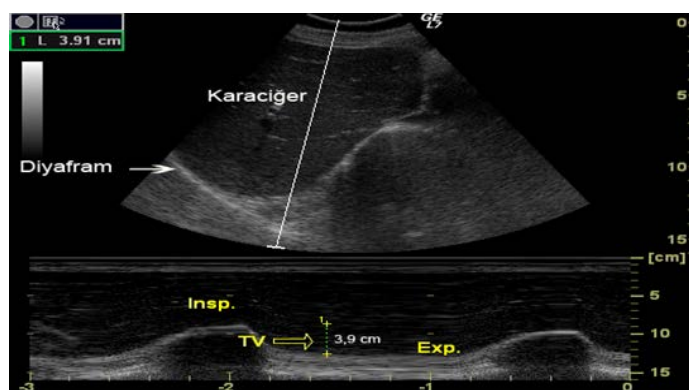
well trained in thoracic ultrasonography, before and after the HBOT consecutive sessions. The average of the three acceptable measurements was used.

The chest physician who had been trained by a radiologist and had taken the course regarding thoracic ultrasonography performed the thoracic ultrasonography. GE Logic 7 ultrasound device with 3.5 MHz convex probe was used for sonographic examination. In the clinical practice, thoracic Ultrasound can be used to investigate the chest wall structures, position, morphology and the position of diaphragm thickness and the lung parenchyma. M-mode US may be used to measure the direction of diaphragmatic motion and the amplitude of excursion. The diaphragm is a good reflector for the sound waves. It is seen as Ultrasonographic bright white and thin echogenic band. Vertical movement of the diaphragm during respiration can be measured by M-mode ultrasonography. By using the subcostal approach in the supine position, both diaphragms can easily be seen from the acoustic diaphragm window created by the spleen, liver on the right and left. On the right side of the patient, by using the subcostal approach, the probe is placed between the midclavicular line and the front axillary line by directing it into medial, posterior and cranial. After seeing the diaphragm on top of the liver dome, it is possible to see the movement of the diaphragm during the tidal volume or deep inspiration from M-mod sections that they have been taken previously (Figure 1).

Data were statistically analyzed using SPSS software version (17.0). Continuous data were expressed as means±standard deviations. The normal distribution for all variables was tested using the Kolmogorov-Smirnov test. Categorical data were expressed in numbers and percentages and compared by chi square tests. Univariate analysis was performed using Mann-Witney U test to identify significant variables ($p<0.05$).

RESULTS

This study consisted of 22 cases, including 16 males and 6 females with the mean age of 53.3 ± 10.0 years. Patients were treated for different indications as follows; 11 patients (50%) wound healing problem, 3 patients (14%) avascular necrosis, 2 patients (9%) osteomyelitis, 6 patients (27%) acute idiopathic hearing loss. As a result, we have found out that the lung volumes such as total lung capacity, residual volume and vital capacity increased significantly ($p<0.05$). We have also noticed that other static lung volumes,



Karaciğer: Liver, Diyafam: Diaphragm

Figure 1. Measurement of diaphragm movement in M-mode during tidal volume

MIP, MEP, and DLCO remained the same ($p>0.05$) as an outcome of the study. Interestingly, there was a significant increase in the thickness of the diaphragm, and diaphragmatic mobility during tidal volume and deep inspiration in the median for the post-treatment ($p<0.05$). Measurement results were significantly greater than pretreatment values.

Of all the indices of pulmonary mechanical and gas exchange function that were measured before and after HBOT, treatment periods are presented in Table 1. And values which were measured statistically significant is also presented in Table 2.

DISCUSSION

There may be different causes of tissue hypoxia such as vascular compromise, heavy infection burden, deep anemia resulted from chronic disease and acute or chronic toxic inhaled gases. Despite surgical and traditional medical treatment approaches, adequate tissue healing may not be achieved. The presence of facilitating factors such as infection, necrosis, foreign material and ischemia in the tissue can delay wound healing. As these factors limit oxygen delivery to the wound bed, the most striking way to reverse the limitations goes through correcting deficiency in the tissue. Therefore, it may be necessary to improve tissue oxygenation, and interdisciplinary approach is a must to cure the ailments. (1,2)

Tissue oxygenation is crucial for sustaining life and the management of wide range of medical conditions. Therefore systemic oxygen administration is widely used as a drug to increase the partial pressure of oxygen in the tissue in order to repair the tissue damage in many diseases due to the lack of efficient

Table 1. The results of measurements of pulmonary function before and after HBOT period.

	Before HBOT		After HBOT		P value
	Mean	Std. Deviation	Mean	Std. Deviation	
FVC (ml)	3767	1041	3805	1069	>0.05
FVC %	101,2	16,96	102,2	18,79	>0.05
FEV1(ml)	2955	878	2939	776	>0.05
FEV1%	98,1	23,0	96,7	19,4	>0.05
FEV1/FVC	78,5	6,53	77,8	6,55	>0.05
FEF 25-75% (L/seconds)	2,87	1,6	2,74	1,2	>0.05
%FEF25-75%	85,4	49,22	78,8	33,83	>0.05
DLCO (mlCO/min/mm)	24,18	5,94	24,90	8,77	>0.05
DLCO%	91,2	24,1	94,0	35,4	>0.05
MIP (cmH ₂ O)	113,4	43,0	87,5	6,36	>0.05
MIP%	101,1	30,0	95,4	36,6	>0.05
MEP (cmH ₂ O)	108,7	31,5	105,5	10,6	>0.05
MEP%	112,5	43,4	108,3	34,7	>0.05
TLC (ml)	7492	3677	7906	4131	<0.05
TLC%	127,0	59,4	133,6	75,3	<0.05
VC (ml)	3767	1041	4858	1006	<0.05
VC%	98,3	15,6	108,0	16,5	<0.05
RV (ml)	4140	3459	4452	3693	<0.05
RV%	211,2	181,7	224,9	201,5	<0.05
FRC (ml)	5322	3546	5685	4014	>0.05
FRC %	169,9	110,9	172,7	137,0	>0.05

DLCO: Diffusing capacity of the lungs for carbon monoxide, FEF25-75%: Forced expiratory flow over the middle one-half of the forced vital capacity, FEV1: Forced expiratory volume exhaled in the first second, FVC: Forced vital capacity, FEV1/FVC: FEV1/FVC ratio, FRC: Functional residual capacity, HBOT: Hyperbaric oxygen treatment, MEP: Maximal expiratory pressure, MIP: Maximal inspiratory pressure, RV: Residual volume, TLC: Total lung capacity, VC: Vital capacity

oxygenation. As a result, adequate oxygenation acting as a nutrient, antibiotic and therapeutic agent enables difficult untreatable health problems to be effectively and safely solved (10). Therefore, HBOT the reference treatment modality in order to repair the damage caused by hypoxia accelerates the healing process in the tissue.

Hyperbaric oxygen therapy is defined as the treatment modality and a curative tool by the application of 100 % oxygen at pressures above one atmosphere absolute (1 ATA = 101.3 kPa). HBOT is delivered using either monoplace or multiplace hyperbaric chamber which is filled with air and systemic oxygen is delivered by mask, hood or anesthetic circuit as needed (11,12). It has been mostly applied in the

treatment of both acute and chronic ischemia/hypoxia-related diseases including decompression sickness, carbon monoxide poisoning, compromised flaps and grafts, sudden sensorineural hearing loss, radiation tissue damage, crush injury, diabetic foot ulcer, thermal burns, necrotising soft tissue infections and others in compliance with the indication's guideline for HBOT in worldwide (13-18). As it is stated in the literature we applied hyperbaric oxygen treatment for the various indications in accordance with the scientific background.

It has been reported that partial oxygen level in difficult to healing wounds has been in the range of 5 to 20 mm Hg, compared with 35 to 50 mm Hg measured in normal tissue (19). The increased partial pressure

Table 2. Results of the thickness of the diaphragm, and diaphragmatic mobility during tidal volume and deep inspiration in the median for the post-treatment

	Before HBOT	After HBOT	P value
Diaphragmatic thickness	0.77±0.26	1.08±0.24	0.026
Diaphragmatic mobility during tidal volume	1.49±0.54	1.97±0.54	<0.01
Diaphragmatic mobility during deep inspiration	5.29±1.50	8.14±1.59	<0.01

The value of p < 0.05 shows statistically significant increase in measurements

of oxygen in the tissue plays a critical role in terms of healing power because it helps to accomplish needs for the energy of all cell types including epithelial, cells, myocytes, neurons, endothelial cells, immune cells involved in the treatment period. It is commonly believed that the success of treatment regarding HBOT in chronic wounds is partially relevant to increase in fibroblastic activity, collagen production, angiogenesis, and epithelialization (20-22). HBOT improves neovascularization inducing bone marrow stem/progenitor cells migration, circulation, and settling in the peripheral wound, developing vascular buds (23,24). It is emphasized that HBOT is an effective and safe modality in the management of nonhealing hypoxic wounds and an integral part of the interdisciplinary medical-surgical approach to the patients (25). Larsson and colleagues (26) evaluated potential benefits of hyperbaric oxygen in the treatment of deep postoperative infections in a case series of pediatric patients with neuromuscular spine deformity. They reported that HBOT is a safe and beneficial adjunctive treatment in such complex deep tissue infections with spinal implants in high-risk pediatric patients.

Apart from the therapeutical effects of the oxygen, there may have been some side effects affecting mostly ears, eyes, lungs and brain in terms of pressure and oxygen reactive substances (27,28). It's also being argued that toxic damage to the pulmonary tissue mostly depends on the dose, application time and individual predisposing risk factors. Toxic effects in the lungs are encountered after long-term treatments rather than acute exposures. The information about the mechanism of how this therapy supports the healing process and side effects are still very limited.

The side effects of hyperbaric oxygen treatment is a striking issue to explore. Discussions of the influence on lung function are so limited that it may cause difficulty to the medical practitioners in terms of the decision to terminate or resume of the treatment. After searching in the literature, we have found only a few articles that may be partially relevant to our study. In 1998, researchers studied pulmonary functions and dynamic lung volumes, forced expiratory flows and the transfer factor of the lung for carbon monoxide (TLCO). The researchers evaluated the results before the hyperbaric oxygen treatment, on first, second, third weeks of the treatment and then 3-4 weeks after treatment. At the end of the therapy series given over 21 consecutive days, there were statistically significant but quantitatively small changes in lung

expiratory function. Although the observed changes were clinically insignificant, they were still present 4 weeks later. There was a progressive reduction in forced expiratory volume in one second (FEV1) ($p < 0.001$), mean forced mid-expiratory flow rate (FEF25-75%) ($p < 0.001$) and forced expiratory flows at 50 and 75% of forced vital capacity (FVC) expired during hyperbaric oxygen treatment. Four weeks after treatment there was a partial normalization. TLCO was slightly reduced on day 21 of treatment only ($p < 0.01$) and fully normalized one month later. In this study with intermittent exposure to hyperoxia, some pattern of changes in pulmonary function took place without any changes in vital capacity. The reduction in pulmonary function after three weeks of HBOT is not considered (29). In another study conducted by Pott and colleagues (30) in 1999, they have investigated the effects of HBOT on pulmonary functions of 14 patients treated in a monoplace chamber. Patients underwent 30 daily sessions at 2,4 ATA and oxygen was breathed freely and continuously inside the chamber. Although the patients were smokers and had an average carbon monoxide diffusing capacity that was 81% of a normal reference population, it was reported that pulmonary function parameters remained unchanged and stated that the HBOT protocol is safe even in lungs with a reduced diffusing capacity as a result.

Apart from the above-mentioned studies, another group of researchers, Plafki and colleagues (31) investigated the complications and side effects of Hyperbaric oxygen in a research of 782 treated patients. 10 of 172 patients in this group were screened out due to pulmonary irregularities. As a conclusion, the researchers reported that after prolonged HBOT sessions none of the group means revealed a significant reduction in pulmonary function values.

In recent years, Hadanny and et al (9) conducted a prospective cohort study and evaluated the effect of hyperbaric oxygen therapy on pulmonary functions. Researchers showed that there were no significant changes in FEV1, FEV1/FVC ratio and FEF25-75%. According to the researchers the increase in FVC and PEF was statistically significant with a 0.014 and 0.001 respectively. They concluded that HBOT protocol which was scheduled for 60 daily sessions at 2 ATA is safe.

In our study, findings show that some lung volumes may slightly change and increase may be significant. But it is not clear to explain how it happens and what

may cause such changes. Apart from that, static lung volumes and other test results remained same and results showed in accordance with the previous studies.

Related to the proper function of the respiratory system, diaphragm muscle with its mobility plays a significant role in the phases of respiration such as inspiration and expiration. In previous studies, there is a lack of sufficient information regarding the effect of HBOT in the function of diaphragm. Only limited experimental studies evaluated a few functions of the diaphragm. In an experimental study, researchers evaluated the effects of HBOT on the function of the diaphragm muscle of animals following medulla spinalis injury. According to the authors HBOT showed protective effect after the injury (6). Another study showed that it did not increase metabolic enzyme activity of the diaphragm muscle in healthy rabbits (7). Although the changes in the thickness of the diaphragm, and diaphragmatic mobility can be result from various causes, there is a slight probability of explanation with the increase dynamic lung volumes.

CONCLUSION

In our study, we evaluated the effect of daily hyperbaric oxygen therapy on diaphragmatic and respiratory functions by using, diffusing capacity, as well as spirometric and diaphragmatic imaging techniques. As a result, HBOT did not impair the pulmonary and diaphragmatic functions. On the contrary, it may cause an increase in pulmonary and diaphragmatic functions. It is not well known whether this increase is long-lasting with the available data.

The significant increase in the test results of lung capacity, residual volume and vital capacity in our study may of course be due to the positive effect of HBOT on the diaphragm muscle and other auxiliary respiratory muscles. This claim should be studied by the enrolment of high numbers of patients and multicenter studies.

Conflict of interest: Authors declare that there is no conflict of interest between the authors of the article.

Financial conflict of interest: Authors declare that they did not receive any financial support in this study.

Address correspondence to: Selin Gamze Sumen, University of Health Sciences, Hamidiye International Faculty of Medicine, Kartal Dr. Lutfi Kırdar City Hospital, Department of Underwater and Hyperbaric Medicine, Istanbul, Turkey
e-mail: sgsumen@gmail.com

REFERENCES

- Weaver LK. Hyperbaric oxygen in the critically ill. *Crit Care Med* 2011;39(7):1-8.
- Aktaş S, Toklu AS, Yildiz S, et al. Development of underwater and hyperbaric medicine as a medical specialty in Turkey. *Undersea Hyperb Med* 2013;40(1):63-7.
- Çimşit M. Hiperbarik oksijenin fiziksel ve fizyolojik esasları. ed. *Hiperbarik Tıp*. Eflatun yayınevi, Ankara, 2009:23-34.
- Çimşit M. Oksijen toksisitesi. ed. *Hiperbarik Tıp*. Eflatun yayınevi, Ankara, 2009:71-86.
- Camporesi EM. Side effects of hyperbaric oxygen therapy. *Undersea Hyperb Med* 2014;41(3):253-7.
- Smuder AJ, Turner SM, Schuster CM, et al. Hyperbaric oxygen treatment following mid-cervical spinal cord injury preserves diaphragm muscle function. *Int J Mol Sci* 2020 30;21(19):7219.
- Nelson AG, Wolf EG, Hearon CM, et al. Hyperbaric oxygenation treatments and metabolic enzymes in the heart and diaphragm. *Undersea Hyperb Med* 1994;21(2):193-8.
- Ozdemir A, Uzun G, Turker T, et al. Changes in pulmonary function in hyperbaric chamber inside attendants: A case-control study. *Undersea Hyperb Med* 2016;43(7):805-11.
- Hadanny A, Zubari T, Tamir-Adler L, et al. Hyperbaric oxygen therapy effects on pulmonary functions: A prospective cohort study. *BMC Pulm Med* 2019;19(1):148.
- Tandara AA, Mustoe TA. Oxygen in wound healing-more than a nutrient. *World J Surg* 2004;28:294-300.
- Sen S, Sen S. Therapeutic effects of hyperbaric oxygen: Integrated review. *Med Gas Res* 2021;11(1):30-3.
- Thom SR. Hyperbaric oxygen-its mechanisms and efficacy. *Plast Reconstr Surg* 2011;127(Suppl 1):131S-41S.
- Toklu AS, Cimsit M, Yildiz S, et al. Decompression sickness cases treated with recompression therapy between 1963 and 1998 in Turkey: Review of 179 cases. *Undersea Hyperb Med* 2014;41(3):217-21.
- Mirasoglu B, Bagli BS, Aktas S. Hyperbaric oxygen therapy for chronic ulcers in systemic sclerosis - case series. *Int J Dermatol* 2017;56(6):636-40.
- Körpınar S, Alkan Z, Yiğit O, et al. Factors influencing the outcome of idiopathic sudden sensorineural hearing loss treated with hyperbaric oxygen therapy. *Eur Arch Otorhinolaryngol* 2011;268(1):41-7.
- Arslan A. Hyperbaric oxygen therapy in carbon monoxide poisoning in pregnancy: Maternal and fetal outcome. *Am J Emerg Med* 2021;43:41-5.
- Tiaka EK, Papanas N, Manolakis AC, et al. The role of hyperbaric oxygen in the treatment of diabetic foot ulcers. *Angiology* 2012;63(4):302-14.
- Soh CR, Pietrobon R, Freiburger JJ, et al. Hyperbaric oxygen therapy in necrotising soft tissue infections: A study of patients in the United States nationwide inpatient sample. *Intensive Care Med* 2012;38:1143-51.
- Sheffield PJ. Tissue oxygen measurements. In: Davis JC, Hunt TK, editors. *Problem wounds: the role of oxygen*. New York: Elsevier Press;1988:17-52.
- Gill AL, Bell CNA. Hyperbaric oxygen: Its uses, mechanisms of action, and outcomes. *QJM* 2004;97:385-95.
- Cianci P. Advances in the treatment of the diabetic foot: Is there a role for adjunctive hyperbaric oxygen therapy? *Wound Rep Reg* 2004;12:2-10.
- Shah JB. Correction of hypoxia, a critical element for wound

- bed preparation guidelines: TIMEO2 principle of wound bed preparation. *J Am Coll Certif Wound Spec* 2011;3(2):26-32.
23. Sjöberg F, Singer M. The medical use of oxygen: A time for critical reappraisal. *J Intern Med* 2013;274:505-28.
 24. Thom SR. Oxidative stress is fundamental to hyperbaric oxygen therapy. *J Appl Physiol* 2009;106:988-95.
 25. Opasanon S, Pongsapich W, Taweepraditpol S, et al. Clinical effectiveness of hyperbaric oxygen therapy in complex wounds. *J Am Coll Clin Wound Spec* 2015;9 6(1-2):9-13.
 26. Larsson A, Uusijärvi J, Lind F, et al. Hyperbaric oxygen in the treatment of postoperative infections in pediatric patients with neuromuscular spine deformity. *Eur Spine J* 2011;20(12):2217-22.
 27. Eisenbud DE. Oxygen in wound healing. *Clinics in Plastic Surgery* 2012;39(3): 293-310.
 28. Yıldız S, Aktas S, Cimsit M, et al. Seizure incidence in 80,000 patient treatments with hyperbaric oxygen. *Aviat Space Environ Med* 2004;75:992-4.
 29. Thorsen E, Aanderud L, Aasen TB. Effects of a standard hyperbaric oxygen treatment protocol on pulmonary function. *Eur Respir J* 1998;12(6):1442-5.
 30. Pott F, Westergaard P, Mortensen J, et al. Hyperbaric oxygen treatment and pulmonary function. *Undersea Hyperb Med* 1999;26:225-8.
 31. Plafki C, Peters P, Almeling M, et al. Complications and side effects of hyperbaric oxygen therapy. *Aviat Spave Environ Med* 2000;71(2):119-24.

An Overview of The Results of Direct Immunofluorescence in Mucocutaneous Biopsies: Single Center Experience

Mukokutanöz Biyopsilerde Direkt İmmünfloresan Değerlendirme Sonuçlarına Bir Bakış, Tek Merkez Deneyimi

Fahriye Kilinc¹, Ugur Gulper², Ilkay Ozer³, Ibrahim Kilinc⁴

¹Necmettin Erbakan University, Faculty of Medicine, Department of Medical Pathology, Konya, Turkey

²Niğde Ömer Halisdemir University, Training and Research Hospital, Department of Medical Pathology, Niğde, Turkey

³Necmettin Erbakan University, Faculty of Medicine, Department of Dermatology, Konya, Turkey

⁴Necmettin Erbakan University, Faculty of Medicine, Department of Medical Biochemistry, Konya, Turkey

Address correspondence to: Fahriye Kilinc, Necmettin Erbakan University, Faculty of Medicine, Department of Medical Pathology, Konya, Turkey

e-mail: drfahriyek@gmail.com

Geliş Tarihi/Received: 1 June 2023

Kabul Tarihi/Accepted: 20 August 2023

Öz

Amaç: Direkt immünfloresan ve histopatolojik inceleme yapılan cilt/mukoza biyopsilerinin immünfloresan sonuçlarını, histomorfolojik bulgularını, ön tanılarıyla uyumunu karşılaştırmak ve immünfloresan incelemenin diagnostik rolünü değerlendirmek amaçlanmıştır.

Hastalar ve Yöntem: 01 Ocak 2019 – 31 Aralık 2019 tarihleri arasında patoloji laboratuvarına gönderilen toplam 207 hastanın biyopsileri değerlendirildi. Ön tanımlara göre gruplar oluşturuldu, histolojik ve direkt immünfloresan bulgular kaydedildi. SPSS programında Kappa istatistikleri ve McNemar testi kullanıldı. $P < 0.05$ istatistiksel olarak anlamlı kabul edildi.

Bulgular: Direkt immünfloresan sonuçları 115 hastada negatif, 91 hastada pozitif ve bir hastada değerlendirme yapılamamıştı. Büllöz pemfigoidli 44 hastanın 19'unda (%43,2), pemfiguslu 18 hastanın 10'unda (%55,6), lupus eritematozuslu 26/51 (%50,9), liken planuslu 10/15 (%66,7), Henoch Shönlein purpuralı 6/6 (%100), diğer vaskülitler için 37/62 (%59,7) hastada histopatolojik uyum izlenmiştir. Direkt immünfloresan pozitifliği büllöz pemfigoid için 19/19, pemfigus için 10/10, lupus eritematozus için 11/26, liken planus için 2/10, Henoch Shönlein purpurası için 6/6, diğer vaskülitler için 28/37 olguda saptanmıştır ($\kappa = 0.021$).

Sonuç: İmmün aracı dermatolojik hastalıkların tanısında ve vezikülobüllöz hastalıkların ayırıcı tanısında direkt immünfloresan inceleme, klinik ve histolojik bulgulara önemli ölçüde destek olmaktadır.

Anahtar Kelimeler: Direkt immünfloresan, deri, vezikülobüllöz hastalıklar, lupus eritematozus, vaskülit

Abstract

Aim: It was aimed to compare skin/mucosa biopsies performed using direct immunofluorescence and histopathological examination, compliance with the preliminary diagnosis and to evaluate the diagnostic value of immunofluorescence examination.

Patients and Methods: A total of 207 patients' biopsies sent to the pathology laboratory between January 01, 2019 and December 31, 2019 were evaluated. Groups were formed according to the preliminary diagnosis, and histological and direct immunofluorescence findings were recorded. Kappa statistics and McNemar test were used in SPSS program. $P < 0.05$ was considered statistically significant.

Results: Direct immunofluorescence results were negative in 115 patients, positive in 91 patients and could not be evaluated in one patient. Histological agreement was found in 19 of 44 (43.2%) patients with bullous pemphigoid, 10 of 18 (55.6%) with pemphigus, 26/51 (50.9%) with lupus erythematosus, 10/15 (66.7%) with lichen planus, 6/6 (100%) with Henoch Shönlein purpuras and 37/62 (59.7%) with other vasculitides. Direct immunofluorescence positivity was found as 19/19 for bullous pemphigoid, 10/10 for pemphigus, 11/26 for lupus erythematosus, 2/10 for lichen planus, 6/6 for Henoch Shönlein purpura, and 28/37 for other vasculitides ($\kappa = 0.021$).

Conclusion: Direct immunofluorescence examination significantly supports clinical and histopathological findings in the diagnosis of immune mediated dermatologic diseases and in the differential diagnosis of vesiculobullous diseases.

Keywords: Direct immunofluorescence, skin, vesiculobullous diseases, lupus erythematosus, vasculitis

Cite this article as: Kilinc F, Gulper U, Ozer I, Kilinc I. An Overview of The Results of Direct Immunofluorescence in Mucocutaneous Biopsies: Single Center Experience. Selcuk Med J 2023;39(3): 104-113

Disclosure: None of the authors has a financial interest in any of the products, devices, or drugs mentioned in this article. The research was not sponsored by an outside organization. All authors have agreed to allow full access to the primary data and to allow the journal to review the data if requested.



"This article is licensed under a [Creative Commons Attribution-NonCommercial 4.0 International License](https://creativecommons.org/licenses/by-nc/4.0/) (CC BY-NC 4.0)"

INTRODUCTION

The skin is an external organ, so it can be observed in the first place and is easily accessible for biopsy. The diagnosis of de novo skin lesions and systemic autoimmune diseases (such as systemic lupus erythematosus (SLE) and vasculitides) can be established through biopsy. However, histopathology alone may not be sufficient in some cases and the diagnosis may need to be supported by assisting techniques (1). Direct immunofluorescence (DIF) is one of these ancillary methods (2). Historically, Coons developed the immunofluorescence (IF) method with a blue fluorescent compound, beta anthracene in the 1940s, diagnostic immunopathology in dermatopathology started with the definition of the lupus band test in 1963 (3). In 1964, Beutner and Jordon demonstrated circulating antibodies in the serum of pemphigus patients using the indirect immunofluorescence (IIF) method. Thus, the immunofluorescence technique took its place as a method used in the diagnosis and management of various vesiculobullous, autoimmune and connective tissue diseases (4).

DIF is technically a one-step procedure that shows antibodies that bind to antigens on the skin or mucosa in vivo (4). It is used in punch biopsy samples that are taken from the lesional and perilesional areas according to the preliminary clinical diagnosis (5,6). While evaluating the DIF findings, the main analyzed parameters are; the primary site of deposition, type, density, and pattern of immune deposits (2). These parameters gain diagnostic importance especially in diseases with autoimmune separation (4). Studies focusing on the compatibility of DIF results with clinical and histological findings in immune-mediated diseases are generally observed in the literature. However, there are few studies in which DIF examination is evaluated together with clinical and histological findings for immune-mediated diseases and diseases/conditions in the differential diagnosis. We planned to consider the final diagnostic results together in biopsies with DIF inconsistency with clinical findings.

In this study, it was aimed to compare evaluated results of DIF and histopathological examination of mucocutaneous biopsies in about 1 year, and to determine the contribution of DIF to diagnosis. It is hoped that this study will contribute to the literature as the experience of single center.

PATIENTS AND METHODS

After receiving ethics committee approval; skin and mucosa biopsies and immunofluorescent samples sent to the pathology laboratory for routine examination between January 01, 2019 and December 31, 2019 were retrospectively analyzed. For this purpose, clinical preliminary diagnoses were grouped (such as pemphigus, bullous pemphigoid (BP), Duhring's disease, vasculitis, discoid lupus erythematosus (DLE), and lichen planus (LP)), and the main histological findings (such as intraepithelial/subepithelial separation, vasculopathy, clasia, dermal mucin deposition) and DIF results (Presence of immunoglobulin G, M, A, and C3 deposits and positivity patterns, if any) were recorded. Patients' age, gender and lesion localization was also recorded.

Statistical analysis of clinical preliminary diagnoses, histological findings and DIF results were obtained using SPSS software with Kappa statistics and McNemar test. $p < 0.05$ values were considered statistically significant. For the Kappa values: 0.00 – 0.20 indicated mild agreement, 0.21 – 0.40 low agreement, 0.41 – 0.60 moderate agreement, 0.61 – 0.80 significant agreement and 0.81 – 1.00 almost excellent agreement.

RESULTS

A total of 207 patients were included in the study. The youngest patient was 3 yo, and the oldest patient 97 yo. Of all the patients, 88 were male and 119 were female. Biopsy localizations were recorded as feet (7), legs (66), legs and trunk (1), trunk (44), arms (19), arms and legs (1), hands (5), hands and feet (1), neck (3), hairy skin (16), face (23), oral mucosa (19) and lips (2). DIF results were negative in 115 patients and positive in 91 patients, and could not be evaluated in one patient, statistical analysis of DIF results was made except for this patient. Results of the patients characterized by subepithelial separation (Table 1):

Pathologic diagnosis was made as BP in 18 patients with the clinical preliminary diagnosis of BP and all of these patients showed DIF positivity. Subepidermal separation was found in 15 patients, IgG and C3 (7/18), and C3 (7/18) positivity mostly found in the epidermis basal membrane with DIF (Figure 1). Chronic bullous dermatosis of childhood (CBDC) was diagnosed with DIF and histological findings in one patient. BP was ruled out with histological and DIF findings in 13 patients. Results of the patients characterized by intraepithelial separation (Table 2):

There were 8 patients with the clinical primary

Table 1. Clinical preliminary diagnosis, pathological diagnosis, DIF results, immune deposits and histological findings of the patients characterized by pemphigoid group and subepidermal subepithelial separation.

Clinical diagnosis (n)	Pathological diagnosis (n)	DIF (n)	Immune deposition (n)	Histological finding (n)
BP (18)	BP (18)	Positive (18)	At BMZ IgG and C3 linear (6) C3 linear (5) IgM, IgA and C3 linear (2) IgM and C3 linear (1) IgG linear (1) At BMZ C3 linear (1) C3 granular (1) IgG, C3 linear and granular (1)	Subepidermal separation yes (15) Subepidermal separation no (3)
CBDC (1)	CBDC (1)	Positive (1)	At BMZ IgM and IgA linear (1)	Subepidermal separation yes (1)
BP, PV (1)	Differential diagnosis could not be made (1)	Negative (1)		Subepidermal or intraepidermal separation no (1)
BP, LP, LIGAD, Urticaria, Kaposi (7)	Differential diagnosis could not be made (7)	Positive (4) Negative (2) Could not be evaluated (1)	At BMZ C3 (1) PV C3 (2), PV C3 and IgM (1)	Subepidermal separation yes (7): BP, LP distinction could not be made (1/7) Vasculopathy yes (3/7) Ulceration yes (1/7) Could not be differentiated because of DIF negativity (1/7) and failure to evaluate (1/7)
BP, Atopic dermatitis, Prurigo, Duhring's disease, SCLE, Dermatomyositis, Drug eruption, SJS (13)	Prurigo (6) Spongiotic dermatitis (1) Atopic dermatitis (2) Dermatomyositis (1) Drug eruption (1) SJS (1) Subcorneal pustular dermatosis (1)	Positive (2), Negative (4) Positive (1) Negative (2) Negative (1) Negative (1) Negative (1) Negative (1)	PV C3 (1), At BMZ granular C3 (1) PV C3 (1)	Subepidermal separation no (13) Dermal mucin positive (1/13)
CBDC, LIGAD, Strophulus, Nummular dermatitis (4)	Nummular dermatitis (1) Strophulus (3)	Positive (1) Negative (3)	At BMZ partly granular C3 (1)	Spongiotic dermatitis (1) Severe spongiosis (3)
Duhring's disease, Prurigo, Viral eruption, Atopic dermatitis, Psoriasis (8)	Prurigo (2) Spongiotic dermatitis (3) Atopic dermatitis (2) Perivascular dermatitis (1)	Positive (1), Negative (1) Negative (3) Negative (2) Negative (1)	PV sparse fine granular C3 (1)	

DIF: direct immunofluorescence, BP: bullous pemphigoid, CBDC: chronic bullous dermatosis of childhood, PV (clinical diagnosis): pemphigus vulgaris, LIGAD: linear immunoglobulin A dermatosis, SCLE: subacute cutaneous lupus erythematosus, SJS: Stevens-Johnson syndrome, BMZ: basement membrane zone, PV (immune deposition): perivascular.

and pathological diagnosis of PV. While there was suprabasal separation in 6 patients, DIF was positive in all of these patients and intercellular IgG and C3 deposits were found in the epidermis in 4 patients, C3 deposit in 3 patients and intercellular IgA and C3 deposits in the hair follicle epithelium in 1 patient (Figure 2). Subcorneal separation was present and DIF was positive in 2 patients with pemphigus foliaceus (PF). Results of the patients characterized

by LE and LP (Table 3):

The pathological diagnosis was DLE in 22 of 51 patients and histologically DLE compatible findings and dermal mucin deposition were found with Alcian-Blue. Of the 22 patients, DIF was negative in 12 and among the remaining 10 patients, epidermis basal membrane deposits were found with mostly of IgM (Figure 3). Of 51 patients, 3 were diagnosed with subacute cutaneous lupus and 1 with cutaneous

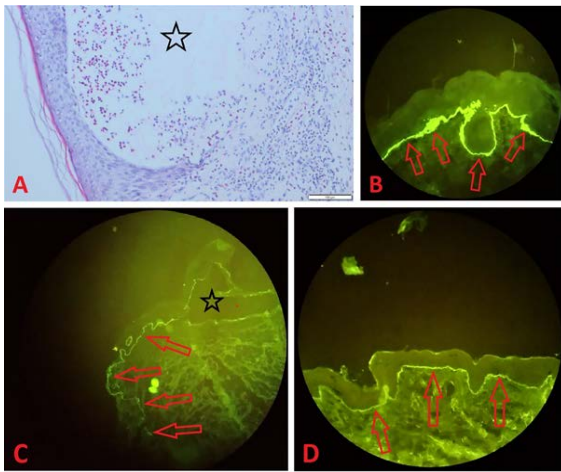


Figure 1. A: Subepidermal separation and bulla formation (star) are seen in the histological section of the skin tissue in the case of bullous pemphigoid (Hematoxylin/Eosin, 100x). B, C, D: Immune deposits are observed in the epidermal basal membrane zone in DIF images of different bullous pemphigoid patients (arrows). B: strong C3, C: moderate C3, D: moderate IgA positivity (There is also subepidermal separation at C (star)).

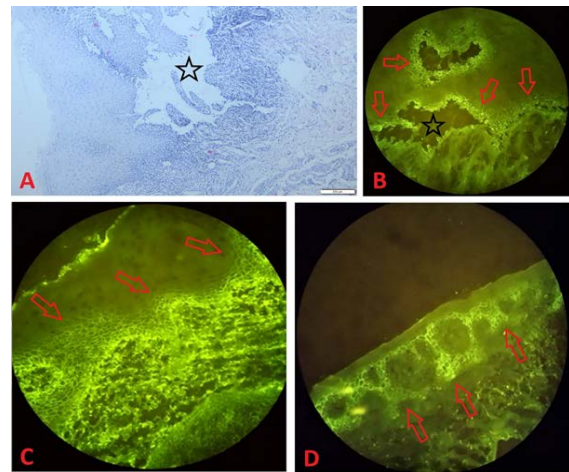


Figure 2. A: In the oral mucosal biopsy of a patient of pemphigus vulgaris, suprabasal separation (star) is observed in the surface epithelium (Hematoxylin/Eosin, 40x). B, C, D: In DIF images of different pemphigus vulgaris patients, intracellular immune deposits are observed in the epithelial lower rows (arrows). B, D: C3 positivity C: IgG positivity. B and C are oral mucosa samples, D is skin biopsy sample (There is also suprabasal separation at B (star)).

Table 2. Clinical preliminary diagnosis, pathological diagnosis, DIF results, immune deposits and histological findings of the patients characterized by pemphigus group and suprabasal intraepithelial separation.

Clinical diagnosis (n)	Pathological diagnosis (n)	DIF (n)	Immune deposition (n)	Histological finding (n)
PV (8)	PV (8)	Positive (8)	Intraepithelial IgG and C3 (3) C3 (3) In hair follicle intraepithelial IgA and C3 (1) Intraepithelial IgG and C3 (1)	Suprabasal separation yes (6) Suprabasal separation no (1) Ulceration yes (1)
PV, Drug reaction, Mucositis, Contact dermatitis, Leukoplakia (3)	PV excluded (3)	Negative (3)		Nondiagnostic (1) Spongiotic dermatitis (1) Ulceration (1)
PF, BP, Duhring's disease, Pemphigus erythematosus (2)	PF (2)	Positive (2)	In spinous layer intercellular IgG and C3 (1) IgG (1)	Subcorneal separation yes (2)
PF, Psoriasis, Seborrheic dermatitis, DLE, PV, AGEP, Subcorneal pustular dermatosis (5)	Psoriasiform spongiotic dermatitis (1) Psoriasis (2) Chronic dermatitis (1) Subcorneal pustular dermatosis (1)	Positive (1) Negative (2) Negative (1) Negative (1)	At BMZ IgM linear (1)	Suprabasal or intraepithelial separation no (5)
Darier's disease, Hailey-Hailey disease, Acanthosis nigricans (3)	Darier's disease (1) Hailey-Hailey disease (2)	Negative (1) Negative (2)		Suprabasal acantholytic separation (1) Suprabasal acantholytic separation (2)

DIF: direct immunofluorescence, PV: pemphigus vulgaris, BP: bullous pemphigoid, PF: pemphigus foliaceus, DLE: discoid lupus erythematosus, AGEP: acute generalized exanthematous pustulosis, BMZ: basement membrane zone.

Table 3. Clinical preliminary diagnosis, pathological diagnosis, DIF results, immune deposits and histological findings of the patients characterized by lupus erythematosus and lichen planus.

Clinical diagnosis (n)	Pathological diagnosis (n)	DIF (n)	Immune deposition (n)	Histological finding (n)
DLE, SCLE, LP, Actinic LP, Cutaneous Lupus, LPP, PLE, Rosacea, Atopic dermatitis, Pityriasis rosea, Dermatitis artefacta (51)	DLE (22)	Positive (10), Negative (12)	At BMZ IgM granular (1), linear (2) C3 granular (2) IgG granular (1) IgM and C3 granular (1) IgM and C3 linear (1) IgM, IgA and C3 linear (1) IgG, IgA and C3 linear (1)	Dermal mucin positive (22)
	SCLE (3)	Negative (3)		Dermal mucin positive (3)
	Cutaneous lupus (1)	Positive (1)	PV C3 (1)	Dermal mucin and vasculopathy positive (1)
	Psoriasis (3)	Positive (1), Negative (2)	At BMZ sparse C3 granular (1)	
	Actinic LP (3), LPP (3), PLE (3), Rosacea (3), Granulomatous inflammation (3), Spongiotic dermatitis (2), Pityriasis rosea (1), Dermatitis artefacta (1), LE, LPP and PLE could not be differentiated (3)	Negative (22)		
LP, Contact dermatitis, SCLE, BP, PV, GVHD, Vasculitis (15)	LP (9)	Positive (2), Negative (7)	At BMZ C3 fine granular (1), PV sparse C3 granular (1)	Lichenoid reaction yes (9)
	LP excluded (3) Ulcer (3)	Negative (3) Negative (3)		Lichenoid reaction no (3) Ulcer, favor of LP (1) Ulcer, favor of lichenoid GVHD (1) Ulcer, no comments for LP (1)

DIF: direct immunofluorescence, DLE: discoid lupus erythematosus, SCLE: subacute cutaneous lupus erythematosus, LP: lichen planus, LPP: lichen planopilaris, PLE: polymorphous light eruption, BP: bullous pemphigoid, PV (clinical diagnosis): pemphigus vulgaris, GVHD: graft versus host disease, BMZ: basement membrane zone, PV (immune deposition): perivascular.

lupus, 1 of which was DIF positive.

Results of the patients characterized by vasculitis were as follows (Table 4, Figure 4):

Six patients with clinical preliminary diagnosis and the pathological diagnosis of HSP were identified. DIF was positive in all patients with histologically detected LCV; perivascular IgA and C3 were found in four patients, IgM, IgA and C3 deposits in 2. The pathological diagnosis was LCV in 23 patients; while histological leukocytoclasia and DIF positivity were found in 17. C3 was the most common with DIF followed by IgA and C3. There were 13 patients diagnosed with vasculopathy, and DIF was negative

in 10. Whereas, the diagnosis of vasculitis was ruled out with histological findings and DIF negativity in 12 cases.

When all patients were evaluated in terms of the subgroups, clinical and histopathological/DIF agreement rates ranged from 0% to 100%. A rate of 0% was found in 8 patients with the primary diagnosis of Dühring's patient, while a 100% rate was observed in 3 patients with the primary diagnosis of Darier disease, Hailey-Hailey disease and 6 patients with the primary diagnosis of HSP. Kappa agreement value between histopathological and DIF results in terms of total cases was mild ($\kappa = 0.021$). $p < 0.001$ value was

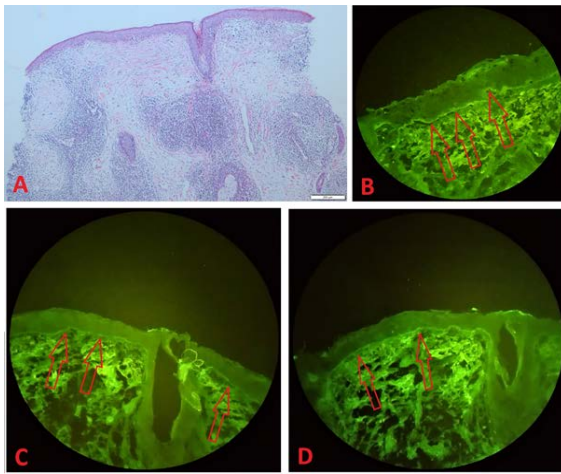


Figure 3. A: Skin biopsy specimen of a discoid lupus erythematosus patient shows flattening of the epidermis, basal vacuolar changes, periadnexal and perivascular lymphocytic infiltration and interstitial mucin deposition in the dermis (Hematoxylin/Eosin, 40x). B, C, D: IgG positivity at B, IgA positivity at C and C3 positivity at D in the epidermis basal membrane zone in the DIF study of the same patient (arrows).

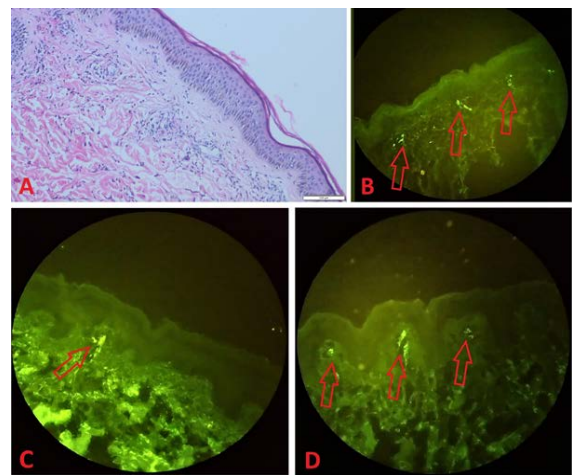


Figure 4. A: In a patient of leukocytoclastic vasculitis, leukocytoclasia and signs of vascular damage with nuclear particles in the dermis are observed (Hematoxylin/Eosin, 100x). B, C, D: Perivascular immune deposits are observed in the upper dermis in different leukocytoclastic vasculitis patients (arrows). C3 positivity at B, IgA positivity at C and D.

Table 4. Clinical preliminary diagnosis, pathological diagnosis, DIF results, immune deposits and histological findings of the patients characterized by vasculitis group.

Clinical diagnosis (n)	Pathological diagnosis (n)	DIF (n)	Immune deposition (n)	Histological finding (n)
HSP (6)	HSP (6)	Positive (6)	PV IgA and C3 (4) IgM, IgA and C3 (1) IgA, C3 and IgM at BMZ and PV (1)	LCV yes (6)
LCV, Drug eruption, PPD, Urticaria, Urticarial vasculitis, PLEVA, Lymphomatoid papulosis, Stasis dermatitis, Livedoid vasculitis, Psoriasis (62)	LCV (23)	Positive (17), Negative (6)	PV C3 (8), IgA (1) IgA and C3 (3) IgM, IgA and C3 (2) IgM and C3 (1) PV and at BMZ C3 (1) IgA and C3 (1)	Leukocytoclasia (23)
	Small vessel vasculitis (6)	Positive (6)	PV C3 (3) IgA and C3 (2), IgM and C3 (1)	
	Lymphocytic vasculitis (4)	Positive (2), Negative (2)	PV C3 (2)	
	Livedoid vasculitis (2)	Positive (2)	PV C3 (1), IgM and C3 (1)	
	Urticarial vasculitis (2)	Positive (1), Negative (1)	PV C3 (1)	
	Vasculopathy (13)	Positive (3), Negative (10)	PV C3 (2), IgM and C3 (1)	
Vasculitis no (12)	Negative (12)			

DIF: direct immunofluorescence, HSP: Henoch Schönlein purpura, LCV: leukocytoclastic vasculitis, PPD: pigmented purpuric dermatosis, PLEVA: pityriasis lichenoides et varioliformis acuta, BMZ: basement membrane zone, PV (immune deposition): perivascular.

found between the histopathology and DIF evaluation with the McNemar test.

DISCUSSION

The DIF test is useful in the diagnosis of autoimmune bullous diseases and in differentiating from histologically similar conditions. Additionally, it can be helpful in addition to clinical and histological findings, in conditions such as connective tissue diseases, vasculitides, LP and occasionally psoriasis (7). Localization of immune complexes, their pattern, presence of inflammatory infiltrate, and types of antibodies are evaluated in the diagnosis of dermatological diseases (8).

In this study, pathologic agreement was observed in 19 (43.2%) of 44 patients with the primary diagnosis of BP, differential diagnosis could not be established in 8 (18.2%) patients and exclusion could be provided in 17 (38.6%) patients. There was no agreement between histological and DIF findings with the primary diagnosis of Dühring's disease. Pathological agreement was obtained in 10 (55.6%) of 18 patients with the primary clinical diagnosis of pemphigus and exclusion was made in 8 (44.4%) patients. Clinical agreement was obtained between histological and DIF findings in 26 (50.9%) patients with the primary diagnosis of LE, pathological diagnosis could not be made in 3 (5.9%) patients and exclusion was made in 22 (43.1%) patients. In the LP group, pathology was consistent in 10 (66.7%) of 15 patients, one patient's (6.7%) biopsy could not be evaluated due to ulceration and LP was excluded in 4 (26.7%) patients. In the vasculitis group, pathological agreement was observed in all 6 patients (100%) for HSP, and 37 (59.7%) of 62 patients with livedoid vasculitis, urticarial vasculitis and their differential diagnoses, especially LCV, in the clinical primary diagnosis were diagnosed as vasculitis, 13 (20.9%) as vasculopathy, while vasculitis was ruled out in 12 (19.4%) patients. Although DIF negativity was observed in 42 patients, the diagnosis was established with histopathological findings (12 DLE, 3 SCLE, 1 dermatomyositis, 7 LP, 6 LCV, 3 vasculitis, 10 vasculopathy). While no histopathological finding was found in 5 patients, the diagnosis was obtained using DIF positivity in these patients (3 BP, 2 PV).

Several studies comparing DIF, clinical and histopathological findings have reported that DIF results were consistent with clinical and histological findings. In a study analyzing 215 biopsies, DIF positivity was found in 103 patients, clinical and

histological agreement was good, and positivity was found by 98.1% in the pemphigus group, 96% in the BP group and 100% in the HSP group. DIF negativity contributed to rule out immune mediated diseases in 110 patients (7). In another study evaluating 204 skin biopsies with 51 being in patients aged between 0 and 14 years, 151 DIF positivities were found, with 132 being consistent with the clinical diagnosis (2). In a study by Lebe et al. (9), histological findings and DIF images were evaluated in 197 cases diagnosed with vesiculobullous dermatitis, and the rates of agreement among clinical and histopathological/DIF diagnoses were close to our results with 58.8% in PV, 53.8% in PF, 37.9% in BP and 5.2% in dermatitis herpetiformis (Dühring's disease). In another study, the concordance of clinical, histological and DIF findings in 92 patients diagnosed with autoimmune bullous dermatosis was evaluated, statistically high agreement was found between clinical, histological and DIF diagnoses for the intraepidermal separation subgroup, and low agreement for the subepidermal separation subgroup (10).

Autoimmune vesiculobullous diseases, like other inflammatory dermatoses, are a morphologically heterogeneous group, and the distinction between various bullous diseases is important for treatment and prognosis. The DIF evaluation is still accepted as the gold standard in the differentiation of these diseases (9). However, for the diagnosis of these diseases, studies have been carried out on the detection of IgG, IgA and complement by immunohistochemical method from formalin-fixed paraffin-embedded blocks in recent years (11).

BP is the most common autoimmune subepidermal bullous disease, and is characterized by antibodies developing against hemidesmosome components in the basal cells of the epidermis (9). These components are mainly BP180 (180kDa) or BPAG2 and BP230 (230kDa) or BPAG1, and are responsible for the adhesion between the epidermis and dermis (12). Clinically characteristic is large serous or hemorrhagic tense blisters on normal or erythematous skin. Histology shows subepidermal separation, mild, moderate, or intense lymphocyte, eosinophil, and/or neutrophil infiltration within the separation and in the dermis (6). In a study conducted to investigate the accuracy of the belief that false negative DIF results may be encountered if the biopsy site is the lower extremity, no difference was found in terms of false negativity in biopsies taken from the trunk, upper extremity and lower extremity (13). With DIF, a linear,

homogeneous deposit of IgG and/or C3 is almost always encountered along the basement membrane zone of the skin around the lesion, oral lesions are present in some cases with IgA deposits (14). In a study by Meijer et al. (15), 277 (91.4%) of 343 patients diagnosed with pemphigoid had IgG, 223 (73.6%) C3c, 83 (27.4%) IgA deposits, while IgG alone was seen in 60 (19.8%), with C3c in 135 (44.6%) with IgA in 20 (6.6%) and combined with C3c and IgA and 62 (20.5%) specimens. In the study of Damman et al. (16), it is reported that in cases where IgG and C3c are negative, detection of C4d with DIF may help in the diagnosis, but it is not a 100% specific BP marker. Consistently with the literature, in our study of 19 patients diagnosed with BP and CBDC, IgG and/or C3 deposits were seen in 15 (78.8%) patients, IgM and IgA deposits in 1 (5.3%) patient, IgM, IgA ve C3 in 2 (10.6%) and IgM and C3 deposits in 1 (5.3%) patient. Immunodeposits were linear in 17 patients, granular in 1 case, linear and granular in 1 patient.

Pemphigus is a rare group of autoimmune bullous diseases affecting the skin and mucous membranes. Autoantibodies (mainly IgG) found on the surface of keratinocytes and formed against desmosome components (especially desmoglein1, Dsg1, or desmoglein3, Dsg3, or both) that are involved in intraepidermal adhesion play a pathogenic role. Acantholysis, vesicles, blisters and erosions develop on the skin and/or mucous membranes because of the loss of intercellular adhesion (17,18). The main pemphigus forms according to clinical and histopathological features include PV, PF, paraneoplastic pemphigus, pemphigus herpetiformis, and IgA pemphigus (17). The diagnosis of PV, PF and IgA pemphigus is based on clinical findings, DIF examination of perilesional biopsy, serology, and histological examination of lesional biopsy (19). Intercellular deposits of IgG, less frequently C3, IgM, and IgA are seen in the epidermis with DIF (14). In a study by Arbache et al. (20), intercellular IgG and C3 deposits were most frequently observed with DIF in 277 patients in the intraepidermal separation disease group. Positivity rates were found as 91.5% and 79.5% for PV, 94%, and 73% for PF, 66%, and 33% for paraneoplastic pemphigus and intercellular IgA deposition 100% for IgA pemphigus. In this study, the DIF positivity was observed in 10 patients with the primary diagnoses of PV and PF. IgG and C3 deposits were found in 5 (50%) patients, C3 deposits in 3 (30%) patients. In one of the DIF-positive patients, immune deposits were in the hair follicle epithelium.

LE is a complex disease and the clinical picture of LE can vary from the form in which only cutaneous lesions are seen, to the form in which skin rashes are accompanied by progressive systemic involvement (21). LE can be clinically classified mainly into systemic (acute), subacute cutaneous and chronic forms (22). Discoid lupus erythematosus (DLE) accounts for 85% of cutaneous LE cases (23). The main histological findings are epidermal atrophy, follicular dilatation, plugging, liquefactive degeneration and basement membrane thickening of the epidermal basal layer, dermal edema, telangiectasia, perivascular and periappendageal lymphocytes, histiocytes, mucin deposition (21). Vasculitic reactions can be seen in 11% of SLE cases (24). Immune deposits of various patterns (homogeneous, granular and reticular) are observed along the dermoepidermal junction with DIF and IgM are most commonly identified (21).

In a study evaluating the histopathological and DIF findings of 75 skin biopsies with DLE, DLE variants, LP-like lesions in the clinical preliminary diagnosis, histopathological characteristic DLE features were found in 60% of the patients and DIF positivity in 68% of the patients. The most common site of accumulation of immunocomplexes with DIF was the dermoepidermal junction (80%), the most commonly found (77%) was IgG deposit, followed by IgM deposit. These deposits were observed alone or along with other Ig's or C3 (23). Elbendary et al. (25) encountered most frequently IgM deposition especially in granular pattern in LE cases at the dermoepidermal junction and stromal-epithelial junction of hair follicles and sweat glands. In this study, 22 (84.6%) of 26 patients with the pathological diagnosis of LE were the patients with DLE. Interface dermatitis and dermal mucin depositions were observed in 26 patients, and vasculopathic changes in 1 patient. DIF positivity was observed in 11 (42.3%) of the 26 patients. Immune deposits were in the epidermis basement membrane zone in 10 (90.9%) patients, and in the dermal perivascular area in 1 (9.1%) patient diagnosed with vasculopathy and cutaneous lupus. The most common immunoglobulin deposit was IgM in 6 (54.5%) patients, alone, with C3, or with IgA and C3.

The term vasculitis refers to a heterogeneous group of disorders characterized by inflammation and damage of blood vessel walls. It may be limited to the skin or some other organs or may be a multisystem disease (14). The clinical signs of vascular damage are seen as edema, livedo reticularis and various hemorrhage findings (such as petechiae, purpura,

ecchymosis) and in the case of severe damage, vascular occlusion may cause ischemia and associated necrosis, gangrene and/or ulceration. The main histological findings are inflammatory cell infiltration and vascular damage (such as fibrinoid necrosis in the vessel wall). Conditions in which inflammation is not observed but vascular damage is seen are considered as vasculopathy (6). In a study evaluating the histopathological and DIF findings of 121 cases diagnosed with cutaneous small vessel vasculitis, it was observed that at least one of IgM, IgG, IgA and C3 were deposited in the perivascular or epidermal basal membrane zone. The most common immune deposit was C3 (53.7%), and the most deposited immunoglobulin was IgA (11.6%) in the perivascular area. IgA positivity was observed in all (100%) patients with HSP (26). In this study, leukocytoclasia was found in 29 (67.4%) and DIF positivity was found in 34 (79.1%) of 43 patients with pathological diagnosis of vasculitis, including HSP. C3 was the most common deposit and was observed in 33 (97.1%) patients either alone or along with immunoglobulin. Immune deposits were observed in the perivascular area in all patients, and additionally in the epidermis basal membrane zone in three patients. The most frequently deposited immunoglobulin was IgA in 15 (44.1%), in all HSP patients (100%) and it was positive in 32.1% of patients diagnosed with vasculitides other than HSP. IgM deposits were observed in 7 (20.6%) patients with 2 having HSP. Immune deposit with IgG was not observed in any patient.

The main limitations of this study are the use of data obtained from archival sources and its retrospective nature. The biopsy results examined in a certain period were analyzed, the follow-up of the cases, the course of the diseases, whether there were any biopsy results before or after them were not examined.

CONCLUSION

The DIF method makes a significant contribution to clinical and histological findings in the diagnosis or exclusion of immunopathological events affecting the skin. In our study, although the kappa fit value was mild between the histopathology and DIF findings, the contribution of DIF stands out, especially in typing of patients with vesiculobullous diseases. It also supports the clinical and histological findings of LE and vasculitis cases. The correlation between clinical and pathological examinations is crucial to

obtain efficient results. It should be kept in mind that there may be false negative or false positive results in the DIF test. A definitive diagnosis can be made by evaluating the DIF and histological findings together. Biopsy localization, lesion age, type of sampling, laboratory stages, and criteria to be considered in the microscopic evaluation process are important points that enable reaching an accurate diagnosis.

Conflict of interest: Authors declare that there is no conflict of interest between the authors of the article.

Financial conflict of interest: Authors declare that they did not receive any financial support in this study.

Address correspondence to: Fahriye Kilinc, Necmettin Erbakan University, Faculty of Medicine, Department of Medical Pathology, Konya, Turkey
e-mail: drfahriyek@gmail.com

REFERENCES

1. Dhanabalan RT, Ramalingam S, Ibrahim SS, et al. The utility of immunofluorescence in diagnosing dermatological lesions and its correlation with clinical and histopathological diagnosis in a tertiary health care setup. *Indian J Dermatopathol Diagn Dermatol* 2016;3:63-70.
2. Minz RW, Chhabra S, Singh S, et al. Direct immunofluorescence of skin biopsy: Perspective of an immunopathologist. *Indian J Dermatol Venereol Leprol* 2010;76(2):150-7.
3. Chhabra S, Minz RW, Saikia B. Immunofluorescence in dermatology. *Indian J Dermatol Venereol Leprol* 2012;78(6):677-91.
4. Shetty VM, Subramaniam K, Rao R. Utility of immunofluorescence in dermatology. *Indian Dermatol Online J* 2017;8(1):1-8.
5. Elston DM, Stratman EJ, Miller SJ. Skin biopsy: Biopsy issues in specific diseases. *J Am Acad Dermatol* 2016;74(1):1-16; quiz 17-8.
6. Busam KJ, Barnhill RL. Laboratory methods. In: Barnhill RL, ed. *Dermatopathology*. 3rd ed. United States: McGraw-Hill Medical; 2010:1024-32.
7. Mysorekar VV, Sumathy TK, Shyam Prasad AL. Role of direct immunofluorescence in dermatological disorders. *Indian Dermatol Online J* 2015;6(3):172-80.
8. Odell ID, Cook D. Immunofluorescence techniques. *J Invest Dermatol* 2013;133(1):e4.
9. Lebe B, Gül Niflioğlu G, Seyrek S, et al. Evaluation of clinical and histopathologic/direct immunofluorescence diagnosis in autoimmune vesiculobullous dermatitis: Utility of direct immunofluorescence. *Turk Patoloji Derg* 2012;28(1):11-6.
10. Tran GH, Le NTA, Dang MH, et al. Concordance of clinical, histologic and direct immunofluorescence findings in patients with autoimmune bullous dermatoses in Vietnam. *Dermatopathology (Basel)* 2023;10(1):30-40.
11. Zhao W, Zhu H, Zhao X, et al. Direct immunofluorescence of IgG on formalin-fixed paraffin-embedded tissue by heat-induced antigen retrieval as a sensitive method for the diagnosis of pemphigus. *Clin Cosmet Investig Dermatol* 2023;16:1233-41.

12. Miyamoto D, Santi CG, Aoki V, et al. Bullous pemphigoid. *An Bras Dermatol* 2019;94(2):133-46.
13. Perry DM, Wilson A, Self S, et al. False-negative rate of direct immunofluorescence on lower extremities in bullous pemphigoid. *Am J Dermatopathol* 2021;43(1):42-4.
14. Weedon D. The vesiculobullous reaction pattern. In: Weedon's Skin Pathology. 3rd ed. China: Churchill Livingstone Elsevier; 2010:123-68.
15. Meijer JM, Diercks GFH, de Lang EWG, et al. Assessment of diagnostic strategy for early recognition of bullous and nonbullous variants of pemphigoid. *JAMA Dermatol* 2019;155(2):158-65.
16. Damman J, Edwards G, van Doorn MB, et al. Diagnostic utility of C4d by direct immunofluorescence in bullous pemphigoid. *Am J Dermatopathol* 2021;43(10):727-9.
17. Porro AM, Seque CA, Ferreira MCC, et al. Pemphigus vulgaris. *An Bras Dermatol* 2019;94(3):264-78.
18. Egami S, Yamagami J, Amagai M. Autoimmune bullous skin diseases, pemphigus and pemphigoid. *J Allergy Clin Immunol* 2020;145(4):1031-47.
19. Schmidt E, Kasperkiewicz M, Joly P. Pemphigus. *Lancet* 2019;394(10201):882-94.
20. Arbache ST, Nogueira TG, Delgado L, et al. Immunofluorescence testing in the diagnosis of autoimmune blistering diseases: Overview of 10-year experience. *An Bras Dermatol* 2014;89(6):885-9.
21. Luzar B, Calonje E. Idiopathic connective tissue disorders. In: Calonje E, ed. *McKee's Pathology of the Skin with Clinical Correlations*. 5th ed. China: Elsevier; 2020:771-825.
22. Hall BJ, Cockerell CJ. *Diagnostic Pathology: Nonneoplastic Dermatopathology*. 2nd ed. Philadelphia: Elsevier, 2016.
23. Bharti S, Dogra S, Saikia B, et al. Immunofluorescence profile of discoid lupus erythematosus. *Indian J Pathol Microbiol* 2015;58(4):479-82.
24. Micheletti RG. Cutaneous vasculitis in rheumatologic disease: Current concepts of skin and systemic manifestations. *Clin Dermatol* 2018;36(4):561-6.
25. Elbendary A, Zhou C, Valdebran M, et al. Specificity of granular IgM deposition in folliculosebaceous units and sweat gland apparatus in direct immunofluorescence (DIF) of lupus erythematosus. *J Am Acad Dermatol* 2016;75(2):404-9.
26. Oltulu P, Ugur A, Ozer I, et al. Direct immunofluorescence (Dif) microscopy in cutaneous small vessel vasculitis: A single institution experiences. *Med J SDU* 2018;25(2):176-84.

The Efficacy of Interfacial Plan Block Procedures on Postoperative Satisfaction of Surgeons: A Survey Study

İnterfasiyal Plan Blok Uygulamalarının Cerrahların Postoperatif Memnuniyeti Üzerindeki Etkisi: Anket Çalışması

Selcuk Alver¹



¹Istanbul Medipol University, Department of Anesthesiology and Reanimation, Istanbul, Turkey

Address correspondence to: Selcuk Alver, Istanbul Medipol University, Department of Anesthesiology and Reanimation, Istanbul, Turkey
e-mail: selcukalver@yahoo.com

Geliş Tarihi/Received: 4 July 2023
Kabul Tarihi/Accepted: 16 August 2023

Öz

Amaç: İnterfasiyal plan blokları (İFPB) postoperatif dönemde multimodal analjezinin bir parçası olarak kullanılabilir. İFPB'nin postoperatif dönemde analjezik etkinliği, hastaların ve cerrahların memnuniyetini artırabilir. Anket çalışmaları anesteziyoloji araştırmalarında uzun yıllardır kullanılmaktadır. Bu anket çalışmasında cerrahi ekibin memnuniyet düzeyini araştırmayı amaçladık.

Gereçler ve Yöntem: Çalışma 1 Mayıs 2023 ve 31 Mayıs 2023 tarihleri arasında gerçekleştirildi. Anketimiz 450 uygulayıcıya telefon veya e-posta yoluyla gönderildi ve 30 gün içinde alınan yanıtlar çalışmaya dahil edildi. Yirmi yedi uygulayıcı anketi tamamlamadığı için çalışma dışı bırakıldı.

Bulgular: 423 anketin cevapları geçerli cevaplar kabul edildi. Katılımcılara İFPB hakkında bilgileri soruldu ve cevaplar şu şekildedeydi: 393'ünün İFPB hakkında bilgi sahibiydi. (%92,9). 360 katılımcı İFPB'nin, işlemin postoperatif analjezik tüketimini azalttığını (%85,1) bildirdi. 338 katılımcı İFPB'nin hasta takiplerine katkıda bulunduğunu bildirdi. (%80).

Sonuç: Bulgularımız cerrahi ekibin memnuniyet düzeyinin yüksek olduğunu ve cerrahların ameliyat olan hastaları için İFPB yapmak için anesteziyenin talepte bulduklarını göstermektedir.

Anahtar Kelimeler: Postoperatif ağrı, interfasiyal plan blokları, memnuniyet, cerrahlar, anket çalışması

Abstract

Aim: Interfascial plane blocks (IFPB) can be used as part of multimodal analgesia in the postoperative period. The analgesic efficacy in the postoperative period of IFPB may increase the satisfaction of patients and surgeons. Survey studies have been used for many years in anesthesiology research. In this survey study, we aimed to investigate the satisfaction level of the surgical team.

Materials and Methods: The study was carried out between 1 May 2023 and 31 May 2023. Our survey was sent to 450 practitioners via telephone or email, and responses received within 30 days were included in the study. Twenty seven practitioners had not completed the questionnaire.

Results: 423 answers from practitioners were considered to be valid responses. Participants were asked knowledge about IFPB, and answering as follows: 393 have heard about IFPB (92,9%). 360 participants reported that the IFPB, procedure reduced postoperative analgesic consumption (85,1%). 338 participants reported that the IFPB, procedure contributed to their patient follow-ups (80%).

Conclusion: Our results show that the satisfaction level of the surgical team is high and the surgeons request from anesthesia to perform IFPB for their patients who underwent surgery.

Keywords: Postoperative pain, interfascial plane blocks, satisfaction, surgeons, survey study

Cite this article as: Alver S. The Efficacy of Interfacial Plan Block Procedures on Postoperative Satisfaction of Surgeons: A Survey Study. Selcuk Med J 2023;39(3): 114-121

Disclosure: Author has not a financial interest in any of the products, devices, or drugs mentioned in this article. The research was not sponsored by an outside organization. Author has agreed to allow full access to the primary data and to allow the journal to review the data if requested.



"This article is licensed under a [Creative Commons Attribution-NonCommercial 4.0 International License](https://creativecommons.org/licenses/by-nc/4.0/) (CC BY-NC 4.0)"

INTRODUCTION

Postoperative pain is acute pain and it is occurred by the inflammatory process due to surgical trauma and decreases with the tissue healing. Pain in the postoperative period is a serious problem that reduces patient comfort and delays the patient's return to work after surgery (1). Inadequate treatment of pain leads to complications such as respiratory depression, delayed mobilization, and prolonged hospital stays. Successful postoperative analgesia prevents these undesirable effects (2).

Thanks to the use of ultrasound (US) in regional anesthesia applications, the popularity and usage of interfascial plane blocks (IFPB) have increased nowadays (3). The clinicians can perform several IFPBs from the thoracic wall to the back according to the surgical area. Anterior and lateral thoracic wall blocks (pectoral blocks, and serratus anterior plane block), posterior abdominal wall and thoracolumbar plane blocks (quadratus lumborum block – QLB, thoracolumbar interfascial plane block – TLIP), and peri-paravertebral blocks (erector spinae plane block – ESPB, rhomboid intercostal block - RIB) have been commonly used and many papers have been published about the analgesic efficacy of them (4,5,6,7).

Interfascial plane blocks (IFPB) can be used as part of multimodal analgesia in the postoperative period. The use of IFPB is simple and safe due to the US-guidance (8). Clinicians can use IFPB as the sole anesthetic method in high-risk patients (9). Since the effective analgesic efficacy, IFPB may be an opioid-sparing strategy. Simple visualizing of the sonoanatomy and the spread of the local anesthetic under US-guidance are the most important factors in the widespread use of IFPB (7,8). The analgesic efficacy in the postoperative period of IFPB may increase the satisfaction of patients and surgeons (10-13). Survey studies have been used for many years in anesthesiology research. There is no survey study that evaluates the level of surgical satisfaction with the IFPB in the literature.

In this survey study, we aimed to investigate the satisfaction of surgical teams in terms of IFPB applications in surgical clinics in Turkey. We objectively evaluated the advantages and disadvantages of IFPB, and for which operations IFPB is mostly used.

MATERIALS AND METHODS

Compliance with Ethical Standards

Approval was obtained from Istanbul Medipol

University Ethics and Research Committee for this survey study (13.04.2023, Decision no: 371).

Study Design

After ethical approval, the survey questions were prepared by considering the IFPB that is commonly performed by anesthesiologists. The study is a cross-sectional type study and a questionnaire form created electronically (Google Forms) was used to collect data. In order to determine the study universe prior to the dissemination of the questionnaire, anesthesiologists who routinely applied the fascial plane block in their clinical practices were reached with the help of the Regional Anesthesia Society. Afterward, the questionnaire form was sent to the surgeons they worked with via e-mail and WhatsApp. Questions were directed to the participants between 1 May and 31 May 2023. An informative letter about the purpose and nature of the survey is given to the participants in the introduction of the questionnaire. A total of 21 questions were asked of the participants in the survey. A total of 450 surgeons were delivered a questionnaire and the data obtained from the questionnaire forms of 423 participants who completed the questionnaires completely within the specified date range were analyzed.

We prepared the questions according to the most commonly performed surgeries in Turkey. The survey includes 21 questions. We prepared the questions according to the following issues; information and consent, fear-anxiety, pain score, complications, disturbed behavior, trust, willingness to be applied again, and satisfaction criteria. The questions were determined by the consensus of the authors (8,10,11).

The Inclusion Criteria

Surgeons who perform surgery actively were included in the study.

The Exclusion Criteria

Answering the survey questions incompletely and not desiring to participate in the study were determined to be exclusion criteria.

Questions about neuraxial and peripheral nerve blocks were excluded.

Survey Questions Content

There are no limitations in terms of age and education status in the survey questions. The participants were asked to detail the working duration of the surgical service and the departments they most commonly worked in the surgical branch. In addition, they were questioned about IFPB procedures, at which stage of their procedures they want IFPB (preemptive or postoperative), the advantages and disadvantages

of IFPB, and unwanted applications in the procedures. The surgical team was also questioned about the contribution of IFPB procedures to patient follow-up and recovery in the postoperative period. Thus, at which stages of the operation the IFPB is used and the advantages and disadvantages of this application in operations have been determined. The survey questions are detailed in (Table 1).

Statistical Analyses

The pooled data were evaluated using the SPSS 22.0 statistical program (IBM Corp., Armonk, NY, USA). Frequency distributions were calculated and presented as numbers and percentages.

RESULTS

Our survey was sent to 450 practitioners via telephone or email, and responses received within 30 days were included in the study. Because it was determined that 27 practitioners had not completed the questionnaire, 423 answers were considered to be valid responses.

There were 283 male (66,9%) and 140 female participants. The experience range of 25,5% of the participants was under 5 years, making up a majority of participants in our survey. Among the practitioners, 51 were professors (12.1%), 96 were associate professors (22,7%), 66 were assistant professors (15,6%), 102 were specialist doctors (24,1%), and 108 were resident doctors (25,5%). Also among the practitioners, 108 were general surgeons (25,5%), 63

were neurosurgeons (14,8%), 48 were gynecology and obstetrics surgeons (11,4%), 82 were orthopedics and traumatology surgeons (19,3%), 60 were thoracic surgeons (14,1%), 17 were plastic and reconstructive surgeons (4%), 45 were cardiovascular surgeons (10,6%). In addition, 245 general practitioners were affiliated with university hospitals (57.9%), 162 were affiliated with tertiary hospitals (38.3%), and 16 were affiliated with secondary level hospitals (Table 2).

Participants were asked about their knowledge of IFPB and answered as follows: 393 of them have heard about IFPB (92,9%) and 30 had never (7,1%). 378 of the participants are performing IFPB currently in their hospitals (89.3%), 25 of them are not performing IFPB currently in their hospitals (5,9%) meanwhile 20 of them had no idea about performing IFPB currently in their hospital (4,7%). 326 participants would like their patients to have facial plane blocks routinely done (77%), 39 participants would not like their patients to have facial plane blocks routinely done (9,2%) and 58 of them had no idea (13,7%). 333 participants were given sufficient information about IFPB by the practitioner (78,7%), 39 participants weren't given sufficient information about IFPB by the practitioner (9,2%), and 51 of them had no idea (12,1%) (Table 3).

Participants were asked about the clinical impact, follow-up, satisfaction, complications, and disruptive behaviors related to IFPB and responded as follows: 360 participants reported that the IFPB procedure

Table 1. Survey questions

QUESTIONS
Gender?
Education Status?
Total length of professional service?
What is your specialty?
The organization/affiliation you are currently working for?
Do you know what IFPB is / Have you ever heard about IFPB? (Anesthesia information)
Is IFPB performed to your patients currently in your hospital? (Anesthesia information)
Would you like your patients to have facial plane blocks routinely done? (Satisfied)
Has sufficient information been provided by the practitioner about the IFPB? (Information)
Which of your cases need IFPB the most? (Anesthesia information)
Have IFPB procedure reduced the postoperative analgesic consumption? (Satisfaction)
Have the IFPB procedure contributed to your patient follow-ups? (Satisfaction)
Have you ever been asked if your patient suffers from pain while in the postoperative recovery room after the IFPB? (Satisfaction)
Do you have any worries about IFPB before the procedure? (Worry-anxiety)
Were there any applications that you were worried about during the IFPB procedure? (Disruptive behavior)
Do you trust the anesthesia team during the IFPB procedure? (Trust)
Were there any complications after the IFPB procedure? (Complication)
If you had surgery, would you like to be performed IFPB to yourself? (Request)
When do you prefer the IFPB procedure?
What are the disadvantages of IFPB procedure?
What are the advantages of IFPB procedure?

Table 2. Demographic Data

n:423		n	%
Gender	Male	283	66,9%
	Female	140	33,1%
Title	Resident	108	25,5%
	Specialist	102	24,1%
	Assistant professor	66	15,6%
	Associate professor	96	22,7%
	Professor	51	12,1%
Experience (year)	<5	108	25,5%
	6-10	72	17%
	11-15	99	23,4%
	16-20	84	19,8%
	>21	60	14,1%
Specialty	General Surgery	108	25,5%
	Neurosurgery	63	14,8%
	Gynecology and Obstetrics	48	11,4%
	Orthopedics and traumatology	82	19,3%
	Thoracic Surgery	60	14,1%
	Plastic and reconstructive surgery	17	4%
	Cardiovascular surgery	45	10,6%
Organization/affiliation	University Hospital	245	57,9%
	Tertiary hospital	162	38,3%
	Secondary hospital	16	3,7%

Table 3. Knowledge about IFPB

n:423		n	%
Do you know what IFPB is / Have you ever heard about IFPB?	Yes	393	92,9%
	No	30	7,1%
Is IFPB performed to your patients currently in your hospital?	Yes	378	89,3%
	No	25	5,9%
	No idea	20	4,7%
Would you like your patients to have facial plane blocks routinely done?	Yes	326	77%
	No	39	9,2%
	No idea	58	13,7%
Has sufficient information been provided by the practitioner about the IFPB?	Yes	333	78,7%
	No	39	9,2%
	No idea	51	12,1%

reduced postoperative analgesic consumption (85,1%), 51 participants reported that the IFPB procedure didn't reduce postoperative analgesic consumption (12%), 12 of them had no idea (2,8%). 338 participants reported that the IFPB procedure contributed to their patient follow-ups (80%), 22 participants reported that the IFPB procedure didn't contribute to their patient follow-ups (5%), and 63 of them had no idea (15%). 322 participants had been asked if their patient suffers from pain while in the postoperative recovery room after the IFPB (76,4%), 89 participants hadn't been asked (12%) and 12 of them had no idea (2,8%). 84 participants had worries about IFPB before the procedure (19,8%),

280 participants hadn't any worries (66,1%) and 59 of them had no idea (13,9%). 376 participants trusted the anesthesia team during the IFPB procedure (88,8%), 3 participants didn't trust (0,7%) and 44 of them had no idea (10,1%). 4 participants had complications after the IFPB procedure (0,09%), 378 participants hadn't any complications after the IFPB procedure (89,4%) and 41 of them had no idea (9,7%). The most frequently reported complication was a hematoma. 319 participants would prefer IFPB if they had surgery (75,4%), 15 participants wouldn't prefer it (3,5%) and 89 of them had no idea (21%) (Table 4).

Practitioners were asked, "When do you prefer the IFPB procedure?" responded to multiple options as

Table 4. Clinical Effect, Follow-up, Satisfaction, Complications and Disruptive Behavior

n:423	n	%	
Have IFPB procedure reduced the postoperative analgesic consumption?	Yes	360	85,1%
	No	51	12 %
	No idea	12	2,8%
Have the IFPB procedure contributed to your patient follow-ups?	Yes	338	80%
	No	22	5%
	No idea	63	15%
Have you ever been asked if your patient suffers from pain while in the postoperative recovery room after the IFPB?	Yes	322	76,4%
	No	89	21,4%
	No idea	12	2,8 %
Do you have any worries about IFPB before the procedure?	Yes	84	19,8%
	No	280	66,1%
	No idea	59	13,9%
Were there any applications that you were worried about during the IFPB procedure?	Yes	355	83,6%
	No	24	5,6%
	No idea	44	10,4%
Do you trust the anesthesia team during the IFPB procedure?	Yes	376	88,8%
	No	3	0,7%
	No idea	44	10,1%
Were there any complications after the IFPB procedure?	Yes	4	0,09%
	No	378	89,4%
	No idea	41	9,7%
If you had surgery, would you like to be performed IFPB to yourself?	Yes	319	75,4%
	No	15	3,5%
	No idea	89	21%

follows: 25% in a preoperative block room, 43% after anesthesia induction before surgery, 86% end of the surgery, 27% at PACU and 5% had no idea. (Figure 1A). Practitioners were asked, “Which of your cases need IFPB the most?” responded multiple options as follows: 22,3% breast surgery, 30,2% laparoscopic abdomen surgery, 22,1% laparotomy abdomen surgery, 27,3% spine surgery, 15,1% vats surgery, 18% thoracotomy surgery, 16,5% knee surgery, 19,4% hip surgery, 11,5% open heart, 16,5% transplant surgery, 6,5% robotic surgery, 6,5% urogenital surgery, 7,9% breast surgery, (Figure 1B).

Practitioners were asked, “What are the advantages of the IFPB procedure?” responded to multiple options as follows: 87.9 % reduced analgesia, 70% early recovery, 60,7% early discharge, 63,6% early mobilization, 75% patient satisfaction, 20,7% reduced thromboembolic event, 18,6% less chronic pain and 3,6 % had no idea. (Figure 2A).

Practitioners were asked, “What are the disadvantages of the IFPB procedure?” responded

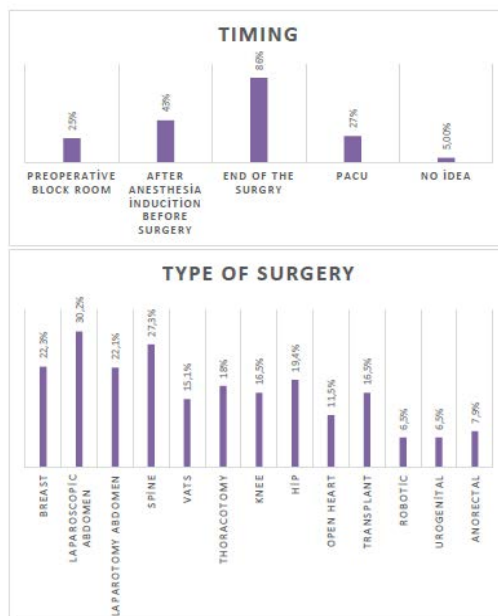


Figure 1A.-1B. Graphics of Timing and Indications of IFPB Procedure

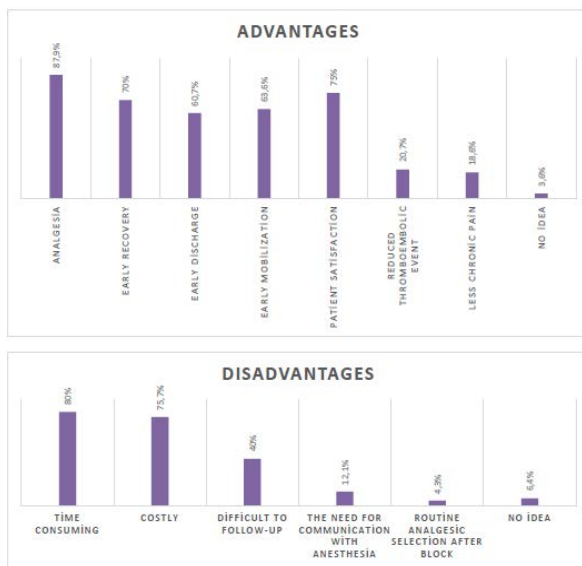

Figure 2A.-2B. Advantages and Disadvantages of IFPB Procedure

to multiple options as follows: 80% time consuming, 70% costly, 40% difficult to follow-up, 12,1% need for communication with anesthesia, 4,3% routine analgesic selection after block, and 6,4 % had no idea. (Figure 2B).

DISCUSSION

According to our results; IFPB is commonly used thanks to the use of the US. Academic studies especially in university hospitals, provide the use and spread of novel blocks. The IFPB is commonly performed in general surgery, orthopedics, neurosurgery, thoracic surgery, and plastic surgery operation rooms. The performance of IFPB at the level of resident, specialist, and academician affects surgical satisfaction at all education levels. Decreasing postoperative pain scores increases patient satisfaction and indirectly increases the satisfaction of the surgeons.

In our study; early mobilization and fast recovery are considered as the other factors that increase surgical satisfaction. In addition, the disadvantages of IFPB are the time consuming and the procedure is costly. The surgical team mostly wants the IFPB application to be performed after the surgical procedure. Some surgical teams want from the anesthesia team to perform the IFPB procedure in the preoperative or postoperative recovery unit so that it does not affect

the surgical time. In our study, neuraxial blocks and peripheral nerve blocks were not included. Despite this, current IFPBs have been shown to increase surgical satisfaction. In addition, we contacted as many surgical teams as we could to get the opinions of different surgical teams in our study.

Thoracic paravertebral blocks, intercostal blocks, and pectoral blocks are performed for the management of postoperative pain following breast surgery (3). In addition, ESPB and RIB are peri-paravertebral blocks and they are performed for many indications from perioperative pain management to chronic pain interventions (14,15). According to our results, the IFPB is commonly requested by general surgeons to reduce postoperative pain.

US-guided ESPB, oblique subcostal transversus abdominis plane block (OSTAP), rectus sheath block, thoracoabdominal nerve with modified perichondral approach (M-TAPA) block and external oblique block (EOB) are widely performed in patients underwent open and laparoscopic abdominal surgeries (12,13). M-TAPA block targets the anterior and lateral cutaneous branches of the thoracoabdominal nerves and provides abdominal analgesia at T4-T12/L1 levels (16-18). In a cadaveric study performed by Ciftci et al, it was shown that M-TAPA provides abdominal analgesia to the level of T12/L1 (18). Gngr et al and Alver et al reported that M-TAPA provided effective analgesia management after laparoscopic cholecystectomy and inguinal surgeries (12,13). Therefore, IFPB is commonly performed in daily anesthesia practice and IFPB increases the satisfaction of the surgical team. In our study, IFPB is commonly requested for laparoscopic abdominal surgeries by the surgeons.

Adductor canal block and pericapsular nerve group block (PENG) are performed for orthopedic surgery procedures (19,20). The PENG block is a novel IFPB defined by Arango et al (19). In addition, lumbosacral ESPB may be used for several orthopedic surgeries such as hip and lower extremity surgery (14).

Video-assisted thoracic surgery (VATS) is the standard surgical procedure for thorax surgery nowadays. Thoracic paravertebral block (TPVB) is the first-line regional technique for VATS surgery. TPVB is difficult to perform and may cause several complications such as pneumothorax, and vascular injury. US-guided ESPB and RIB are commonly performed IFPB for VATS (3,14,15,21). Serratus posterior superior intercostal plane block (SPSIB) is a novel interfascial plane block that was defined by

Tulgar et al. in 2023 (22). It has been reported that SPSIB may be performed for thoracic analgesia (22,23).

Lumbar spinal surgery is one of the most common surgeries performed for the treatment of back and leg pain. In patients undergoing lumbar disc herniation (LDH) operation, severe pain may occur especially in the postoperative period at the operation site. Effective postoperative pain control reduces complications such as hospital-acquired infection and thromboembolism as it provides early mobilization and early discharge. QLB was defined by Blanco (24), TLIP block was defined by Hand et al. in 2015 (25). Modified TLIP defined by Ahiskalioglu et al. in 2017 (26). There are several IFPBs for lumbar and abdominal analgesia (27).

Our survey study has some limitations. Our study was not a single-center study. we reached out to surgeons from different centers. Thus, there were different surgical teams from each other.

In conclusion, this survey study shows that although the IFPB is a novel and current technique, IFPB is commonly used and known in all surgical units. Our results show that the satisfaction level of the surgical team is high and the surgeons request from anesthesia to perform IFPB on the patients who underwent surgery.

Conflict of interest: Author declares that there is no conflict of interest between the authors of the article.

Financial conflict of interest: Author declares that he did not receive any financial support in this study.

Address correspondence to: Selcuk Alver, Istanbul Medipol University, Department of Anesthesiology and Reanimation, Istanbul, Turkey
e-mail: selcukalver@yahoo.com

REFERENCES

1. Lovich-Sapola J, Smith CE, Brandt CP. Postoperative pain control. *Surg Clin North Am* 2015;95(2):301-18.
2. Rawal N. Current issues in postoperative pain management. *Eur J Anaesthesiol* 2016;33(3):160-71.
3. Chin KJ, Versyck B, Pawa A. Ultrasound-guided fascial plane blocks of the chest wall: A state-of-the-art review. *Anaesthesia* 2021;76 Suppl 1:110-26.
4. Ahiskalioglu A, Yayik AM, Celik EC, et al. The shining star of the last decade in regional anesthesia part-I: Interfascial plane blocks for breast, thoracic, and orthopedic surgery. *Eurasian J Med* 2022;54(Suppl1):97-105.
5. De Cassai A, Bonvicini D, Correale C, et al. Erector spinae plane block: A systematic qualitative review. *Minerva Anesthesiol* 2019;85(3):308-19.
6. De Cassai A, Aksu C, Tulgar S, et al. ESP block compared

- to paravertebral block in breast surgery. *Minerva Anesthesiol* 2020;86(10):1116-7.
7. Machi A, Joshi GP. Interfascial plane blocks. *Best Pract Res Clin Anaesthesiol* 2019;33(3):303-15.
8. Elsharkawy H, Pawa A, Mariano ER. Interfascial plane blocks: Back to basics. *Reg Anesth Pain Med* 2018;43(4):341-6.
9. Medetoglu EN, Koksai V, Yilmaz MA, et al. Pericapsular nerve group (PENG) block as a sole anesthetic method for malignant soft tissue excision. *Challenge Journal Of Perioperative Medicine* 2023;1(1):17-9.
10. Alver S, Bahadir C, Tahta AC, et al. The efficacy of ultrasound-guided anterior quadratus lumborum block for pain management following lumbar spinal surgery: A randomized controlled trial. *BMC Anesthesiol* 2022;22(1):394.
11. Alver S, Ciftci B, Celik EC, et al. Postoperative recovery scores and pain management: A comparison of modified thoracolumbar interfascial plane block and quadratus lumborum block for lumbar disc herniation. *Eur Spine J* 2023;14.
12. Alver S, Ciftci B, Güngör H, et al. Efficacy of modified thoracoabdominal nerve block through perichondrial approach following laparoscopic inguinal hernia repair surgery: A randomized controlled trial. *Braz J Anesthesiol* 2023;S0104-0014(23)00046-5.
13. Güngör H, Ciftci B, Alver S, et al. Modified thoracoabdominal nerve block through perichondrial approach (M-TAPA) vs local infiltration for pain management after laparoscopic cholecystectomy surgery: A randomized study. *J Anesth* 2023;37(2):254-60.
14. Tulgar S, Ahiskalioglu A, De Cassai A, et al. Efficacy of bilateral erector spinae plane block in the management of pain: Current insights *J Pain Res* 2019;12:2597-613.
15. Elsharkawy H, Hamadnalla H, Altinpulluk EY, et al. Rhomboid intercostal and subserratus plane block -a case series. *Korean J Anesthesiol* 2020;73(6):550-6.
16. Sawada A, Kumita S, Nitta A, et al. Modified thoracoabdominal nerve block through perichondrial approach (M-TAPA): An anatomical study to evaluate the spread of dye after a simulated injection in soft embalmed Thiel cadavers. *Reg Anesth Pain Med* 2023;48(8):403-7.
17. Tanaka N, Suzuka T, Kadoya Y, et al. Efficacy of modified thoracoabdominal nerves block through perichondrial approach in open gynecological surgery: A prospective observational pilot study and a cadaveric evaluation. *BMC Anesthesiol*. 2022;22(1):107.
18. Ciftci B, Alici HA, Ansen G, et al. Cadaveric investigation of the spread of the thoracoabdominal nerve block using the perichondral and modified perichondral approaches. *Korean J Anesthesiol* 2022;75(4):357-9.
19. Girón-Arango L, Peng PWH, Chin KJ, et al. Pericapsular nerve group (PENG) block for hip fracture. *Reg Anesth Pain Med* 2018;43(8):859-63.
20. Ekinci M, Ciftci B, Demiraran Y, et al. A comparison of adductor canal block before and after thigh tourniquet during knee arthroscopy: A randomized, blinded study. *Korean J Anesthesiol* 2021;74(6):514-21.
21. Çiftçi B, Ekinci M, Atalay YO. Ultrasound-guided rhomboid intercostal block provides effective pain control after video-assisted thoracoscopic surgery: A brief report of three cases. *Korean J Anesthesiol* 2021;74(4):355-7.
22. Tulgar S, Ciftci B, Ahiskalioglu A, et al. Serratus posterior superior intercostal plane block: A technical report on the

- description of a novel periparavertebral block for thoracic pain. *Cureus* 2023;15(2):e34582.
23. Ciftci B, Alver S, Ahiskalioglu A, et al. Serratus posterior superior intercostal plane block for breast surgery: A report of three cases, novel block and new indication. *Minerva Anesthesiol* 2023 doi: 10.23736/S0375-9393.23.17432-3.
 24. Blanco R, Ansari T, Girgis E. Quadratus lumborum block for postoperative pain after caesarean section: A randomised controlled trial. *Eur J Anaesthesiol* 2015;32(11):812-8.
 25. Togha M, Razeghi Jahromi S, Ghorbani Z, et al. M. serum vitamin D status in a group of migraine patients compared with healthy controls: A case-control study. *Headache* 2018; 58:1530-40.
 26. Ahiskalioglu A, Yayik AM, Alici HA. Ultrasound-guided lateral thoracolumbar interfascial plane (TLIP) block: Description of new modified technique. *J Clin Anesth* 2017;40:62.
 27. Alver S, Umutoglu T, Sumer I, et al. Efficacy of bilateral ultrasound-guided transversus abdominis plane block after laparoscopic sleeve gastrectomy: Postoperative, randomized, controlled study. *Challenge Journal of Perioperative Medicine* 2023;1(1):6-11.

Is Vitamin D Associated with The Presence, Type and Severity of Migraine?

D Vitamini Migren Varlığı, Tipi ve Şiddeti ile İlişkili Midir?

Mustafa Altas¹, Zeliha Yazar², Hatice Caliskan Burgucu³, Hasan Huseyin Kir⁴, Mustafa Kulaksizoglu²

¹Necmettin Erbakan University, Faculty of Medicine, Department of Neurology, Konya, Turkey

²Necmettin Erbakan University, Faculty of Medicine, Department of Endocrinology and Metabolism Diseases, Konya, Turkey

³Konya City Hospital, Clinic of Endocrinology and Metabolic Diseases, Konya, Turkey

⁴Elbistan State Hospital, Clinic of Neurology, Kahramanmaraş, Turkey

Address correspondence to: Mustafa Altas, Necmettin Erbakan University, Faculty of Medicine, Department of Neurology, Konya, Turkey

e-mail: drmustafaaltas@gmail.com

Geliş Tarihi/Received: 24 May 2023

Kabul Tarihi/Accepted: 18 August 2023

Öz

Amaç: Migren dünya genelinde yaygın olarak görülen nörovasküler bir hastalıktır. Yapılan birkaç çalışmada D vitamin düzeyleri ile baş ağrısı şiddeti, tipleri arasında ilişki saptanmıştır. Biz de bu çalışmada birincil olarak migren hastaları ile sağlıklı kontroller arasında D Vitamin düzeyleri arasında fark olup olmadığını, ikincil olarak migren tipleri ve şiddeti ile D vitamini düzeyi arasında ilişki olup olmadığını araştırdık.

Hastalar ve Yöntem: Bu vaka-kontrol çalışması Ocak 2021 - Temmuz 2022 tarihleri arasında Necmettin Erbakan Üniversitesi Meram Tıp Fakültesi Nöroloji Bölümünde gerçekleştirildi. Çalışmamıza 18 yaş üstü migren tanısı almış 204 hasta ve baş ağrısı olmayan 204 sağlıklı gönüllü dâhil edildi. Migren tanısı uluslararası baş ağrısı derneği 3 (ICHD-3) kriterlerine göre nöroloji uzmanı tarafından koyuldu.

Bulgular: Migren grubunda ortalama D vitamin düzeyi 15.30±9.93 ng/dl, kontrol grubunda 14.62±7.93 ng/dl idi. Her iki grup arasında istatistiksel açıdan anlamlı fark saptanmadı (p=0.976). Vitamin D eksikliği ve yetersizliği açısından da migren hastaları ile kontrol grubu arasında fark saptanmadı (p=0.365).

Sonuç: Çalışmamızın sonuçlarına göre migren hastaları ile normal popülasyon D vitamini düzeyleri arasında fark bulamadık. Migren alt tipleri arasında da D vitamini düzeyleri arasında istatistiksel bir fark yoktu. Ayrıca migren şiddeti ve migren atak sıklığı ile D vitamini düzeyleri arasında da ilişki saptanmadı. Çalışmamızın sonuçlarına göre D vitamini eksikliği prevalansının yüksekliği hem migren hastalarında hem de sağlıklı popülasyonda ortak sorun olarak gözükmekte olup bu konuda yapılacak geniş örnek sayılı randomize klinik çalışmalara ihtiyaç vardır.

Anahtar Kelimeler: Baş ağrısı, migren, vitamin D

Abstract

Aim: Migraine is a neurovascular disease that is common worldwide. In a few studies, a relationship was found between vitamin D levels and headache severity and types. In this study, we primarily investigated whether there was a difference in vitamin D levels between migraine patients and healthy controls, and secondarily, whether there was a relationship between types and severity of migraine and vitamin D levels.

Patients and Methods: This case-control study was carried out between January 2021 - July 2022 at Necmettin Erbakan University Meram Faculty of Medicine, Department of Neurology. 204 patients over the age of 18 who were diagnosed with migraine and 204 healthy volunteers without headache were included in our study. The diagnosis of migraine was made by a neurologist according to the International Headache Society 3 (ICHD-3) criteria.

Results: The mean vitamin D level was 15.30±9.93 ng/dl in the migraine group and 14.62±7.93 ng/dl in the control group. There was no statistically significant difference between the two groups (p=0.976). There was no difference between migraine patients and the control group in terms of vitamin D deficiency and insufficiency (p=0.365).

Conclusion: According to the results of our study, we did not find any difference in vitamin D levels between migraine patients and the normal population. There was no statistical difference in vitamin D levels among migraine subtypes. In addition, no relationship was found between severity and frequency of migraine attacks and vitamin D levels. According to the results of our study, the high prevalence of vitamin D deficiency appears to be a common problem in both migraine patients and the healthy population, and randomized clinical studies with large sample numbers are needed on this subject.

Keywords: Headache, migraine, vitamin D

Cite this article as: Altas M, Yazar Z, Caliskan Burgucu H, Kir HH, Kulaksizoglu M. Is Vitamin D Associated with The Presence, Type and Severity of Migraine? Selcuk Med J 2023;39(3): 122-127

Disclosure: None of the authors has a financial interest in any of the products, devices, or drugs mentioned in this article. The research was not sponsored by an outside organization. All authors have agreed to allow full access to the primary data and to allow the journal to review the data if requested.



"This article is licensed under a [Creative Commons Attribution-NonCommercial 4.0 International License](https://creativecommons.org/licenses/by-nc/4.0/) (CC BY-NC 4.0)"

INTRODUCTION

Migraine is a common neurovascular disorder that affects 12-15% of the general population. Individuals with migraine experience various issues such as absenteeism and decreased productivity and this puts a heavy burden on the society (1).

Migraine attacks are featured as moderate-to-severe, throbbing, unilateral headaches with nausea, vomiting, phonophobia, and photophobia. The attacks duration usually lasts from a few hours to 2-3 days (2). Approximately 25% of the migraine patients experience an aura, (temporary disturbance in visual, sensory, language or motor functions) before the migraine attacks (3). Migraine is divided into 2 main types according to the frequency of headache. Chronic migraine has more than 15 headache days in a month and episodic migraine has less than 15 headache days in a month (2).

The pathogenesis of migraine is not clear due to various factors. In this context, specific factors such as cytokines (interleukin 1 beta (IL-1B), IL-6 and tumor necrosis factor α (TNF α)), immune cells (mast cells), genes and environmental characteristics play a crucial role. Several treatment options have been developed to target them. (4-5). In addition, various dietary supplements such as magnesium have been suggested to be effective in the prophylactic treatment of migraine. Also one of these is vitamin D (6).

In addition to the beneficial effects of vitamin D on calcium and bone metabolism, in epidemiological and clinical studies; low vitamin D levels have been associated with Alzheimer's, depression, psychosis, autism, autoimmune and endocrine disorders, and cancer (7). Several studies have found that a relationship between vitamin D levels and musculoskeletal pain, headache and chronic pain (8-9). There are also studies in the literature examining the relationship between vitamin D deficiency and migraine. However, this relationship has not been fully demonstrated in all these studies.

In this study, we aimed primarily to show whether there is a difference in vitamin D levels between migraine patients and healthy controls, and secondly, whether there is a relationship between migraine types and migraine severity and vitamin D levels.

PATIENTS AND METHOD

This case-control study was carried out between January 2021 and July 2022 at Necmettin Erbakan University Meram Faculty of Medicine, Department of Neurology. The Necmettin Erbakan University

Meram Medical Faculty Ethics Committee approved the study protocol on March 3, 2023, with the number of 2023/4214.

The study was conducted 204 migraine patients over the age of 18 as study group and 204 age- and gender-matched healthy volunteers as the control group. Migraine diagnosis was settled by a neurologist according to the International Headache Society 3 criteria. Healthy volunteers (who were admitted to the hospital for other reasons) without headache were included as the control group. In both groups; patients with known vitamin D disorders, those using vitamin D in the last 3 months, drugs that affect vitamin D metabolism, those with chronic kidney and liver disease, cancer patients and pregnant women were excluded.

After the diagnosis of migraine was made, the severity of migraine was determined by the Visual Analog Scale (VAS) score and the disability by the Migraine Disability Assessment Score (MIDAS) score. The MIDAS questionnaire validated in Turkish was applied for the MIDAS score. The MIDAS scores between 0-5 were classified as 1st degree, those between 6-10 as 2nd degree, those between 11-20 as 3rd degree and those who were 21 and above were classified as 4th degree (10). According to VAS, according to the point where the patients marked the severity of the pain on the 100 ml VAS line, 0-4 ml pain was evaluated as no pain, 5-44 ml mild pain, 45-74 ml moderate pain, 75-100 ml severe pain (11). Patients were grouped as migraine with or without aura according to whether they had aura or not, chronic migraine for 15 days or more a month headache, episodic migraine for 14 days or less. From the patient's anamnesis, the frequency of migraine attacks, the number of days spent with headache in a month, whether it was episodic or chronic, with or without aura were recorded.

Venous blood was collected from all participants during the first visit, and 25 Hydroxy vitamin D levels were measured were made with the enzyme-linked immunosorbent assay (ELISA, Fortress Diagnostics Limited, United Kingdom) method. Vitamin D measurements were also made in the control group in the same month. Vitamin D level <20 is considered as vitamin D deficiency, 21-29 vitamin D insufficiency, 30 and above were considered as normal (12).

Statistical analysis

Statistical analyzes were performed using the Statistical Package for Social Sciences 21.0 program. Continuous variables were given as mean

± standard deviation if the distribution was normal. Normal distribution was checked by the Kolmogorov-Smirnov test. In the comparison of independent group differences, the test of significance of the difference between two means (Independent samples t-test) was used when continuous variables conforming to normal distribution; Mann-Whitney U test was used to compare independent group differences when continuous variables not conforming to normal distribution. Chi-square test was used to compare categorical variables between independent groups. The comparison of migraine severity, disability scores and vitamin D levels was done with Kruskal-Wallis test. ANOVA test was used for the relationship between different subcategories of vitamin D and migraine characteristics. The correlation between vitamin D levels and migraine clinical features, Pearson or Spearman tests were used according to the distribution characteristics of the data. A p value of <0.05 for the differences was considered statistically significant.

RESULTS

Demographic features

204 migraine patients and 204 healthy volunteers as control groups were included in our study. The number of men and women was equal in both groups (F:176 M:28). There was no statistically significant difference between the two groups in terms of age and gender (p=0.131, p=1.00, respectively). The mean age was 41.73±11.95 years in migraine patients and

43.59±14.86 years in the control group. 155 (76%) of migraine patients had migraine without aura and 49 (24%) had migraine with aura. 120 (58.8%) patients had episodic, 84 (41.2%) patients had chronic migraine.

Serum vitamin D levels

The mean vitamin d level was 15.30±9.93 ng/dl in the migraine group and 14.62±7.93 ng/dl in the control group. There was no statistically significant difference between the two groups (p=0.976). In terms of vitamin d deficiency and insufficiency, no difference was found between migraine patients and the control group (p=0.365)(Table 1).

The mean number of migraine attacks was 6.02±3.37, and the mean number of days spent with headache was 13.03±6.81 days. There was no correlation between the number of migraine attacks, the number of days with headache and vitamin D levels (p=0.505, p=0.835, respectively). There was no difference in the number of attacks in the group with vitamin deficiency, insufficiency or sufficient vitamin D (p=0.467).

The mean vitamin D level was 14.31±8.98 ng/dl in migraine with aura, and 15.61±10.22 ng/dl in migraine patients without aura. There was no statistically significant difference between the two groups (p=0.443). In the aura group, vitamin D deficiency was found in 37 (75.5%) patients, vitamin D insufficiency in 9 (18.4%) patients, and adequate vitamin D in 3 (6.1%) patients. There was no difference between the migraine with aura and migraine without aura groups

Table 1. Comparison of demographic characteristics and vitamin D levels of migraine patients and control group

	Migraine Group (204)	Control Group (204)	p Value
Age(year)	41.73±11.95	43.59±14.86	0.131
Gender(male/female)	28/176	28/176	1.00
Vitamin D levels (ng/mL)	15.30±9.93	14.62±7.93	0.976
Vitamin D levels (ng/mL)			0.365
≥30	14	8	
21-29	39	36	
≤20	151	160	

Table 2. Comparison of migraine characteristics and vitamin D levels

	Episodic Migraine (n=120)	Chronic Migraine (n=84)	p Value	Migraine with aura (n=155)	Migraine without aura (n=49)	p Value
Vitamin D levels (ng/mL)	14.93±9.69	15.82±10.30	0.609	14.31±8.98	15.61±10.22	0.443
Vitamin D levels (ng/mL)			0.072			0.956
≥30	11(%9.2)	3 (%3.6)		11(7,1)	3 (%6.1)	
21-29	27(%22.5)	12(%14.3)		30(19,4)	9 (%18.4)	
≤20	82 (%68.3)	69(%82.1)		114(73,5)	37 (%75.5)	

Table 3. Comparison of migraine severity and vitamin d levels

	Vitamin D level (ng/mL)	p Value
VAS *		0.121
mild	9,35±4,73	
moderate	15,28±8,21	
severe	15,37±10,26	
MIDAS*		0.023
1(0-5 day/month)	15,68±8,20	
2(6-10 day/month)	14,87± 10,07	
3(11-21 day/month)	15,57±10,88	
4 (>21 day/month)	15,28±9,27	

*VAS:Visual Analog Scale MIDAS:Migraine Disability Assessment Score

in terms of vitamin D deficiency or insufficiency ($p=0.956$).

The mean vitamin D level was 15.82 ± 10.30 ng/dl in the chronic migraine group, and 14.93 ± 9.69 ng/dl in the episodic migraine group. There was no statistically significant difference between the two groups ($p=0.609$). 82 (68.3%) patients with episodic migraine had vitamin D deficiency, 27 (22.5%) patients had vitamin D insufficiency, 11 (9.2%) patients had sufficient vitamin D. Vitamin D deficiency was found in 69 (82.1%) patients with chronic migraine, 12 (14.3%) patients had vitamin d insufficiency and 3 (3.6%) patients had sufficient levels of vitamin D. There was no difference between the two groups in terms of vitamin D deficiency or insufficiency ($p=0.072$)[Table 2].

In the migraine group, VAS scores were mild in 2 (1%) patients, moderate in 31 (15.2%) patients, and severe in 171 (83.8%) patients. MIDAS score was found in 30 (14.7%) patients for 0-5 days, 72 (35.3%) patients for 6-10 days, 71 (34.8%) patients for 11-20 days, and 31 (15.2%) patients for 21 days and above. VAS and MIDAS scores and vitamin D levels are shown in the Table 3. There was no difference in terms of VAS criteria and vitamin D levels ($p=0.121$). There was a significant difference between MIDAS 1st degree and MIDAS 3rd degree in terms of vitamin D levels among MIDAS subgroups ($p=0.018$).

There was no significant correlation between VAS and MIDAS scores and vitamin D levels (respectively $p=0.819$, $p=0.747$)

DISCUSSION

According to the results of our study, no difference was found between the mean vitamin D levels of migraine patients and the normal population. Vitamin D levels were found to be similar among migraine subtypes. There was no correlation between migraine

severity, migraine attack frequency and vitamin D levels.

The prevalence of vitamin d deficiency and insufficiency in migraine patients varied between 40-68% and 13-80%, respectively (13-15). The results in our study were 74% for vitamin d deficiency and 19.1% for vitamin d insufficiencies, which were similar to the study of Song et al. (16). Different cut-off values were taken for vitamin d deficiency and insufficiency in different studies, and in our study, no difference was found between migraine patients and the control group in terms of vitamin d deficiency-insufficiency.

When we look at the literature, there are studies showing the relationship between various types of headache and vitamin D. In a study comparing patients with chronic tension-type headache and healthy controls, vitamin D was found to be significantly low in patients with chronic tension-type headache (17). In a study comparing cluster headache, migraine and healthy controls, no difference was found between the groups in terms of vitamin D levels (18). In a study in which migraine, tension-type headache and control groups were compared in the pediatric age group, no difference was found between the groups in terms of mean vitamin D levels (19).

In studies comparing migraine patients and the control group in terms of vitamin D levels, there are studies that found low vitamin D levels in migraine patients compared to the control group, as well as studies that did not find a difference (20-23). In the study of Kjaergaard et al.(13), vitamin D levels were found to be lower in migraine patients who did not smoke compared to the control group, and similar in smokers. In the cross-sectional study of Zandifar et al., in which 105 migraine patients and 110 healthy controls were compared, no difference was found between the case and control groups in terms of vitamin D levels, similar to our study, and vitamin D deficiency and vitamin D insufficiency were found to be similar between the case and control groups (14). Unlike our study, in the study of Rapisarda et al.(23), vitamin D levels in the migraine group were found to be significantly lower than in the control group. In the study conducted by Çelikkilek et al.(24) in which the vitamin D, vitamin D binding protein and vitamin D receptor levels of migraine patients and the control group were compared, significantly lower vitamin D levels were found in the migraine group.

Studies have found conflicting results between migraine type, frequency and severity, and vitamin D level. Similar to our study, in the study of Togha et

al.(25) in 2018 comparing 70 migraine patients and 70 healthy controls, no difference was found between chronic migraine patients and episodic migraine patients in terms of vitamin D levels. In another study comparing chronic migraine and episodic migraine patients, similar results were obtained between the groups in terms of vitamin D levels (26). In the study of Çelikbilek et al.(24), no correlation was found between the frequency of migraine severity and vitamin D levels, vitamin D binding protein, and the number of vitamin D receptors. Similarly, in the study of Zandifar et al.(14), no relationship was found between migraine severity and vitamin D levels. Unlike these studies, in the study of Rapisarda et al.(23), a negative linear correlation was found between vitamin D levels and headache days.

In the literature, high vitamin D levels were found in those living in low latitudes, and this was seen as the reason for the low prevalence of headaches. An increase in the frequency of headaches in the winter months and a decrease in the summer months suggested that low vitamin D levels play a role in the frequency of headaches (27).

The pathogenesis of migraine is not fully understood, and it is stated that vitamin D has an effect on inflammation, pain desensitization and the immune system. The increase in proinflammatory and neuroinflammatory factors in the nervous system causes vasodilation in the arteries and causes pain in the first place. It is stated that vitamin D has beneficial effects in the pathogenesis of migraine due to its anti-inflammatory and immune-regulatory effects (28). In addition, it has been stated that magnesium deficiency has a role in the pathogenesis of migraine, and a direct relationship has been found between magnesium deficiency and vitamin D deficiency (29). Another mechanism is the presence of vitamin D, vitamin D receptor, vitamin D binding protein and 1 alpha hydroxylase enzyme (converts vitamin D to active vitamin D) in the central nervous system, especially in the hypothalamus (30).

There are some limitations of our study. Firstly, our study was conducted in a relatively small group of patients. Absence of body mass index is another deficiency of our study. Dietary or supplementary products and alcohol use that may affect vitamin D levels were not evaluated. Vitamin D binding globulin and vitamin D receptor levels, which may help explain the migraine mechanism, have not been studied.

CONCLUSION

According to the results of our study, the high prevalence of vitamin D deficiency seems to be a common problem in both migraine patients and the healthy population. We did not find a relationship between vitamin D levels and migraine characteristics and severity. However, there is a need for randomized clinical studies with large sample numbers to be conducted on this subject.

Conflict of interest: Authors declare that there is no conflict of interest between the authors of the article.

Financial conflict of interest: Authors declare that they did not receive any financial support in this study.

Address correspondence to: Mustafa Altas, Necmettin Erbakan University, Faculty of Medicine, Department of Neurology, Konya, Turkey
e-mail: drmustafaaltas@gmail.com

REFERENCES

1. Ashina M, Katsarava Z, Do TP, et al. Migraine: Epidemiology and systems of care. *Lancet* 2021;397(10283):1485.
2. Arnold M. Headache classification committee of the international headache society (IHS). The international classification of headache disorders, *Cephalalgia* 2018;38:1-211.
3. Fraser CL, Hepschke JL, Jenkins B, et al. Migraine aura: Pathophysiology, mimics, and treatment options. *Semin Neurol* 2019;39(6):739-48.
4. Conti P, D'Ovidio C, Conti C, et al. Progression in migraine: Role of mast cells and pro-inflammatory and anti-inflammatory cytokines. *Eur J Pharmacol* 2019;844:87-94.
5. Cayir A, Cobanoglu H, Coskun M. Assessment of the genotoxic potential of a migraine-specific drug by comet and cytokinesis-block micronucleus assays. *Expert Opin Drug Metab Toxicol* 2020;16(5):441-6.
6. Wells RE, Beuthin J, Granetzke L. Complementary and integrative medicine for episodic migraine: An update of evidence from the last 3 years. *Curr Pain Headache Rep* 2019;23(2):10.
7. Anjum I, Jaffery SS, Fayyaz M, et al. The role of vitamin D in brain health: A mini literature review. *Cureus* 2018;10(7):2960.
8. Ghorbani Z, Togha M, Rafiee P, et al. Vitamin D in migraine headache: A comprehensive review on literature. *Neurol Sci* 2019;40:2459-77.
9. Wu Z, Maihi Z, Stewart AW, et al. The association between vitamin D concentration and pain: A systematic review and meta-analysis. *Public Health Nutr* 2018;21(11):2022-37.
10. Ertas M, Siva A, Dalkara T, et al. Validity and reliability of the Turkish migraine disability assessment (MIDAS) questionnaire. *Headache* 2004;44(8):786-93.
11. Scott J, Huskisson EC. Graphic representation of pain. *Pain* 1976;2(2):175-84.
12. Holick MF, Binkley NC, Bischoff-Ferrari HA, et al. Evaluation, treatment, and prevention of vitamin D deficiency: An endocrine society clinical practice guideline. *J Clin Endocrinol Metab* 2011;96(7):1911-30.

13. Kjaergaard M, Eggen AE, Mathiesen EB, et al. Association between headache and serum 25-hydroxyvitamin D; The tromso study: Tromso 6. *Headache* 2012;52(10):1499-505.
14. Zandifar A, Masjedi SS, Banihashemi M, et al. Vitamin D status in migraine patients: A case-control study. *Biomed Res Int* 2014;2014:514782.
15. Mottaghi T, Khorvash F, Askari G, et al. The relationship between serum levels of vitamin D and migraine. *J Res Med Sci* 2013;18(Suppl 1):66-70.
16. Song TJ, Chu MK, Sohn JH, et al. Effect of vitamin D deficiency on the frequency of headaches in migraine. *J Clin Neurol (Korea)* 2018;14(3):366-73.
17. Prakash S, Rathore C, Makwana P, et al. Vitamin D deficiency in patients with chronic tension-type headache: A case-control study. *Headache* 2017;57(7):1096-8.
18. Sohn JH, Chu MK, Park KY, et al. Vitamin D deficiency in patients with cluster headache: A preliminary study. *J Headache Pain* 2018;19(1):54.
19. Hancı F, Kabakus N, Türay S, et al. The role of obesity and vitamin D deficiency in primary headaches in childhood. *Acta Neurol Belg* 2020;120:1123-31.
20. Gallelli L, Michniewicz A, Cione E, et al. 25-Hydroxy vitamin D detection using different analytic methods in patients with migraine. *J Clin Med* 2019;8(6):895.
21. Patel U, Kodumuri N, Malik P, et al. Hypocalcemia and vitamin D deficiency amongst migraine patients: A nationwide retrospective study. *Medicina (Kaunas)* 2019;55(8):407.
22. Hussein M, Fathy W, Elkareem RMA. The potential role of serum vitamin D level in migraine headache: A case-control study. *J Pain Res* 2019;12:2529.
23. Rapisarda L, Mazza MR, Tosto F, et al. Relationship between severity of migraine and vitamin D deficiency: A case-control study. *Neurol Sci* 2018;39:167-8.
24. Celikbilek A, Gocmen AY, Zararsiz G, et al. Serum levels of vitamin D, vitamin D-binding protein and vitamin D receptor in migraine patients from central Anatolia region. *Int J Clin Pract* 2014;68:1272-7.
25. Togha M, Razeghi Jahromi S, Ghorbani Z, et al. M. serum vitamin D status in a group of migraine patients compared with healthy controls: A case-control study. *Headache* 2018; 58:1530-40.
26. Iannacchero R, Costa A, Squillace A, et al. P060. Vitamin D deficiency in episodic migraine, chronic migraine and medication-overuse headache patients. *J Headache Pain* 2015;16(Suppl 1):A184.
27. Prakash S, Mehta NC, Dabhi AS, et al. The prevalence of headache may be related with the latitude: A possible role of vitamin D insufficiency? *J Headache Pain* 2010;11:301-7.
28. Lukacs M, Tajti J, Fulop F, et al. Migraine, neurogenic inflammation, drug development-pharmacochemical aspects. *Curr Med Chem* 2017;24:3649-65.
29. Reddy P, Edwards LR. Magnesium supplementation in vitamin D deficiency. *Am J Ther* 2019;26(1):124-32.
30. Eyles DW, Burne TH, McGrath JJ. Vitamin D, effects on brain development, adult brain function and the links between low levels of vitamin D and neuropsychiatric disease. *Front Neuroendocrinol* 2013;34:47-64.

The Use of Groin Flap for Hand Defects: Which Should Be Prior, Free or Pedicled, Based on Patient-Reported Outcomes?

El Defektleri İçin Kasık Flebinin Kullanımı: Serbest veya Pediküllü, Hasta Bildirim Sonuçlarına Göre Hangisi Öncelikli Olmalı?

Selman Hakki Altuntas¹, Omer Faruk Dilek², Osman Gurdal³, Fuat Uslusoy¹, Mustafa Asim Aydın⁴

¹Suleyman Demirel University, School of Medicine, Department of Plastic, Reconstructive and Aesthetic Surgery, Isparta, Türkiye

²Sisli Hamidiye Etfal Training and Research Hospital, Department of Plastic, Reconstructive and Aesthetic Surgery, Istanbul, Türkiye

³Suleyman Demirel University, School of Medicine, Department of Biostatistics and Medical Informatics, Isparta, Türkiye

⁴Olimpos Sağlık Danışmanlık LTD. ŞTI, Private Practice, Plastic Surgery, Antalya, Türkiye

Address correspondence to: Selman Hakki Altuntas, Süleyman Demirel University, School of Medicine, Department of Plastic, Reconstructive and Aesthetic Surgery, Isparta, Türkiye
e-mail: shaltuntas@gmail.com

Geliş Tarihi/Received: 10 July 2023
Kabul Tarihi/Accepted: 30 August 2023

Öz

Amaç: Pediküllü kasık flebi, eldeki geniş defektlerin çoğu için standart bir flep olarak önerilmiştir. Kasık flebini serbest flep olarak kaldırmak da mümkündür. Geniş el defektleri olan hastalarda pediküllü ve serbest kasık flebi rekonstrüksiyonlarını hasta bildirim sonuçlarına göre retrospektif olarak karşılaştırmayı amaçladık.

Hastalar ve Yöntem: 2013-2020 yılları arasında ellerindeki geniş defektler nedeniyle pediküllü veya serbest kasık flebi yapılan 16 hasta bu çalışmaya dahil edildi. Çalışma retrospektif klinik anket çalışması olarak gerçekleştirildi. Hastalar pediküllü kasık flebi grubu (n=8) ve serbest kasık flebi grubu (n=8) olmak üzere iki gruba ayrıldı. Hastalar 2 yıl takip edildi. Hastalara postoperatif dönemde DASH ve SF-36 testleri uygulandı.

Bulgular: Pediküllü flep uygulanan hastaların yarısında ciddi dirsek ve omuz ağrısı vardı ve fizik tedavi gerektirdi. Yara iyileşmesi serbest kasık flebi grubunda anlamlı olarak daha erken tamamlandı (p<0,05). Pediküllü grupta ortalama hastanede kalış süresi serbest flep grubundan (sırasıyla 21 gün ve 13 gün) daha uzundu ve bu istatistiksel olarak anlamlı değildi. DASH skorları pediküllü flep grubunda subakut ve kronik evrede 92 ve 72 iken, serbest flep grubunda sırasıyla 52 ve 24 bulundu (p=0,012 ve 0,002). SF-36 skorlarına göre pediküllü flep grubunda fiziksel fonksiyonlar anlamlı olarak bozulmuştu (p < 0.001).

Sonuç: Kasık flebinin serbest flep olarak transfer edilmesi ile omuz ve dirsek eklemi ile ilgili problemler ortadan kalktı, el rehabilitasyonuna daha erken başlanabildi ve günlük işlere dönüş süresi kısaldı. Eğer kasık flebi tercih edilecekse, serbest stil ilk olarak gözönüne alınmalıdır.

Anahtar Kelimeler: El yaralanmaları, pediküllü flep, serbest flep.

Abstract

Aim: A pedicled groin flap has been offered as a standard flap for most of the large defects in the hand. Raising the groin flap is also possible as a free flap. We aimed to compare the pedicled and free groin flap reconstructions in patients with large hand defects based on patient-reported outcomes, retrospectively.

Patients and Methods: Sixteen patients who had groin flaps pedicled or free for the large defects of their hands were included in this study between 2013-2020. This study was performed retrospectively clinical survey work. Patients were divided into two groups: the pedicled groin flap group (n=8) and the free groin flap group (n=8). Patients were followed for 2 years. The patients were subjected to DASH and SF-36 tests in postoperative period.

Results: Half of the patients with pedicled flaps had serious elbow and shoulder pain and required physical therapy. The wound healing was completed significantly earlier in the free groin flap group (p<0.05). The DASH scores were found to be 92 and 72 in the subacute and chronic stages in the pedicled flap group, whereas 52 and 24 were found in the free flap group, respectively (p = 0.012 and 0.002). According to SF-36 scores, physical functions were impaired significantly in the pedicled flap group (p < 0.001).

Conclusions: By transferring the groin flap as a free flap, the problems related to shoulder and elbow joints have disappeared, hand rehabilitation could be started earlier, and the time to return to daily work was shortened. So, if the groin flap is preferred, free style should be considered first.

Keywords: Hand injuries, pedicled flap, free flap.

Cite this article as: Altuntas SH, Dilek OF, Gurdal O, Uslusoy F, Aydın MA. The Use of Groin Flap for Hand Defects: Which Should Be Prior, Free or Pedicled, Based on Patient-Reported Outcomes? Selcuk Med J 2023;39(3): 128-134

Disclosure: None of the authors has a financial interest in any of the products, devices, or drugs mentioned in this article. The research was not sponsored by an outside organization. All authors have agreed to allow full access to the primary data and to allow the journal to review the data if requested.



"This article is licensed under a [Creative Commons Attribution-NonCommercial 4.0 International License](https://creativecommons.org/licenses/by-nc/4.0/) (CC BY-NC 4.0)"

INTRODUCTION

Most of the large defects in the hand required vascularized coverage because they exposed tendons and bones. In flap selection for soft tissue reconstruction, the size and site of the injury, other accompanying traumas, the age of the patient, and the patient's comorbidities should be considered (1). Physical therapy plays an important role in hand injuries. A healthy soft tissue reconstruction is also essential for the success of the postoperative physical therapy program (2). Therefore, the importance of the flap method chosen for soft tissue and skin cover is increasing. Local flaps are often insufficient to cover large tissue defects. Distant and free flaps are more preferred in these indications (1).

McGregor and Jackson described the groin flap in 1972. Since that time, this flap has been offered as a standard procedure for covering large hand defects (3, 4). But, sometimes, immobilization of the upper extremity because of this procedure caused serious elbow and shoulder pain and disability and hindered appropriate positioning and a physiotherapy program. A groin flap is possible to transfer as a free flap in the same indications. The main disadvantages of free flaps compared to pedicled flaps are that they require microsurgical equipment and skills and are time-consuming surgery. Although the free groin flap was described as the first free flap in the literature, the use of this flap was halted by the assertion of some technical difficulties at the time. Recently, the free groin flap has been popularized again by being named a Superficial Circumflex Iliac Perforator (SCIP) flap because of the thin flap, the most hidden donor site, and technical advancements (5, 6).

We aimed to compare pedicled and free groin flap patients in terms of patient comfort, functional recovery of the hand, and duration of hospital stay.

PATIENTS AND METHODS

Patients

This study included sixteen patients who had large defects in their hands and reconstructed the soft tissues with groin flaps (pedicled or free) between 2013-2020. This study was planned as a retrospective clinical survey work. The Local Clinical Research Ethic Committee approved the conduct of this study (No: 2020-110). Patients were informed about the study and consented voluntarily. They were split into two groups: the pedicled groin flap group (PGF), which had eight patients ($n = 8$), and the free groin flap group (FFG), which also had eight patients ($n = 8$).

Except for one patient, the hand defects were linked to traumatic injuries such as vehicle and industrial accidents. One patient had severe palmar skin burn contracture. In eight patients, hand defects were covered with a pedicled groin flap, while the others received a free groin flap. Groin flap reconstructions were performed immediately in 13 patients and late in 3 patients.

Surgical Technique

Skin and soft tissue coverage of large tissue defects in the hand were performed with pedicled or freely raised flaps raised from the groin area. The operations were performed by the same two teams, especially in the free flap. While the first team was preparing the recipient vessel for free flaps in addition to the necessary procedures on the hand (debridement, fracture fixation, tendon, and nerve repairs, etc.), the second team performed flap raising.

When the groin flap was planned as a pedicle, the pedicle was left as long as possible to allow a more comfortable hand position. The pedicle was tubed. The SCIA origin was found on the femoral artery medially before raising the flap, which was raised as a free flap. In both groups, the sartorius fascia was included so that the deep branch remained on the flap at the ASIS level. When it was raised as a free flap, the superficial inferior epigastric vein was found by first entering the incision parallel to the inguinal ligament, at the level of the femoral artery and its medial one. The vein was followed inferiorly to the place where it opened into the saphenous vein. This vein was used instead of the comitant vein for anastomose. By reaching the femoral artery medially from the lateral side of this vein, the artery that may belong to the flap was seen from the femoral side (Figure 1). Afterward, the flap was raised laterally and joined to the medial exploration area (Figure 2). The recipient's vessels were the radial artery and superficial vein in the snuff box. Two team approaches were usually performed. One team repaired the injured structures in the hand, such as tendon, bone, and nerve, and prepared the recipient vessels, while the other team was working on the flap. SCIA and comitant vein calibers between recipient vessels were well matched. Vessel anastomoses were performed end to end fashion (Figure 3).

Evaluation of Patients and Questionnaire Study

Patients' wound healing and wound problems were compared. When the epithelization was finished, wound healing was approved. Wound complications, such as dehiscence and infection, were discussed.

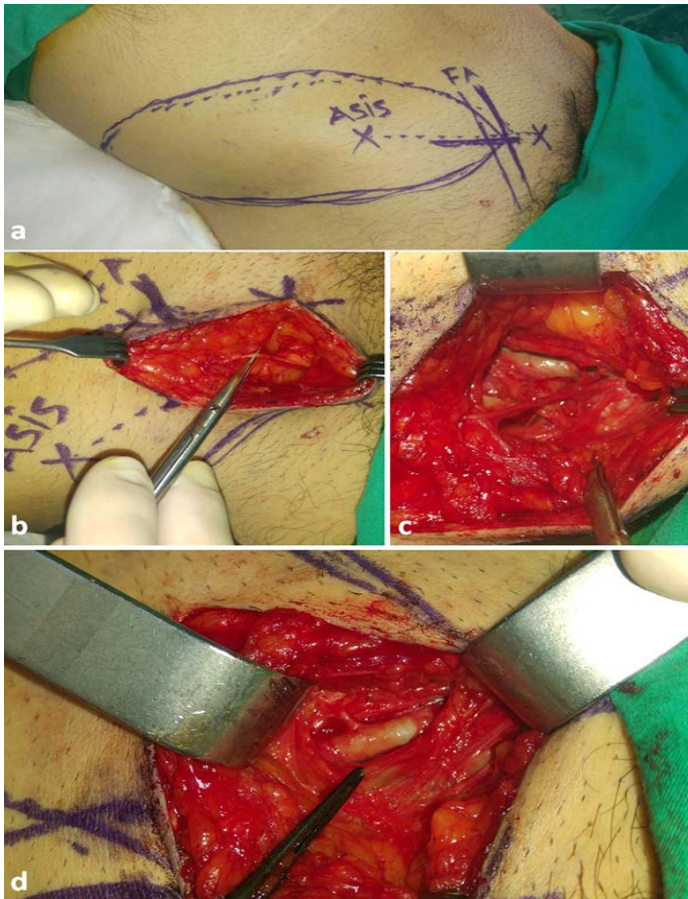


Figure 1. Marking the anatomic landmarks and flap boundaries of the groin flap for freestyle (a) superficial epigastric vein dissection until the saphenous bulb (b, c) and revealing the SCIA arising from the femoral artery (d).

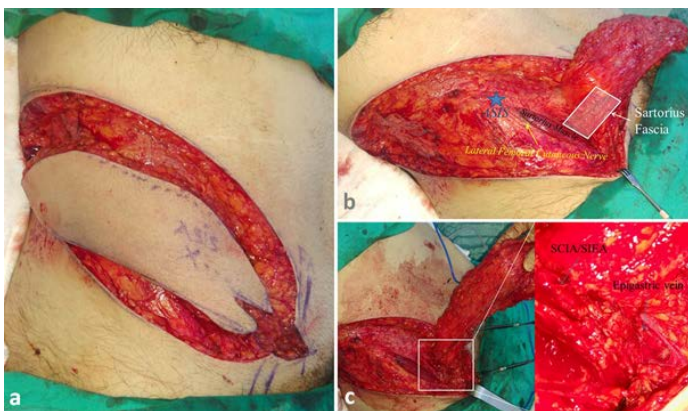


Figure 2. Raising the the free groin flap after pedicle dissection (a). Sartorius fascia should be included in to the flap beginning from ASIS (b). View after completing the dissection (c).

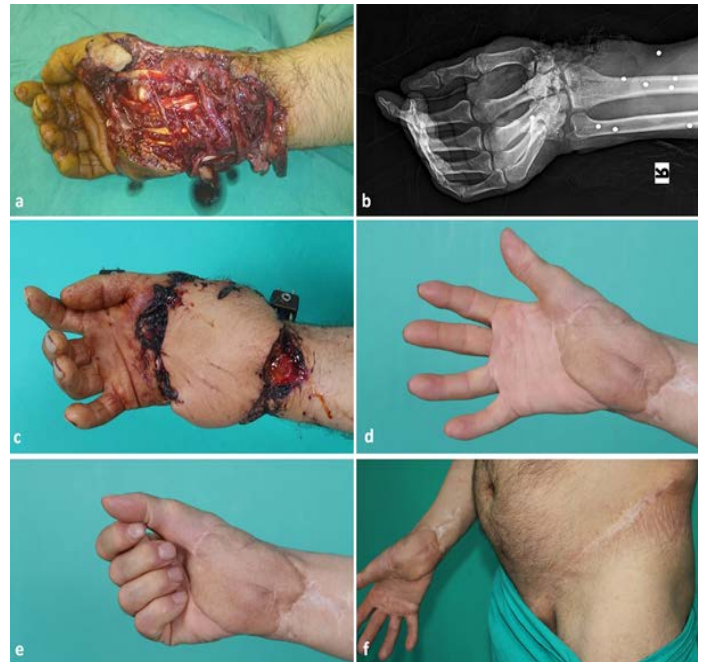

Figure 3. A patient with a crush injury in the hand, including the wrist joint (a, b). A free groin flap was used to cover the skin defect after bone stabilization and tendon and nerve repair. Early postoperative view (c) late postoperative view of the hand and donor site (d, e, f).

Following the postoperative period, the patients were given DASH and SF-36 tests. The SF-36 test was used to assess general patient comfort in the early postoperative period. At the first and sixth months after surgery, a DASH test was performed to evaluate shoulder, elbow, and hand problems. The Visual Analogue Scale (VAS) was used to assess pre- and postoperative pain, and which days the patients could walk and sit in the toilet without pain and required a second person for daily work were asked.

Statistical Analysis

The arithmetic mean, standard deviation, standard error, median, and mode values of the dataset were calculated to produce descriptive statistical analyses. The Shapiro-Wilk statistical test was used to determine the normal distribution of continuous data, and the Levene test was used to determine homogeneity control between variances ($p > 0.05$). Because the data from the two groups had a sample size of less than 12, and in addition, the most independent group comparisons did not show a normal distribution or homogeneity, the Mann-Whitney U test was used. The Kruskal-Wallis H test and Bonferroni post-

Table. Demographics of patients and perioperative informations .

Flap group	Age	Gender	Operation time	Hospital stay	Pedicle division	Wound healing	Wound infection	Wound dehiscence
		(min.)*		(day)	time (day)	time (day)*	*	*
Pedicated	61	K	125	30	40	40	+	+
Pedicated	67	E	150	40	30	61	+	+
Pedicated	49	E	105	15	25	35	-	-
Pedicated	55	K	120	38	31	52	+	+
Pedicated	56	E	115	28	32	43	+	+
Pedicated	20	E	130	7	25	34	-	-
Pedicated	66	E	90	6	21	15	-	-
Pedicated	23	E	70	4	28	20	-	-
Free	32	E	280	9	0	17	-	-
Free	22	E	230	10	0	26	-	-
Free	20	K	260	11	0	19	-	-
Free	21	E	245	13	0	20	-	-
Free	56	E	345	21	0	23	-	-
Free	13	E	270	14	0	18	-	-
Free	55	E	360	23	0	25	-	-
Free	34	E	250	8	0	15	-	-

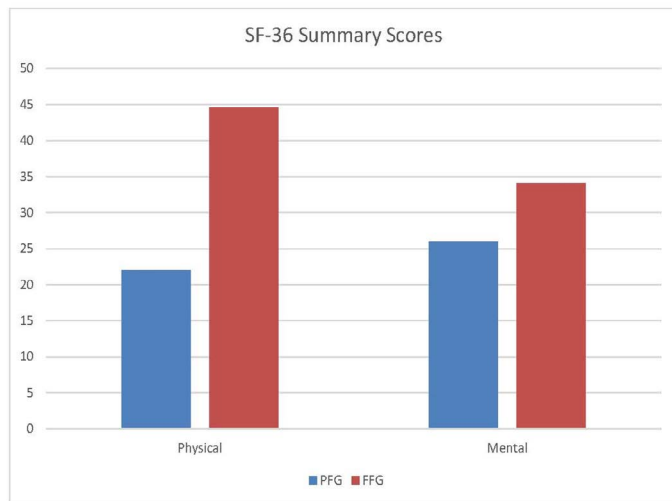
*: p<0,05

hoc corrections were used when comparing more than two independent groups. The collected data were statistically analyzed using the SPSS software package (Statistical Packages for Social Sciences, 29.0, Windows). For all tests, the significance level was set at $\alpha=0.05$.

RESULTS

The demographics and perioperative information

are given in Table. The mean age of patients was 49 in the pedicled flap group and 31 in the free flap group. All flaps survived in both groups. The mean pedicle division time was 29 days in PFG. The wound healed at the 38th day and the 20th day in PGFG and FFG, respectively, and the difference was significant ($p = 0.027$). The complication related to the flap was not seen in FFG, but wound dehiscence and infection were seen in four patients in PFG. The average



PFG: Pedicled Groin Flap Group, FFG: Free Groin Flap Group

Physical: $p<0,05$, Mental: $p>0,05$

Figure 4. SF-36 Summary scores in Pedicled and Free Groin Flap Groups.

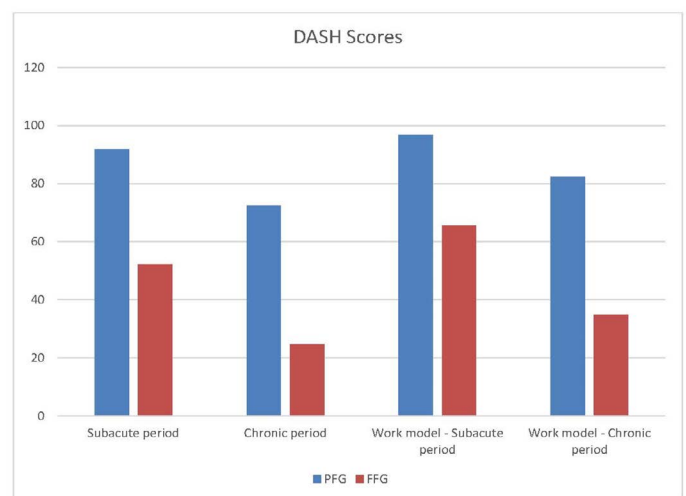


Figure 5. DASH scores in pedicled and free flap groups. DASH scores were decreased in PFG subacute and chronic period including work model with significant ($P<0,05$).

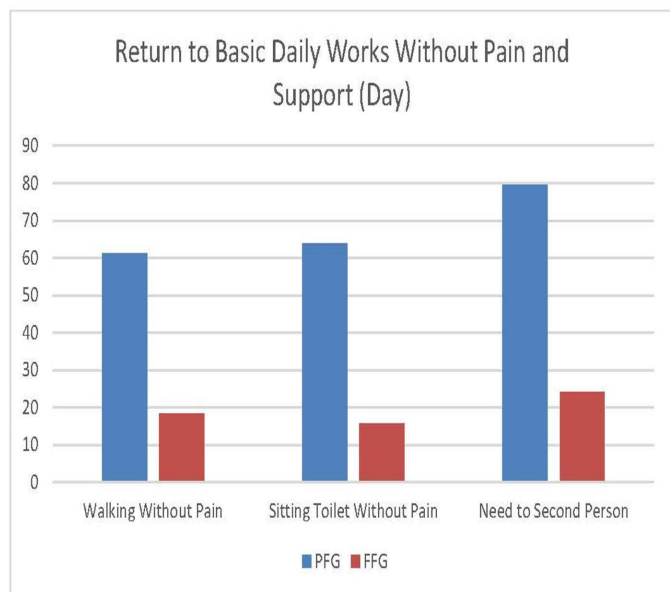
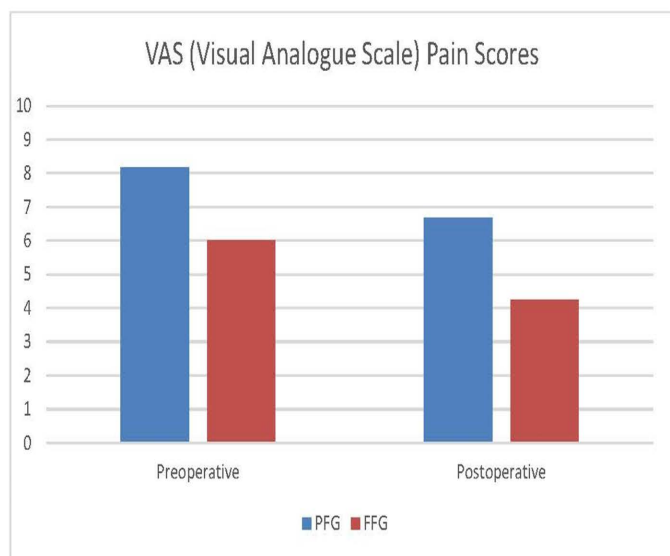


Figure 6. Visual Analogue Scale pain average scores increased in PFG compared to FFG with insignificant ($P>0,05$). But the return the daily works without pain and support was significantly decreased in FFG compared to PFG ($P<0,05$).

hospital stay in PFG was higher than in FFG (21 and 13.6 days, respectively), but the difference was not statistically significant ($p > 0.05$). The mean duration of operation was significantly shorter in PFG (113 min.) than in FFG (280 min.) ($p < 0.001$).

Half of the patients with pedicled flap had serious elbow and shoulder pain because of immobilization

of the upper extremity. ROM disabilities which are required physical therapy at the shoulder and elbow were also seen. This result was verified with DASH questionnaire. DASH score was found 92 and 72 in subacute and chronic stage in PFG, whereas 52 and 24 in FFG respectively ($p=0.012$ and $p=0.006$). In the work model of DASH, the score was found 96 and 65 in the subacute period in PFG and FFG respectively ($p=0.001$). In the chronic period, score was 80 in PFG and 34 in FFG and the difference was so significant ($p=0.004$) (Figure 4).

The patient's comfort in the early postoperative period related to surgical procedures was evaluated with the SF-36 quality of life test. The average of physical function score was 22 in PFG versus 44,6 in FFG, and the difference was significant ($p = 0.002$). The mental function score was lower in the PFG, but this was not significant ($p > 0.05$) (Figure 5). The mean VAS score was higher postoperatively in the PFG than in the FFG, but the difference was insignificant ($p > 0.05$).

The number of days a second person was needed for daily work was 79 in PFG and 24 in FFG ($p = 0.02$). Sitting in the toilet and walking without pain were started on the 63rd and 61st days in PFG and on the 15th and 18th days in FFG, respectively, with significance ($p = 0.01$ and $p = 0.02$) (Figure 6).

DISCUSSION

Distant flaps are preferred in the reconstruction of large tissue defects in the hand, where local flaps are not sufficient. Although the use of free flaps has increased recently, the widespread use of pedicled groin flaps continues for hand soft tissue defects (3, 4, 7). Although the free groin flap is described as the first flap in the literature, surgeons quit preferring this flap because of some technical difficulties such as a short pedicle, a small caliber of artery, and variations in the vasculature. But it is repopularized because of lower donor site morbidity, with the generous skin donor region allowing primary closure and the most effective hiding of the scar in the body (8). We also use the pedicled groin flap in our clinic for large hand defects. However, the problems that arise with the use of this flap with the pedicle have recently encouraged us to transfer this flap freely. We mostly prefer a groin flap when a free flap is required as a skin cover in the body. The fact that the least donor site problem is effective in this preference In fact, this flap was used to close the donor site of other free flaps (9, 10).

No study has been found in the literature comparing

the effect of pedicled or free transfer of the inguinal flap for hand defects on patient comfort and hand functionality. The most important limitation in the free transfer of this flap is the need for microsurgery and the long operation time because of the tough dissection of the pedicle (short, small, and variable vessel anatomy) (6,11). In our study, FFG operation time was found to be significantly longer than PFG. For this reason, we transferred the flap to the pedicle in patients who we thought could not tolerate the long operation time. This group consisted mostly of elderly patients with additional problems. Therefore, the mean age of both groups was so different (PFG:49 vs FFG:31). The pedicle of the flap was prepared to form a tube in PFG. In the FFG, the problem of pedicle shortness was tried to be overcome by keeping the skin island long. Raising the flap with this method, the handicaps of variational conditions can be eliminated, and operation time can be shortened in comparison with the literature. However, the operation time was found to be significantly higher when compared with the pedicled flap. In their study, Wood and Irons found that the duration of operation was 5.37 hours in various free flap transfers and 2.76 hours in the pedicled group (12). No circulatory disturbance was found in any of the flaps. In a meta-analysis of upper extremity reconstruction with a free flap, arterial and venous problems were found to be 5% and 8%, respectively (13).

Another problem with the groin flap is the bulkiness because of the adipose tissue, especially in overweight people (14). Therefore, in our study, the thinning procedures were required in both groups. As in the study by Ince et al. (15), procedures to reduce the fat tissue of the flap during the free style, may eliminate the need for seconder flap thinning.

Wound healing was significantly shorter in FFG compared to PFG. Thus, this contributed positively to both the short hospital stay and the initiation of the physical therapy program. When evaluated in terms of postoperative complications, wound dehiscence, and infections were all seen in PFG. These complications resulted in delayed wound healing and a prolonged hospital stay. In a meta-analysis examining the studies on upper extremity reconstruction with a free flap, infection was found to be 7%, hematoma 6%, seroma 6%, and wound dehiscence 7% (16).

The short duration of hospital stays is desirable both in terms of cost and patient psychology. The significant decrease in the length of hospital stays in FFG motivated us to choose this method more. In

the study comparing it with a pedicle groin flap using various free flaps, the length of hospital stay was found to be 13 days in the free flap group and 19 days in the pedicle flap group (12).

Restriction of the movement of the upper extremity in PFG is an important problem, especially in elderly individuals (3). In half of the patients, serious problems were encountered in the elbow and shoulder regions due to restrictions other than the injury area in the hand. Physical therapy programs had to be applied to the shoulder and elbow regions in order to eliminate the limitations. With the inclusion of hand injuries, a significant increase in DASH scores was encountered in subacute and chronic periods. In a study, the median DASH score was found to be 11.5 in patients who underwent reconstruction of hand defects with a pedicled groin flap (16). In the same study, 39% of the patients developed hand stiffness due to restriction, and the patients could be given physical therapy one week later than after the separation of the pedicle. There was only one study investigating the change in the quality of life-related to a free groin flap. In the study evaluating the cases where oral defects were reconstructed, the quality of life was mostly evaluated in terms of oral functions.

In addition, it was observed that the quality-of-life studies related to the reconstructions performed in the upper extremity and especially in the hand were very limited. In our study, hand and upper extremity problems were evaluated with the DASH score, and the effect on life comfort was evaluated with the SF-36. SF-36 summary scores were evaluated in two main categories: physical and mental. While the mean physical score was found to be significantly lower in PFG compared to FFG, the mean mental score was low in PFG but not statistically significant. This shows that the negative psychological effects of surgical trauma on patients are similar in both groups. From this, it can be concluded that physical status and mental status are not always correlated in patients. Although the postoperative early pain status was higher in the PFG group, there was no significant difference between the groups. In this respect, there is a similarity between mental scores and pain status. It can be said that pain may be effective in improving the psychological state of the patient. In the study where free flap reconstruction was performed in the upper extremity, it was concluded that pain was negatively correlated with DASH and SF-36 tests (17).

The questioning of the walking and sitting toilet, which are among the basic daily functions, was made

by comparing two different techniques recommended for the pilonidal sinus (18). We wanted to question the effect of the choice of flap method on the quality of life from a different perspective by adding the time that the patient was independent in her/his daily work and did not need the help of a second person to these questions. PFG showed a significant delay in painless walking and sitting on the toilet ($p < 0.05$). The need for the support of a second person in daily work was found to be significantly reduced in FFG. It is inevitable that the increase in difficulty in performing daily basic functions will result in a decrease in the quality of life.

Among the limiting factors of the study are the fact that it is retrospective, the homogeneity between the groups is low, and the number of patients is less.

In conclusion, by transferring the groin flap as a free flap, the problems related to shoulder and elbow joints have disappeared, and early hand rehabilitation could be started. DASH and SF-36 scores verified this. Return to daily work was also started earlier, and postoperative patient comfort was found to be better in free groin flap patients. These findings should be considered if the groin flap choices for reconstruction and the circumstances force the transfer of the groin flap as free in terms of patient comfort.

Conflict of interest: Authors declare that there is no conflict of interest between the authors of the article.

Financial conflict of interest: Authors declare that they did not receive any financial support in this study.

Address correspondence to: Selman Hakkı Altuntas, Süleyman Demirel University, School of Medicine, Department of Plastic, Reconstructive and Aesthetic Surgery, Isparta, Türkiye
e-mail: shaltuntas@gmail.com

REFERENCES

1. Griffin M, Hindocha S, Malahias M, et al. Flap decisions and options in soft tissue coverage of the upper limb. *Open Orthop J* 2014;8:409-14.
2. Michlovitz S. Physical therapy after hand injuries. *Hand Clin* 1999;15(2):261-73.
3. Goertz O, Kapalschinski N, Daigeler A, et al. The effectiveness of pedicled groin flaps in the treatment of hand defects: Results of 49 patients. *J Hand Surg Am* 2012;37(10):2088-94.
4. Sabapathy SR, Bajantri B. Indications, selection, and use of distant pedicled flap for upper limb reconstruction. *Hand Clin* 2014;30(2):185-99.
5. Koshima I, Nanba Y, Tsutsui T, et al. Superficial circumflex iliac artery perforator flap for reconstruction of limb defects. *Plast Reconstr Surg* 2004;113(1):233-40.
6. Hsu WM, Chao WN, Yang C, et al. Evolution of the free groin flap: The superficial circumflex iliac artery perforator flap. *Plast Reconstr Surg* 2007;119(5):1491-8.
7. Al-Qattan MM, Al-Qattan AM. Defining the indications of pedicled groin and abdominal flaps in hand reconstruction in the current microsurgery era. *J Hand Surg Am* 2016;41(9):917-27.
8. Altiparmak M, Cha HG, Hong JP, et al. Superficial circumflex iliac artery perforator flap as a workhorse flap: Systematic review and meta-analysis. *J Reconstr Microsurg* 2020;36(8):600-5.
9. Tong D, Liu Y, Wu LW, et al. Free groin flap for aesthetic and functional donor-site closure of the anterolateral thigh flap. *J Plast Reconstr Aesthet Surg* 2016;69(8):1116-20.
10. Rieger UM, Majenka P, Wirthmann A, et al. Comparative study of the free microvascular groin flap: Optimizing the donor site after free radial forearm flap phalloplasty. *Urology* 2016;95:192-6.
11. Aydin MA, Nasir S. Free SCIA/SIEA skin flap: A dual blood supply approach to groin region. *Microsurgery* 2007;27(7):617-22.
12. Wood MB, Irons GB. Upper-extremity free skin flap transfer: Results and utility as compared with conventional distant pedicle skin flaps. *Ann Plast Surg* 1983;11(6):523-6.
13. Zhang Y, Gazyakan E, Bigdeli AK, et al. Soft tissue free flap for reconstruction of upper extremities: A meta-analysis on outcome and safety. *Microsurgery* 2019;39(5):463-75.
14. Wagner RD, Carr L, Netscher DT. Current indications for abdominal-based flaps in hand and forearm reconstruction. *Injury* 2020;51(12):2916-21.
15. Ince B, Yazar S, Dadaci M. Simultaneous flap thinning with ultrasound-assisted liposuction during free flap surgery: Preliminary results. *Microsurgery* 2019;39(2):144-9.
16. Acharya AM, Ravikiran N, Jayakrishnan KN, et al. The role of pedicled abdominal flaps in hand and forearm composite tissue injuries: Results of technical refinements for safe harvest. *J Orthop* 2019;16(4):369-76.
17. van Bekkum S, de Jong T, Zuidam M, et al. Long-term quality of life after free flap upper extremity reconstruction for traumatic injuries. *J Reconstr Microsurg* 2020;36(3):213-22.
18. Ertan T, Koc M, Gocmen E, et al. Does technique alter the quality of life after pilonidal sinus surgery? *Am J Surg* 2005;190(3):388-92.

Comparison of Tranexamic Acid and Haemostatic Net in Reducing the Risk of Hematoma in Facelift Surgery

Yüz Germe Ameliyatında Hematom Riskini Azaltmada Traneksamik Asit ve Hemostatik Netin Karşılaştırılması

Mehmet Emin Cem Yıldırım¹, İlker Uyar²

Öz

Amaç: Yüz germe ameliyatı, yaşlanma belirtilerini azaltmak ve daha genç bir görünüme kavuşmak için sıklıkla tercih edilen bir estetik cerrahi işlemdir. Yüz germe ameliyatı olan hastalarda hematoma gibi komplikasyonların görülme sıklığı oldukça fazladır. Bu çalışma, yüz germe ameliyatı olan hastalarda traneksamik asit (TXA) ve hemostatik net (ağ) tekniğinin hematoma oluşumunu önlemedeki etkinliğini karşılaştırmayı amaçlamaktadır.

Hastalar ve Yöntem: Çalışmaya Ekim 2019-Şubat 2023 tarihleri arasında derin plan yüz germe ve yüz-boyun germe uygulanan 65 hasta (56 K, 9 E) dahil edildi. Hastalar TXA verilen, hemostatik net uygulananlar, ikisi birden uygulananlar ve hiçbirinin uygulanmadığı kontrol grubu olmak üzere dört farklı grupta değerlendirildi. Hastaların demografik bilgileri, takip bulguları, postoperatif dönemde hematoma ve diğer komplikasyonlar kaydedildi. Gruplar arasındaki farklılıklar istatistiksel olarak değerlendirildi.

Bulgular: Hastaların ortalama yaşı 54'tü. Sadece TXA uygulanan hasta grubu 17 hastadan, hemostatik net uygulanan grup 9 hastadan, her ikisi uygulanan grup 21 hastadan ve kontrol grubu 18 hastadan oluştu. Toplam 6 hastada hematoma görüldü. Sadece hemostatik net kullanılan hastalarda ve sadece TXA kullanılan hastalarda hematoma insidansında sayısal bir azalma gözlemlense de istatistiksel olarak anlamlı değildi ($p>0.05$). TXA ve hemostatik netin birlikte kullanıldığı hastalarda hematoma insidansı istatistiksel olarak anlamlı şekilde azalmıştır ($p<0.05$).

Sonuç: Traneksamik Asit ve hemostatik netin birlikte hematoma insidansını azaltmada etkili olduğu gösterildi. Hemostatik net kullanımı, hematoma insidansında istatistiksel olarak anlamlı bir azalma ile sonuçlanmıştır. Bu önlemlerin cerrahi sonuçları iyileştirebileceği ve hastaların iyileşme sürecini hızlandırabileceği düşünülmektedir.

Anahtar Kelimeler: Yüz germe, traneksamik asit, hemostatik net, hematoma

Abstract

Aim: Facelift surgery is a frequently preferred aesthetic surgery procedure to reduce the signs of aging and achieve a more youthful appearance. The incidence of complications such as hematoma is quite high among patients undergoing facelift surgery. This study aims to compare the efficacy of TXA and hemostatic net technique in terms of preventing hematoma formation in facelift surgery patients.

Patients and Methods: The study included 65 patients (56 F, 9 M) who underwent deep plan facelift and face and neck lift between October 2019 and February 2023. Patients were evaluated in four different groups: TXA given, those applied hemostatic net, those applied both, and the control group applied neither. Demographic information, follow-up findings, any hematoma or other complications in the postoperative period were recorded. Differences between the groups were evaluated statistically.

Results: The mean age of the patients was 54 years. The patient group using only TXA consisted of 17 patients, the group hemostatic net applied consisted of 9 patients, the group applied both consisted of 21 patients, and the control group consisted of 18 patients. Hematoma was observed in 6 patients in total. Although a numerical decrease in the incidence of hematoma was observed in patients in whom only hemostatic net was used and in patients in whom only TXA was used, it was not statistically significant ($p>0.05$). The incidence of hematoma decreased that is statistically significant in patients in whom TXA and hemostatic net were used together ($p<0.05$).

Conclusion: Tranexamic Acid and hemostatic net both together showed to be effective in reducing the incidence of hematoma. It is thought that these measures may improve surgical outcomes and accelerate the recovery process of patients.

Keywords: Facelift, tranexamic acid, hemostatic net, hematoma

¹Biruni University, Faculty of Medicine, Department of Plastic Reconstructive and Aesthetic Surgery, Istanbul, Turkey

²Izmir Katip Celebi University, Faculty of Medicine, Department of Plastic Reconstructive and Aesthetic Surgery, Izmir, Turkey

Address correspondence to: Mehmet Emin Cem Yıldırım, Biruni University, Faculty of Medicine, Department of Plastic Reconstructive and Aesthetic Surgery, Istanbul, Turkey
e-mail: dr.cem_yildirim@hotmail.com

Geliş Tarihi/Received: 24 July 2023

Kabul Tarihi/Accepted: 31 August 2023

Cite this article as: Yıldırım MEC, Uyar I. Comparison of Tranexamic acid and Haemostatic Net in Reducing the Risk of Hematoma in Facelift Surgery. Selcuk Med J 2023;39(3): 135-138

Disclosure: None of the authors has a financial interest in any of the products, devices, or drugs mentioned in this article. The research was not sponsored by an outside organization. All authors have agreed to allow full access to the primary data and to allow the journal to review the data if requested.



"This article is licensed under a [Creative Commons Attribution-NonCommercial 4.0 International License](https://creativecommons.org/licenses/by-nc/4.0/) (CC BY-NC 4.0)"

INTRODUCTION

Facelift surgery is a frequently preferred aesthetic surgery procedure to reduce the signs of aging and achieve a more youthful appearance. This type of surgery usually involves reshaping the skin and underlying tissues. However, the incidence of complications such as hematoma is quite high among patients undergoing facelift surgery (1). A hematoma can result in the accumulation of blood in the surgical site, potentially negatively affecting aesthetic results and prolonging the healing process.

Hematoma is one of the most common complications after facelift surgery (1-3). Therefore, some measures and techniques are applied to reduce the risk of hematoma after facelift surgery (4-6). Among these measures, tranexamic acid (TXA) and hemostatic net technique have been frequently used in recent years (7,8). TXA is a drug used as an antifibrinolytic agent and promotes blood clotting (7). There are a limited number of studies on the efficacy of TXA in facelift surgery patients. Some of these studies have shown that tranexamic acid reduces intraoperative blood loss and bruising (7). However, more information is needed on the potential side effects and optimal dosage of this drug.

The hemostatic net technique is a method used to achieve hemostasis at the surgical site (8). This technique is an intermittent continue suture technique that is placed on the skin to control small vessels in the surgical site and minimize bleeding. Hemostatic net has the potential to reduce the risk of hematoma by reducing the need for postoperative drainage. This study aims to compare the efficacy of TXA and hemostatic net technique in terms of preventing hematoma formation in facelift surgery patients.

PATIENTS AND METHODS

The study included 65 patients (56 F, 9 M) who underwent deep plan facelift and face and neck lift between October 2019 and February 2023. The study was designed retrospectively. Written and verbal consent was obtained from the patients. Ethics committee approval was obtained (0716 - 2023). Patients were evaluated in four different groups: TXA

given, those applied hemostatic net, those applied both, and the control group applied neither. Patients with bleeding disorders, history of aspirin use, and uncontrolled hypertension were excluded from the study. Patients were routinely followed up in the hospital for 2 nights postoperatively. Demographic information, follow-up findings, any hematoma or other complications in the postoperative period were recorded. Patients who developed hematoma were re-operated and the hematoma was intervened. Differences between the groups were evaluated statistically.

Each patient received one Jackson-Pratt drain on each side. At the end of the operation, each patient wears the same type of facial corset. The patient is not removed from the bed for 6 hours in a 45-degree reclining position. At the 4th hour, TXA 250 mg administered as IV inf. for 20 minutes. A total of 2 ampoules of 250 mg TXA are administered, one at the beginning of the surgical skin incision and the other at the 4th hour postop. Haemostatic net is applied with 2.0 PDS. It is removed on the 3rd day with drains.

Statistical Analysis

The data analysis was carried out using IBM SPSS Statistics version 20 (IBM Corp., Armonk, NY, USA). Statistical analysis involved performing Chi-Square test, and P values < 0.05 were considered to indicate significance.

RESULTS

The mean age of the patients was 54 years (min 42 - max 79). The patient group using only TXA consisted of 17 patients, the group hemostatic net applied consisted of 9 patients, the group applied both consisted of 21 patients, and the control group consisted of 18 patients. Hematoma was observed in 6 patients in total (Table 1.) Two patients with hematoma were in the only TXA group. Four patients belonged to the control group. The hematoma appeared at the 8th postoperative hour at the latest. No hematoma was observed in any of the patients in whom hemostatic net was applied. In addition, hematoma was not observed in patients in whom the hemostatic net was removed on the 3rd day. The

Table 1. Groups and number of patients with hematoma

Groups	Number of patients	Hematoma
Only TXA	17	2
Hemostatic Net	9	0
TXA and Hemostatic Net	21	0
Control Group	18	4

mean follow-up period was 6 months (min 4 - max 14 months). In 2 patients with hematoma, partial skin loss was observed in an area of 1 cm² and was left for secondary healing. Nerve defect, infection or other complications were not observed in any patient. TXA and hemostatic net is thought to reduce the incidence of hematoma. Although a numerical decrease in the incidence of hematoma was observed in patients in whom only hemostatic net was used and in patients in whom only TXA was used, it was not statistically significant ($p>0.05$). The incidence of hematoma decreased that is statistically significant in patients in whom TXA and hemostatic net were used together ($p<0.05$).

DISCUSSION

Hematoma is the most common complication in facelift surgery (9). The incidence requiring surgical intervention ranges from 1% to 15% (10). Male gender is a risk factor for hematoma (11). Hematomas can present as bleeding from small collections to a very serious amount and speed. While self-limiting hematomas of 5 - 10 ml can be drained with the help of injectors. Arterial bleeding, rapidly developing, widespread swelling, bleeding that causes ecchymosis should be re-operated with an emergency approach. Although hematomas usually appear in the first 24 hours, most major hematomas are 10-12 days old. observed per hour. Late manifestations of hematoma include swelling and discoloration of the lips and buccal mucosa (1,2,8).

If a hematoma is suspected, all dressings should be removed and the entire surgical site examined. When a progressive hematoma is observed, some of the sutures should be removed to provide drainage to reduce tension in the skin flaps. Afterwards, he should be taken to the operating room without wasting time. In cases where this treatment approach is not applied or the hematoma is not noticed, very serious complications may occur. Skin flap loss, wound dehiscence, infection, contour deformity and pigmentation changes can be observed.

Cold compress and pressure dressing are common general applications for hematoma prevention. The use of drains is common, but it has not been conclusively shown in the literature to reduce the risk of hematoma (12). It has been proven in the literature that postoperative hypertension is closely associated with hematoma formation (13). Post-operative pain, vomiting, retching, early and excessive mobility can cause sudden increases in blood pressure and

lead to hematoma (3,14,15). Systolic pressures above 150 mmHg are generally suggested as the cut-off value for hematoma (10,16). We think that hypotensive anesthesia as in nasal surgeries would not be appropriate. Since the patient wakes up after the surgery, which is completed by keeping the blood pressure low, the vessels that do not bleed during the operation may begin to bleed when the blood pressure is normal. This increases the risk of hematoma (17).

This study aims to compare TXA and hemostatic net technique to reduce the risk of hematoma after facelift surgery. Our results suggest that TXA may be effective in reducing the incidence of hematoma and hemostatic net application also plays an important protective role. TXA, as an antifibrinolytic agent, promotes blood coagulation and may reduce the risk of hemorrhage (7). In this study, we observed that the incidence of hematoma in patients receiving TXA was lower than in the control group. These results support that Tranexamic Acid is an effective option to prevent hematoma formation in facelift surgery patients. However, more research is needed on the potential side effects and optimal dosage of TXA.

On the other hand, we found that the hemostatic net technique was effective in reducing the incidence of hematoma. No hematoma formation was observed in patients who underwent hemostatic net, whereas the incidence of hematoma was significantly higher in the control group. It is thought that hemostatic net reduces the risk of bleeding by providing control of small vessels in the surgical area. In addition, the hemostatic net reduces the need for postoperative drainage, which may increase its effectiveness against hematoma. These findings suggest that the hemostatic net technique may be an important option to reduce the risk of hematoma after facelift surgery.

In the long-term follow-up of our patients, serious complications due to hematoma were rare. Partial skin loss was observed in only two patients and was treated with secondary healing. Nerve defect, infection or other serious complications were not observed in any patient. This shows that TXA and hemostatic net can be used safely and reliably.

The limited number of patients in the groups and the retrospective design of the study can be said to be the limitations of the study.

CONCLUSION

This study compared tranexamic acid and hemostatic net technique to reduce the risk of hematoma in facelift surgery patients. Tranexamic

acid and hemostatic net both together showed to be effective in reducing the incidence of hematoma. It is thought that these measures may improve surgical outcomes and accelerate the recovery process of patients. However, further research and comprehensive clinical trials will support these findings and determine the optimal methods of use.

Conflict of interest: Authors declare that there is no conflict of interest between the authors of the article.

Financial conflict of interest: Authors declare that they did not receive any financial support in this study.

Address correspondence to: Mehmet Emin Cem Yildirim, Biruni University, Faculty of Medicine, Department of Plastic Reconstructive and Aesthetic Surgery, Istanbul, Turkey
e-mail: dr.cem_yildirim@hotmail.com

REFERENCES

1. Kamer FM, Song AU. Hematoma formation in deep plane rhytidectomy. *Arch Facial Plast Surg* 2000;2:240-2.
2. Moyer JS, Baker SR. Complications of rhytidectomy. *Facial Plast Surg Clin North Am* 2005;13:469-78.
3. Bloom JD, Immerman SB, Rosenberg DB. Face-lift complications. *Facial Plast Surg* 2012;28(3):260-72.
4. Marchac D, Sándor G. Face lifts and sprayed fibrin glue: An outcome analysis of 200 patients. *Br J Plast Surg* 1994;47:306-9.
5. Zoumalan R, Rizk SS. Hematoma rates in drainless deep-plane face-lift surgery with and without the use of fibrin glue. *Arch Facial Plast Surg* 2008;10:103-7.
6. Jones BM, Grover R, Hamilton S. The efficacy of surgical drainage in cervicofacial rhytidectomy: A prospective, randomized, controlled trial. *Plast Reconstr Surg* 2007;120:263-70.
7. Al-Hashimi M, Kaur P, Charles W, et al. A Systematic review of the efficacy and safety of tranexamic acid in facelift surgery. *Aesthet Surg J* 2023:sjad213.
8. Auersvald A, Auersvald LA. Hemostatic net in rhytidoplasty: An efficient and safe method for preventing hematoma in 405 consecutive patients. *Aesthetic Plast Surg* 2014;38(1):1-9.
9. Cristel RT, Irvine LE. Common complications in rhytidectomy. *Facial Plast Surg Clin North Am* 2019;27(4):519-27.
10. Clevens RA. Avoiding patient dissatisfaction and complications in facelift surgery. *Facial Plast Surg Clin North Am* 2009;17(4):515-30.
11. Rohrich RJ, Stuzin JM, Ramanadham S, et al. The modern male rhytidectomy: Lessons learned. *Plast Reconstr Surg* 2017;139(2):295-307.
12. Jones BM, Grover R, Hamilton S. The efficacy of surgical drainage in cervicofacial rhytidectomy: A prospective, randomized, controlled trial. *Plast Reconstr Surg* 2007;120(1):263-70.
13. Berner RE, Morain WD, Noe JM. Postoperative hypertension as an etiological factor in hematoma after rhytidectomy. Prevention with chlorpromazine. *Plast Reconstr Surg* 1976;57:314-9.
14. Norred CL, Brinker F. Potential coagulation effects of preoperative complementary and alternative medicines. *Altern Ther Health Med* 2001;7:58-67.
15. Baker DC, Stefani WA, Chiu ES. Reducing the incidence of hematoma requiring surgical evacuation following male rhytidectomy: A 30-year review of 985 cases. *Plast Reconstr Surg* 2005;116:1973-85.
16. Chaffoo RA. Complications in facelift surgery: Avoidance and management. *Facial Plast Surg Clin North Am* 2013;21(4):551-8.
17. Moris V, Bensa P, Gerenton B, et al. The cervicofacial lift under pure local anaesthesia diminishes the incidence of post-operative haematoma. *J Plast Reconstr Aesthet Surg* 2019;72(5):821-9.

Efficacy of Ultrasound-Guided Caudal Epidural Steroid Injection for Axial or Radicular Low Back Pain

Lomber Aksiyel veya Radiküler Ağrılı Hastalarda Ultrason Kılavuzluğunda Kaudal Epidural Steroid Enjeksiyonunun Etkinliği

Ramazan Yılmaz¹, Hamit Goksu², Savas Karpuz¹, Levent Tekin¹, Halim Yılmaz¹

¹University of Health Sciences, Konya Beyhekim Education and Research Hospital, Department of Physical Medicine and Rehabilitation, Konya, Turkey
²Ankara Dr. Abdurrahman Yurtaslan Oncology Training, and Research Hospital, Department of Algology, Ankara, Turkey

Address correspondence to: Ramazan Yılmaz, University of Health Sciences, Konya Beyhekim Education and Research Hospital, Department of Physical Medicine and Rehabilitation, Konya, Turkey
e-mail: drramazanyilmaz@yahoo.com

Geliş Tarihi/Received: 3 June 2023
Kabul Tarihi/Accepted: 22 August 2023

Öz

Amaç: USG kılavuzluğunda kaudal steroid enjeksiyonları (KSE), radyasyon maruziyeti olmaksızın daha kolay uygulanabilme avantajına sahiptir. Bu çalışmanın amacı, USG kılavuzluğunda yapılan KSE'nin aksiyel veya radiküler bel ağrısı tedavisinde etkinliğini değerlendirmektir.

Hastalar ve Yöntem: Bu çalışma retrospektif kesitsel olarak tasarlanmıştır. Aralık 2022-Mayıs 2023 tarihleri arasında, diskojenik veya radiküler karakterde kronik bel ağrısı olan ve USG eşliğinde kaudal epidural steroid enjeksiyonu yapılan 21 hasta çalışmaya dahil edildi. İşlemden 2 ve 6 hafta sonra, hastaların vizüel analog skala (VAS-ağrı), hasta memnuniyet ölçeği, uyku kalitesi düzeyi ve Roland Morris Özürlülük Anketi (RMÖA) düzeyleri değerlendirildi.

Bulgular: Tedavi öncesi düzeylere göre, 2. ve 6. hafta kontrollerde VAS-ağrı skorlarında belirgin gerileme saptandı ($p < 0.001$). Anlamli ağrı azalması olarak kabul edilen, %50'den fazla ağrı rahatlama oranı 2. haftada %57,1, 6. haftada ise %38,1 idi. RMÖA skorlarında, benzer şekilde 2. ve 6. haftada anlamlı iyileşme gözlemlendi ($p < 0.001$) ancak; 2. hafta ile 6. hafta arasında anlamlı fark gözlemlenmedi ($p = 0.447$). Hastaların %71,4'ü başvuruda uyku kalitesini kötü olarak bildirirken, bu oran 2. ve 6. haftalarda sırasıyla %19,0 ve %23,8'e düşmüştü. Memnuniyet açısından hastaların %91,5'i 2. haftada daha iyi olduklarını belirtirken, bu oran 6. haftada %71,4'e düşmüştü.

Sonuç: USG kılavuzluğunda yapılan KSE, primer konservatif tedaviye dirençli diskojenik-radiküler bel ağrısı olan hastalarda ağrıyı, uyku kalitesini ve dizabiliteyi iyileştirmek ve aynı zamanda yüksek hasta memnuniyetini sağlamak için kısa-orta süreli takipte oldukça etkili ve güvenli bir tedavi seçeneğidir.

Anahtar Kelimeler: Bel ağrısı, kaudal epidural blok, ultrason kılavuzluğu, hasta memnuniyeti

Abstract

Aim: Ultrasound (USG)-guided caudal epidural steroid injections (CESI) have the advantage of being more easily applicable without radiation exposure. The aim of this study is to evaluate the effect of USG-guided CESI on axial or radicular low back pain.

Patients and Methods: This study was designed as a retrospective cross-sectional study conducted in an outpatient setting at a tertiary care hospital. Records of the 21 patients who underwent USG-guided CESI due to axial or radicular low back pain and had an assessment with a visual analog scale (VAS pain), degree of pain relief, patient satisfaction scale, sleep quality, and Roland Morris Disability Questionnaire (RMDQ) in the patient files or electronic database were included in the study between December 2022 and May 2023.

Results: There was a significant difference in VAS pain scores between admission and the 2nd week and between admission and the 6th week ($p < 0.001$). The frequency of meaningful pain reduction accepted as more than 50% pain relief was 57.1% and 38.1% at the 2nd and 6th weeks, respectively. A significant difference was found in RMDQ scores between admission and the 2nd week, between admission and the 6th week ($p < 0.001$), and between the 2nd week and the 6th week ($p = 0.447$). While 71.4% of the patients described poor sleep at presentation, this ratio was 19.0% and 23.8% at the 2nd and 6th weeks, respectively. While 91.5% of the patients declared that they were better in the 2nd week, 71.4% reported that they were better in the 6th week.

Conclusion: Ultrasonography-guided CESI is an effective treatment method for improving pain, sleep quality, and disability by ensuring high patient satisfaction in individuals with axial or radicular low back pain in a short-to-moderate-term follow-up.

Keywords: Low back pain, caudal epidural block, ultrasound-guided, patient satisfaction

Cite this article as: Yılmaz R, Goksu H, Karpuz S, Tekin L, Yılmaz H. Efficacy of Ultrasound-Guided Caudal Epidural Steroid Injection for Axial or Radicular Low Back Pain. Selcuk Med J 2023;39(3): 139-146

Disclosure: None of the authors has a financial interest in any of the products, devices, or drugs mentioned in this article. The research was not sponsored by an outside organization. All authors have agreed to allow full access to the primary data and to allow the journal to review the data if requested.



"This article is licensed under a [Creative Commons Attribution-NonCommercial 4.0 International License](https://creativecommons.org/licenses/by-nc/4.0/) (CC BY-NC 4.0)"

INTRODUCTION

Low back pain is one of the most commonly encountered health problems worldwide. It is one of the leading causes of deterioration in the quality of life and loss of labor (1). Low back pain can be acute (<1 month), subacute (1-3 months), or chronic (>3 months), depending on the duration of the symptoms. Chronic low back pain prevalence is estimated at 3.9–25.4 percent, and this rate increases in the older population (2). Lumbar disc herniations are one of the most common causes of low back pain and the most common cause of lumbosacral radiculopathy. Lumbar disc herniation is the pathology of the herniated nucleus pulposus, which often presents with a sudden onset of pain in the hips and legs following increased low back pain. According to Magnetic Resonance Imaging (MRI) findings, lumbar disc pathologies are classified as bulging, protrusion, extrusion, and sequestration. Non-operative treatments, including patient education, activity modification, medications, physical therapy modalities, exercises, spinal manipulation, traction (manual or mechanical), and epidural steroid injections are the first choice for most patients (3-5). Epidural steroid injections have been used to treat low back pain and sciatalgia for a long time. Its effectiveness has been demonstrated in many studies (6-8). Epidural injections may be applied with the interlaminar, caudal, or transforaminal approach (9).

Caudal epidural steroid injection (CESI) is the earliest described technique and involves the infusion of the medication into the epidural space from the sacrococcygeal ligament via the sacral hiatus. CESI is also accepted as the easiest and safest technique for epidural injections, although there is a risk of intravascular injection (10,11). Caudal epidural steroid injection may be applied with fluoroscopy, CT, or ultrasonography (USG)-guided. Studies about CESI in the literature include mainly fluoroscopy-guided injections. Ultrasonography-guided CESI has been applied more frequently in recent years. Considering the disadvantage of radiation exposure in fluoroscopy-guided caudal epidural steroid injection and the approximately 30% rate of needle misplacement in blind techniques relying on anatomical landmarks, as well as the significantly shorter procedural duration with ultrasound guidance compared to fluoroscopic procedures, the ultrasound-guided caudal block appears to be a safe, effective, and reasonable approach (12, 13).

This procedure, performed under ultrasound

guidance, enables more precise injections, thereby enhancing the success of the treatment. However, standardizing the treatment across a broad clinical spectrum proves challenging. Further research is needed to determine the specific clinical cases in which caudal block is warranted, as well as the optimal approach, timing, and technique. Particularly in recent years, patient satisfaction surveys have emerged as an important outcome measure in evaluating treatment results. To our knowledge, there is no study investigating the efficacy of USG-guided caudal epidural block, taking patient satisfaction into account.

The aim of this study is to investigate the short-term effectiveness, safety, and level of patient satisfaction of USG-guided CESI in patients with chronic low back pain unresponsive to conservative treatment associated with lumbar disc herniation.

PATIENTS AND METHODS

Study design and participants

The study protocol was approved by the Ethics Committee of Karatay University Non-Pharmaceutical and Medical Devices (2023/042). The study was designed as a retrospective and observational case-control study. Patients who underwent USG-guided CESI between December 2022 and May 2023, within the last six months, at a tertiary rehabilitation hospital and met the inclusion criteria were included in the study. Sociodemographic data, pain duration, pain distribution, comorbid diseases, history of lumbar surgery, treatment history, affected disc level, analgesic usage, and examination findings were obtained from patient files and electronic databases. In accordance with the literature, pain localized to the back was defined as 'axial pain' while pain radiating down the leg was defined as 'radicular pain' (7, 10). The presence of neuropathic characteristics in the pain was assessed using the Douleur Neuropathique 4 questions (DN4) (14).

The inclusion criteria were as follows:

- axial or radicular low back pain for at least three months unresponsive to conservative treatment
- age >18 years
- magnetic resonance imaging (MRI) findings were compatible with a lumbar disc lesion
- having routine post-injection clinical follow-ups at 2. and 6. week follow-ups
- patients who were evaluated with the Visual Analogue Scale (VAS) and had a VAS score of 5 or above.

- the patients were queried about sleep quality and patient treatment satisfaction survey, and Roland Morris Disability Questionnaire (RMDQ) during their follow-ups.

The exclusion criteria were as follows:

- patients who had received a lumbar injection previously; those with low back pain caused by secondary factors or red flags (fracture, malignancy, infection, rheumatic diseases, etc.).
- patients with an injection site infection, cauda equina syndrome, or progressive neurological deficit.
- patients who underwent interventional pain treatment or physical therapy programs after the CESI.

The Roland Morris Disability Questionnaire (RMDQ) is a validated tool in Turkish that assesses the impact of back pain on daily life (15). This questionnaire comprises 24 questions, with each question being answered as either yes (1 point) or no (0 point). The total score ranges from 0 to 24, where higher scores indicate a poorer functional status. To evaluate sleep quality, the 6th question of the Pittsburgh Sleep Quality Index (PSQI) was utilized, which is a 4-point Likert scale (16). This question, "How was your sleep quality last week?" was answered as 0 for very bad, 1 for fairly bad, 2 for fairly good, and 3 for very good. Patient satisfaction was assessed using a Likert-type questionnaire ranging from 1 to 7. On this scale, the options were defined as follows: 1 for "much better," 2 for "better," 3 for "slightly better," 4 for "no change," 5 for "slightly worse," 6 for "worse," and 7 for "much worse." Participants were instructed to select the option that best represented their own condition.

For US-guided CESI caudal block application in our clinic, the patient is lying prone, the lower lumbar-sacral region is sterilized with betadine, and the caudal canal is determined with the help of USG under sterile conditions. First, the optimal transverse view was obtained, which revealed the superficial sacrococcygeal ligament between the two sacral cornua and the deeper sacral bone. The target in this transverse view is the hypochoic region known as the caudal canal, located between the sacrococcygeal ligament and the sacral bone. Subsequently, the probe was rotated 90 degrees for a longitudinal view to facilitate the "in-plane" insertion of the needle into the sacral hiatus. To prevent dural puncture or hemorrhagia, the needle should not be advanced more than 10–15 mm beyond the apex, as its tip becomes invisible beyond this point. A mixture of steroid, local anesthetic, and serum physiologic (20 mg/1 ml triamcinolone, 4 ml 0.5% bupivacaine,

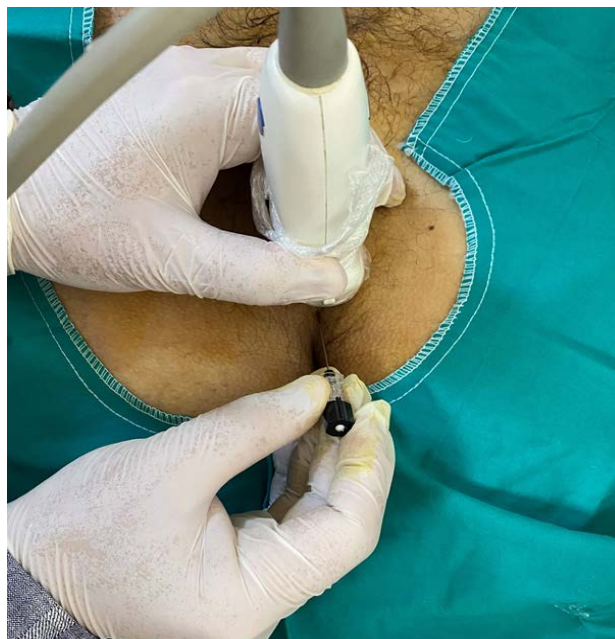


Figure 1. Image depicting the caudal block injection procedure

and 4 ml isotonic) is injected into the caudal canal with a 10 cc syringe, 20-gauge, 90-mm spinal needle under USG guidance (Fig. 1). After entering the canal through the sacrococcygeal ligament, the needle is advanced approximately 10–15 mm and blood control is performed. 9 ml of the mixture are slowly injected (Fig. 2). Then, the patients are monitored for 1 hour regarding vital signs, complications and discharged to their homes.

Statistical analysis

Data were analyzed with SPSS 25.0 (IBM Co., Inc., USA). The Shapiro-Wilk test was used to determine whether the variables had a parametric distribution.

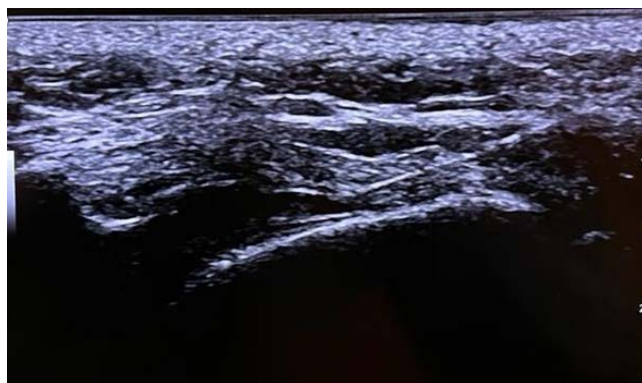


Figure 2. In-plane ultrasound-guided technique demonstrating the entry of the spinal needle into the caudal canal

Table 1. Demographic features of the patients

		N (%) or mean±SD
Age		51.24±14.08
Sex	Female	13(61,9)
	Male	8 (38,1)
BMI (kg/m ²)		27.15±4.35
Educational status	Illiterate	2 (9,5)
	Primary school	14 (66,7)
	Intermediate school	4 (19,0)
	High school	-
	University	1 (4,8)
Marital status	Married	14 (66,7)
	Single or widow	7 (33,3)
Occupation	Housewife	9 (42,9)
	Working	7 (33,3)
	Retired	5 (23,8)
Economic status	Income equal to the outcome	12 (57,1)
	Income higher than the outcome	5 (23,8)
	Income lower than the outcome	4 (19,0)
Smoking	No	18 (85,7)
	Yes	3 (14,3)

SD: Standard deviation, BMI: Body mass index

Table 2. Clinical characteristics of the patients

		n (%) or mean±SD
Pain distribution	Low back pain	3 (14,3)
	Low back and unilateral radicular pain	15 (71,4)
	Low back and bilateral radicular pain	3 (14,3)
Neuropathic pain	Yes	18 (85,7)
	No	3 (14,3)
VAS pain		7.29±1.45
RMDQ score		16.62±5.24
Sleep Quality	0-very bad	5 (23,8)
	1-fairly bad	10 (47,6)
	2-fairly good	6 (28,6)
	3-very good	-
Analgesic usage	NSAID	5 (23,8)
	Gabapentinoids	2 (9,5)
Neurogenic claudication	Yes	9 (42,9)
	No	12 (57,1)
Lumbar operation history	Yes	6 (28,6)
	No	15 (71,4)
Affected disc level	L3-4	1 (4,8)
	L4-5	2 (9,5)
	L5-S1	8 (38,1)
	L4-5 and L5-S1	10 (47,6)
MRI finding	Protrusion	12 (57,1)
	Extrusion	3 (14,3)
	Protrusion and extrusion	6 (28,6)
Comorbidity	Yes	10(47,6)
	No	11 (53,4)
Comorbid disease*	HT	5 (23,8)
	DM	4 (19,0)
	Asthma/COPD	4 (19,0)
	CAD	1 (4,8)
	BPH	3(14,3)

VAS: Visual analog scale, RMDQ: Roland-Morris Disability Questionnaire, NSAID: Nonsteroidal anti-inflammatory drugs, COPD: Chronic obstructive pulmonary disease, BPH: Benign prostate hyperplasia, MRI: Magnetic resonance imaging

Table 3. Visual analog scale, Roland-Morris Disability Questionnaire, sleep quality scores, and patient satisfaction status of the participants

	Baseline	2 nd week n(%) or mean±SD	6 th week	p
VAS pain	7.29±1.45	3.62±1.66	3.90±2.28	<0.001 ^a <0.001 ^b 0.447 ^c
VAS score reduction of >50%	-	12 (57,1)	8 (38,1)	
RMDQ	16.62±5.24	11.38±3.91	9.67±4.55	<0.001 ^a <0.001 ^b 0.027 ^c
Sleep Quality	0-very bad	5 (23,8)	1 (4,8)	
	1-bad	10 (47,6)	3 (14,3)	
	2-good	6 (28,6)	13 (61,9)	
	3-very good	-	4 (19,0)	
Patient Satisfaction	much better	-	3 (14,3)	
	better	-	8 (38,1)	
	a little better	-	8 (38,1)	
	no change	-	2 (9,5)	
	a little worse	-	-	
	much worse	-	-	

VAS: Visual analog scale, RMDQ: Roland-Morris Disability Questionnaire
^abaseline-2nd week, ^bbaseline-6th week, ^c2nd week-6th week comparisons

Categorical data were expressed as numbers and percentages (%). Numerical variables with parametric distribution are shown as the mean ± standard deviation (SD), and non-parametrically distributed numerical variables are shown as the median (min-max). The numerical variables with a non-parametric distribution and repeated measurements were compared using the Wilcoxon signed-rank test and the Friedman test. P<0.05 was accepted for statistical differences.

RESULTS

A total of 21 patients were included in the study. The mean age was 51.24 years (range, 31 to 82 years). The majority of the patients were female; 2/3 graduated from primary school, and again, 2/3 were married. The majority (85%) of them were non-smokers. The demographic characteristics of the patients are shown in Table 1. In four patients, the procedure was difficult, and repeated entries were made (resulting in success). Apart from this, no complications (hypotension, bleeding, paraparesis or monoparesis, urinary retention, etc.) were observed in any of the patients.

85.7% (18/21) of the patients had radicular and neuropathic pain. The VAS pain score was 7.29±1.45, and the RMDQ score was 16.62±5.24. According to the quality question of the PSQI, 71.4% described poor sleep quality. 1/3 of the patients reported having used analgesics. Approximately half of the patients had disc pathology in both the L4-5 and L5-S1

discs. The clinical characteristics of the patients are presented in Table 2.

There was a significant difference in VAS pain scores between admission and the 2nd week and between admission and the 6th week (p<0.001), but no statistical difference was found between the 2nd week and the 6th week (p = 0.447). The frequency of meaningful pain reduction accepted as more than 50% pain relief was 57.1% (12/21) and 38.1% (8/21) in the 2nd and 6th weeks, respectively. A significant difference was found in RMDQ scores between admission and the 2nd week, between admission and the 6th week (p<0.001), and between the 2nd week and the 6th week (p = 0.027). While 71.4% (15/21) of the patients described poor sleep according to sleep quality at presentation, this ratio was 19.0% (4/21) in the 2nd week and 23.8% (5/21) in the 6th week. While 91.5% (19/21) of the patients declared that they were better in terms of general health status in the 2nd week, 71.4% (15/21) reported that they were better at the 6th control. VAS pain, RMDQ, sleep quality scores, and satisfaction status of the patients at admission, 2nd and 6th weeks are demonstrated in Table 3.

DISCUSSION

The objective of this study was to assess the short-term effectiveness of CESI for lumbosacral disc herniation, and the results showed that CESI was effective for pain relief up to the 6th week in terms

of pain and disability, evaluated with VAS pain and RMDQ. Additionally, CESI treatment was found to significantly improve sleep quality throughout the follow-up period. A substantial proportion of patients reported better health status, demonstrating a high level of satisfaction with the treatment. CESI is a widely used effective method for lumbosacral radicular pain, although some studies suggest that transforaminal or interlaminar epidural injections have better outcomes (17,18). But it is the easiest and safest way to get epidural injections, and the advantage of avoiding radiation exposure makes it even more significant. Therefore, the application under USG guidance renders it a practical and valuable approach.

Caudal epidural steroid injection under USG guidance was as effective as fluoroscopy-guided CESI up to the 2nd month in a study conducted in patients with lumbosacral radicular pain (19). Similarly, in a study by Poutoglidou et al. (20), USG-guided CESI was as effective as nonimage and fluoroscopy-guided CESI regarding VAS and the Oswestry Disability Questionnaire (ODQ) in the first month. However, in a study involving patients with post-lumbar surgery syndrome who underwent single-level discectomy, both CESI and transforaminal epidural injections (TFESI) demonstrated comparable effectiveness, with only TFESI showing superior results in terms of disability at the 3rd week (21). Also, some studies investigated combining CESI and TFESI. Munjupong et al. (22) compared CESI plus TFESI versus only TFESI in 54 patients with chronic radicular pain, and they concluded that CESI plus TFESI was superior to TFESI at 3rd months regarding pain relief but not for functional evaluation. In this study, the greater effectiveness of CESI in pain relief may be attributed to its specific impact on the lower lumbosacral nerve roots. If CESI plus TFESI were compared solely to CESI, the effectiveness of CESI could be more easily rationalized.

Klunklin et al. (23) evaluated repeated USG-guided CESI three times at 0, 3, and 6th weeks in 110 patients with low back pain and sciatica. They found that >50 pain relief was 20%, 26%, 74%, and 83% at 2, 4, 6, and 24th weeks, respectively. In the 24th week, ODQ had reduced by more than 50% in most patients. In this series of 21 patients, meaningful pain relief was 57.1% in the 2nd week, higher than the study mentioned above, but 38.1% in the 6th week, lower than the study. Higher meaningful pain relief in the 6th week may be due to repeated injections, of course. Compared to this study published in 2022, it is

noteworthy that we observed greater effectiveness in the second week of our study. This could be attributed to the different half-lives of the local anesthetics used (lidocaine vs. bupivacaine). Additionally, using a lower volume of local anesthetic may help reduce the risk of motor blockage and alleviate symptoms such as nausea and dizziness. Senkal et al. (24) compared USG-guided and fluoroscopy-guided CESI in the 3rd week and 3rd month in 90 patients. USG-guided CESI was superior to fluoroscopy regarding successful injection rate on the first attempt and procedure time, and both techniques were similar in pain relief and improving disability evaluated with a numeric rating scale and ODQ at the 3rd week and 3rd month. This study shows that the similar effect of both fluoroscopy- and US-guided CESI continues up to the 3rd month with a single injection. In these two recent studies, the extent of needle advancement from the entry point into the sacral canal was not specified. However, considering the anatomy, it is expected to be approximately 4.5–6.0 cm above the dura mater (25). At these upper levels, the peridural space is also well vascularized. Therefore, after entering the sacral epidural space, when the tip of the needle is no longer visible under ultrasound, advancing the needle no more than 1–1.5 cm is important for safety reasons. We paid attention to this aspect, and no cases of blood aspiration, cerebrospinal fluid aspiration, or local infection were observed in our patients. Although the number of patients was limited, the practice of not advancing the needle too far supports a safe and effective approach. Indeed, current approaches indicate that injecting immediately after penetrating the sacrococcygeal ligament is sufficient and safer for CESI (26). At this point, ultrasound guidance CESI is superior to fluoroscopy due to its ability to visualize the sacrococcygeal ligament and allow for injection at the immediate entrance of the sacral canal after penetrating the sacrococcygeal ligament (without advancing 1 to 1.5 cm). It offers the advantage of being able to be performed in a shorter time, accessing the sacral canal in a single attempt, and easily identifying cases where the sacral canal is closed, which is seen in approximately 3% of cases.

The present study has several limitations that should be acknowledged. First, it is a retrospective study design, which inherently carries limitations associated with data collection. Additionally, being a single-center study with a relatively small sample size, the generalizability of the findings is limited. Another limitation is the lack of blinding for the assessors, which

introduces the possibility of evaluator bias. However, it is important to note that we took significant measures to minimize this bias and maintain the reliability of the study. Despite these limitations, our study holds notable strengths. To the best of our knowledge, it is the first study conducted in Turkey that takes patient satisfaction into account as an important outcome measure. Moreover, the study focused on patients who had undergone conservative treatments and underwent USG-guided CESI with highly selective indications. The findings strongly demonstrate the effectiveness and safety of this approach. These strengths highlight the valuable contributions of our study to the current literature.

CONCLUSION

Caudal epidural steroid injection is safe, effective in the short term, and comfortable for patients. Considering the aspects of being radiation-free and user-friendly in daily practice, the use of USG-guided CESI can provide high efficacy and patient satisfaction in appropriately selected cases. Large randomized controlled trials with large patient populations and long follow-ups may provide more information about its effectiveness.

Conflict of interest: Authors declare that there is no conflict of interest between the authors of the article.

Financial conflict of interest: Authors declare that they did not receive any financial support in this study.

Address correspondence to: Ramazan Yilmaz, University of Health Sciences, Konya Beyhekim Education and Research Hospital, Department of Physical Medicine and Rehabilitation, Konya, Turkey
e-mail: drramazanyilmaz@yahoo.com

REFERENCES

1. Wu A, March L, Zheng X, et al. Global low back pain prevalence and years lived with disability from 1990 to 2017: Estimates from the global burden of disease study 2017. *Ann Transl Med* 2020;8(6):299.
2. Meucci RD, Fassa AG, Faria NM. Prevalence of chronic low back pain: Systematic review. *Rev Saude Publica* 2015;49:1.
3. Lewis RA, Williams NH, Sutton AJ, et al. Comparative clinical effectiveness of management strategies for sciatica: Systematic review and network meta-analyses. *Spine J* 2015;15(6):1461-77.
4. Chou R, Deyo R, Friedly J, et al. Nonpharmacologic therapies for low back pain: A systematic review for an american college of physicians clinical practice guideline. *Ann Intern Med* 2017;166(7):493-505.
5. Rubinstein SM, van Middelkoop M, Kuijpers T, et al. A systematic review on the effectiveness of complementary and alternative medicine for chronic non-specific low-back pain. *Eur Spine J* 2010;19(8):1213-28.
6. Lewis RA, Williams NH, Sutton AJ, et al. Comparative clinical effectiveness of management strategies for sciatica: Systematic review and network meta-analyses. *The Spine Journal* 2015;15(6):1461-77.
7. Manchikanti L, Knezevic E, Knezevic NN, et al. Epidural injections for lumbar radiculopathy or sciatica: A comparative systematic review and meta-analysis of cochrane review. *Pain physician* 2021;24(5):E539-e54.
8. Leung SM, Chau WW, Law SW, et al. Clinical value of transforaminal epidural steroid injection in lumbar radiculopathy. *Hong Kong Med J* 2015;21(5):394-400.
9. William J, Roehmer C, Mansy L, et al. Epidural steroid injections. *Phys Med Rehabil Clin N Am* 2022;33(2):215-31.
10. Oliveira CB, Maher CG, Ferreira ML, et al. Epidural corticosteroid injections for lumbosacral radicular pain. *Cochrane Database Syst Rev* 2020;4(4):Cd013577.
11. Kim JY, Lee JS, Kim JY, et al. Comparison of the incidence of intravascular injection using the Tuohy and Quincke needles during ultrasound-guided caudal epidural block: A prospective randomized controlled study. *Reg Anesth Pain Med* 2023.
12. Ibrahim ME, Awadalla MA, Omar AS, et al. Ultrasound-guided caudal epidural steroid injection in chronic radicular low back pain: Short-term electrophysiologic benefits. *BJR Open* 2020;2(1):20190006.
13. Akkaya T, Ozkan D, Kertmen H, et al. Caudal epidural steroid injections in postlaminectomy patients: Comparison of ultrasonography and fluoroscopy. *Turk Neurosurg* 2017;27(3):420-5.
14. Sivas F, Uzun Ö, Başkan B, et al. The neuropathic pain component among patients with chronic low back-radicular pain. *J Back Musculoskelet Rehabil* 2018;31(5):939-46.
15. Küçükdeveci AA, Tennant A, Elhan AH, et al. Validation of the Turkish version of the roland-morris disability questionnaire for use in low back pain. *Spine (Phila Pa 1976)* 2001;26(24):2738-43.
16. Aoyagi K, He J, Clauw DJ, et al. Sleep quality in individuals with chronic low back pain and central sensitization. *Physiother Res Int* 2022;27(4):e1968.
17. Lee JH, Shin KH, Bahk SJ, et al. Comparison of clinical efficacy of transforaminal and caudal epidural steroid injection in lumbar and lumbosacral disc herniation: A systematic review and meta-analysis. *Spine J* 2018;18(12):2343-53.
18. Yun Z, Wang C, Yu T, et al. Comparative effects of different epidural injection approaches on lumbosacral radicular pain: A systematic review and network meta-analysis. *Pain Physician* 2022;25(8):531-42.
19. Hazra AK, Bhattacharya D, Mukherjee S, et al. Ultrasound versus fluoroscopy-guided caudal epidural steroid injection for the treatment of chronic low back pain with radiculopathy: A randomised, controlled clinical trial. *Indian J Anaesth* 2016;60(6):388-92.
20. Poutoglidou F, Metaxiotis D, Vasiliadis AV, et al. Caudal epidural injections in lumbar spinal stenosis: Comparison of nonimage, ultrasonography-, and fluoroscopy-guided techniques. A randomized clinical trial. *Perm J* 2021;25.
21. Celenlioglu AE, Sencan S, Bilim S, et al. Comparison of caudal versus transforaminal epidural steroid injection in post lumbar surgery syndrome after single-level discectomy: A prospective, randomized trial. *Pain Physician*

- 2022;25(2):161-9.
22. Munjupong S, Kumnerdee W. Effect of supraneural transforaminal epidural steroid injection combined with caudal epidural steroid injection with catheter in chronic radicular pain management: Double blinded randomized controlled trial. *F1000Res* 2020;9:634.
 23. Klunklin K, Sangsin A, Leerapun T. Efficacy and safety of ultrasound-guided caudal epidural steroid injection in patients with low back pain and sciatica. *J Back Musculoskeletal Rehabil* 2022;35(2):317-22.
 24. Senkal S, Sir E. Comparison of Ultrasonography and conventional fluoroscopy guided caudal epidural injection in chronic low back pain. *Turk Neurosurg* 2021;31(1):119-23.
 25. Porzionato A, Macchi V, Parenti A, et al. Surgical anatomy of the sacral hiatus for caudal access to the spinal canal. *Acta Neurochir Suppl* 2011;108:1-3.
 26. Doo AR, Kim JW, Lee JH, et al. A comparison of two techniques for ultrasound-guided caudal injection: The influence of the depth of the inserted needle on caudal block. *Korean J Pain* 2015;28(2):122-8.

A Case Report of Alveolar Lobular Breast Cancer Metastasized to the Whole Female Reproductive System

Kadın Üreme Sisteminin Tamamına Metastaz Yapan Alveolar Lobüler Meme Kanseri Vaka Sunumu

Sitki Ozbilgec¹, Emine Turen Demir¹, Pembe Oltulu², Mustafa Korkmaz³, Mehmet Artac³, Ali Acar¹

¹Necmettin Erbakan University, Meram Faculty of Medicine, Department of Gynecologic Oncology, Konya, Turkey
²Necmettin Erbakan University, Meram Faculty of Medicine, Department of Pathology, Konya, Turkey
³Erbakan University, Meram Faculty of Medicine, Department of Medical Oncology, Konya, Turkey

Address correspondence to: Sitki Ozbilgec, Necmettin Erbakan University, Meram Faculty of Medicine, Department of Gynecologic Oncology, Konya, Turkey
e-mail: sozbilgec@yahoo.com

Geliş Tarihi/Received: 8 December 2021
Kabul Tarihi/Accepted: 3 April 2022

Öz

Lobüler meme kanserinin üreme organlarına metastazı oldukça nadir görülen bir durumdur. Meme kanseri cerrahisi sonrası tamoksifen ve kemoterapi alan hastaların iç genital organ metastazlarının takibi klinik öneme sahiptir. Lobüler meme kanseri nedeniyle 9 yıl önce radikal mastektomi cerrahisi geçiren hasta, adjuvant kemoterapi tedavisi görmüş. Rutin takiplerinde vajinal kanama şikâyeti olan hastaya endometrial biyopsi sonucu endometriuma meme kanseri metastazı olarak raporlandı. Yapılan BT görüntülemeye iç genital organlarda yaygın metastaz izlenmesi üzerine hastaya cerrahi prosedür uygulandı. Bu vaka sunumunda hastanemize başvuran ve tedavi gören hastayı sunuyoruz.

Anahtar Kelimeler: Meme kanseri, endometrium, adneks, metastaz

Abstract

Metastasis of lobular breast cancer to reproductive organs is a very rare condition. Breast cancer Follow-up of internal genital organ metastases in patients receiving tamoxifen and chemotherapy after surgery is important. The patient underwent radical mastectomy 9 years ago for lobular breast cancer and received adjuvant chemotherapy. She complained of vaginal bleeding during routine follow-up and endometrial biopsy was reported as breast cancer metastasis to the endometrium. The patient underwent a surgical procedure after CT imaging showed extensive metastasis in the internal genital organs. In this case report, we present the patient who was admitted to our hospital and treated.

Keywords: Breast cancer, endometrium, adnexa, metastasis

Cite this article as: Ozbilgec S, Turen Demir E, Oltulu P, Korkmaz M, Artac M, Acar A. A Case Report of Alveolar Lobular Breast Cancer Metastasized to the Whole Female Reproductive System. Selcuk Med J 2023;39(3): 147-150

Disclosure: None of the authors has a financial interest in any of the products, devices, or drugs mentioned in this article. The research was not sponsored by an outside organization. All authors have agreed to allow full access to the primary data and to allow the journal to review the data if requested.



"This article is licensed under a [Creative Commons Attribution-NonCommercial 4.0 International License](https://creativecommons.org/licenses/by-nc/4.0/) (CC BY-NC 4.0)"

INTRODUCTION

Breast cancer is the most common cancer and the leading cause of cancer deaths in women worldwide. In the United States, breast cancer is the second leading cause of female cancer death after lung cancer (1). As we all know, breast cancer can metastasize to many organs. However, metastasis to the uterus is not common and usually occurs in the case of widespread metastatic disease (2). Lobular carcinoma is the most common form of breast cancer that metastasizes to the uterus (3). We introduced a case of breast lobular carcinoma, which was diagnosed with endometrial metastasis after abnormal uterine bleeding and infiltrated the entire internal reproductive system, peritoneum, and omentum of a patient being treated. The patient was diagnosed with breast lobular carcinoma 9 years ago. For lobular breast cancer, when abnormal uterine bleeding occurs, endometrial infiltration and uterine metastasis should be considered, and probe curettage should be used to examine the endometrium. We believe that our article will contribute to the literature in introducing lobular carcinoma metastasis involving all uterine segments, and have extensive histomorphological and immunohistochemical details.

CASE

Our patient is a 56-year-old G3 woman after menopause. She had undergone a radical mastectomy 9 years ago and was diagnosed with lobular breast cancer (figure 1).

Postoperative pathology, was reported as invasive lobular carcinoma, T2N0, ER 80% positive, PR 98% positive, CerbB2 negative. The adjuvant treatment received 4 cycles of Adriamycin (60 mg/m²) plus cyclophosphamide (600 mg/m²) every 21 days, radiotherapy and 7 years of endocrine therapy. In May 2019, the patient was found shortness of breath and pleural effusion during examination. The cytology report of pleural effusion is malignant. Patient who progressed began to receive weekly paclitaxel (80 mg/m²) plus carboplatin (AUC: 2) chemotherapy. In August 2019, partial remission after 12 weeks of chemotherapy, letrozole maintenance treatment was started. Capecitabine was started in patients with peritonitis carcinomatosis in November 2019, and progress was detected after 17 cycles. Ribociclib 1x600 mg plus fulvestrant was started, and 9 months later, vaginal bleeding occurred in patient in September 2021. It was determined that liver metastases detected in MRI examinations performed to evaluate intra-

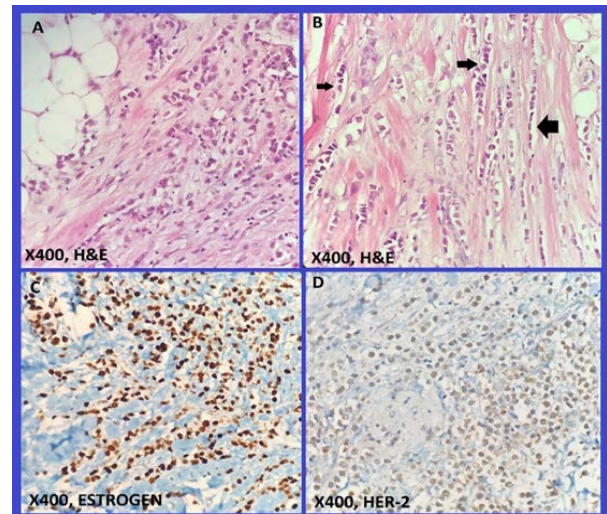


Figure 1. The histomorphological appearance of breast cancer at the time of first diagnosis A)X400,H&E; Infiltration of malignant lobular carcinoma cells with small hyperchromatic nuclei in breast stroma and fibrous stroma B)X400,H&E; 'Indian file' infiltration of malignant lobular carcinoma cells with small hyperchromatic nuclei in the breast stroma (arrow) C)X400,Estrogen; Strong nuclear estrogen expression in malignant lobular carcinoma cells in breast stroma D)X400,Her-2; Weak membranous Her-2 expression in malignant lobular carcinoma cells in breast stroma (score1, negative)

abdominal organs regressed after chemotherapy. During the radiological examination, the progress of bilateral adnexal masses and peritoneal implants was observed.

The thickness of the endometrium was measured at 8 mm during the pelvic ultrasound examination of the patient. In addition, bilateral pelvic masses and ascites were also observed. Several tumor biomarkers were examined, (CA)-15.3 was elevated [545 ng/ml (0-27)], while carcinoembryonic antigen and CA-125 levels were normal. The patient underwent an endometrial biopsy. The result is reported as metastatic breast cancer. Atypical epithelial islets are composed of small cells with a Ki-67 index of about 60%, which were independent cell groups that fall into fibrin and stain positive for pancytokeratin. GATA-3 and estrogen are positive, and CD10 is rarely positive. Pancytokeratin, CD45, S100, synaptophysin, p53, progesterone, p16, p63, chromogranin, mammaglobin, E-cadherin and Her-2 were all negative (score 0). (Figure 2).

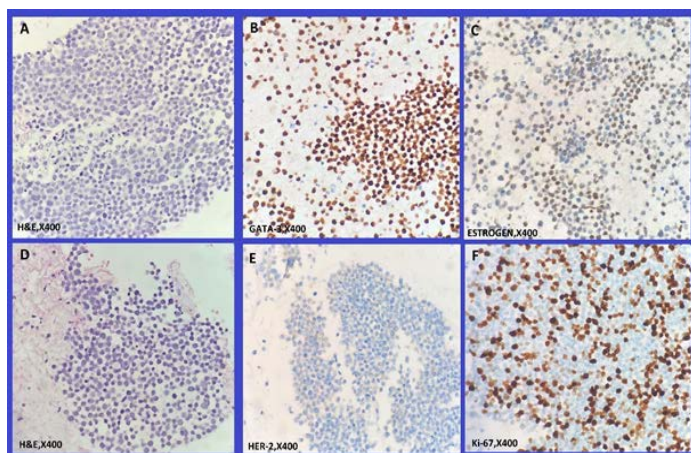


Figure 2. Analysis of lobular carcinoma cell groups in probe curettage material taken for abnormal uterine bleeding A)X400,H&E; Malignant cell groups with small hyperchromatic nuclei are seen B)X400,GATA-3; Malignant groups show positive nuclear reaction in GATA-3 immunohistochemistry staining supporting the breast primer C) X400,Estrogen; Malignant groups of breast show moderate nuclear positivity with Estrogen immunohistochemical staining consistent with Breast Lobular Carcinoma D)X400,H&E; Malignant cell groups with small hyperchromatic nuclei are seen in the middle of the pink colored fibrin material observed at the edges E)X400,Her-2; Her-2 expression is not seen in malignant groups (score 0, negative) F)X400,Ki-67; In malignant groups, approximately 60% of Ki-67 proliferation index nuclear positivity is present.

The patient was discussed in the oncology committee of our hospital. The patient underwent transabdominal hysterectomy and bilateral salpingo-oophorectomy, peritonectomy, and omentectomy. The pathological examination results of the specimens taken out during the operation were reported as metastasis of alveolar lobular breast cancer. The pathology report also included that the uterus, cervix and bilateral adnexa were completely infiltrated by cancer (Figure 3).

The peritonectomy and omentectomy materials are also infiltrated by cancer. The presence of tumor cells were also observed in abdominal washing fluid, and malignant cytology was reported to be compatible with lobular carcinoma.

DISCUSSION

Breast cancer rarely spreads to female reproductive

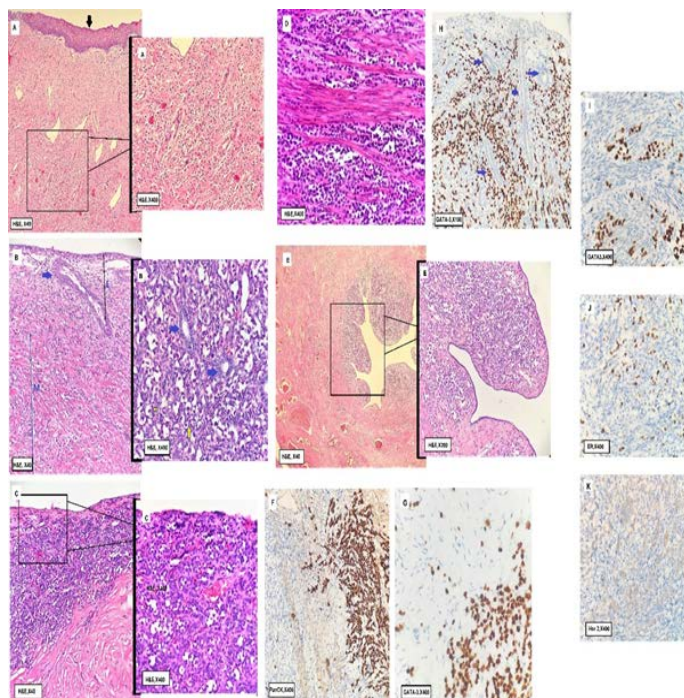


Figure 3. As a result of detailed analysis of all uterine segments in the surgical material, Cervix (A; stratified squamous epithelium that covers the cervix is indicated by arrow), Endometrium (B; Endometrial layer E, myometrium layer M is marked. Endometrial glands are indicated by blue arrow. Stroma outside the glands completely infiltrated with malignant lobular carcinoma (yellow arrows), Myometrium (B, D), Ovary (C; Tumor cells appear to infiltrate the ovarian capsule seen above (black arrow)) Tuba Uterina (E; Tuba uterina lumen visible, mucosa at high magnification) malignant infiltration is observed) malignant infiltration compatible with the morphology of cells belonging to malignant small hyperchromatic breast lobular carcinoma with nuclei is observed. Malignant infiltration observed in the ovary reacts positively with the general epithelial marker Pan cytokeratin (PanCK) (F), and also with GATA-3, which supports the breast primer (G). Tumor infiltrating the endometrium and myometrium also has a positive reaction with GATA-3, which supports the breast primary (H; Endometrial glands are indicated by blue arrow). GATA-3 (I), Estrogen (ER) positivity (J) Her2 negativity (K) are seen in malignant cells in myometrium.

organs. It usually affects the ovaries. Mazur et al. analyzed 325 female genital tract metastases in a study. They found that 75.8% of metastases involved the ovaries. The number of patients with endometrial

metastases was seven. In this study, 52 cases of breast cancer metastasized to the female reproductive tract. 46 of them had ovarian metastases, while two of them had endometrial metastases (4). Akhtar et al. conducted a review of the literature. In 2017, 25 cases of breast cancer that had spread to the uterus were observed (5). In these 25 cases, only one infiltrating ductal carcinoma case metastasized to the entire inner genital system and bone. We presented that the endometrium, myometrium, cervix, fallopian tubes, and ovaries were all involved in a case of invasive lobular cancer that spread throughout the female internal genital system. The tumor had also invaded the peritoneum of the pelvic side walls and the omentum.

Breast cancers with invasive lobular carcinoma account for 9.7% of all cases. Invasive lobular carcinoma is more likely than infiltrating ductal breast carcinoma to spread to the gynecologic organs. According to Borst et al, around 4.5 percent of invasive lobular breast carcinomas spread to gynecological organs, while 0.8% of infiltrating ductal breast carcinomas moved to gynecological organs (6). The probability of metastasis to the endometrium of infiltrating ductal carcinoma was found to be lower than that of invasive lobular carcinoma in a study conducted between 1984 and 2015, in which 13 cases of endometrial metastases from breast cancer were evaluated (7).

Abnormal uterine bleeding is the most prevalent indicator that breast cancer has spread to the uterus (8). Chemotherapy caused postmenopausal uterine hemorrhage in our instance. The endometrium, myometrium, fallopian tubes, and ovaries were all involved in this patient's hysterectomy and bilateral salpingo-oophorectomy. Cancer had invaded the peritoneum, which covered both the pelvic side walls and the omentum. In November 2021, the patient was given paclitaxel (80 mg/m²) and carboplatin (AUC:2) as a postoperative treatment.

In our case, during chemotherapy, a 56-year-old female patient with metastatic breast cancer experienced postmenopausal bleeding and pelvic pain. The patient was diagnosed and treated appropriately as a consequence of the patient's consultation with the gynecological oncology clinic and the prompt evaluation of the endometrium.

CONCLUSION

It should be kept in mind that breast cancer may metastasize to the endometrium in patients

receiving chemo-hormonotherapy for breast cancer. Regular pelvic examination should be performed and transvaginal ultrasound scans should be performed. The endometrium should be evaluated. In case of suspected vaginal bleeding, endometrial sampling should be performed.

Conflict of interest: Authors declare that there is no conflict of interest between the authors of the article.

Financial conflict of interest: Authors declare that they did not receive any financial support in this study.

Address correspondence to: Sitki Ozbilgec, Necmettin Erbakan University, Meram Faculty of Medicine, Department of Gynecologic Oncology, Konya, Turkey
e-mail: sozbilgec@yahoo.com

REFERENCES

1. Siegel RL, Miller KD, Fuchs HE, et al. Cancer statistics, 2021. *CA Cancer J Clin.* 2021;71(1):7-33.
2. Briki R, Cherif O, Bannour B, et al. Uncommon metastases of invasive lobular breast cancer to the endometrium: A report of two cases and review of the literature. *Pan Afr Med J* 2018; 30:268.
3. Ustaalioglu BB, Bilici A, Seker M, et al. Metastasis of lobular breast carcinoma to the uterus in a patient under anastrozole therapy. *Onkologie* 2009;32(7):424-6.
4. Mazur MT, Hsueh S, Gersell DJ. Metastases to the female genital tract. Analysis of 325 cases. *Cancer* 1984;53(9):1978-84.
5. Akhtar A, Ratra A, Puckett Y, et al. Synchronous uterine metastases from breast cancer: Case study and literature review. *Cureus* 2017;9(11):e1840.
6. Borst MJ, Ingold JA. Metastatic patterns of invasive lobular versus invasive ductal carcinoma of the breast. *Surgery* 1993;114(4):637-41.
7. Huo Z, Gao Y, Zuo W, et al. Metastases of basal-like breast invasive ductal carcinoma to the endometrium: A case report and review of the literature. *Thorac Cancer* 2015;6(4):548-52.
8. Akhtar A, Ratra A, Puckett Y, et al. Synchronous uterine metastases from breast cancer: Case study and literature review. *Cureus* 2017;9(11): e1840.